

PATIENT

Flooffu Sood

SPECIES

Canine

BREED

Mini Golden Doodle

SEX

Male

AGE

6 Months

WEIGHT

15.2 Pounds

INTERPRETED BY

Eric Lindquist, DMV

DABVP, Cert. IVUSS

IMAGING PERFORMED BY

Dr. Mayra Sanchez

HOSPITAL NAME

Sunset Animal Hospital

REFERRING VET

Dr. Mayra Sanchez

INVOICE

38093

DATE

5/27/22

PRESENTING CLINICAL SIGNS

Multiple episodes of V/D over the past 3 months First episode occurred after patient chewed up a flip flop Patient responds well to symptomatic treatment

Abnormal PE/Chem/CBC/UA Results: PE: NAF CBC/Chem: NAF Fecal scan: NPS Radiographs: No obvious FB or obstruction seen

ULTRASONOGRAPHIC EXAMINATION OF THE ABDOMEN

Urinary System

The **urinary bladder**, trigone, and pelvic urethra presented normal thicknesses and normal tone. The ureters were not visible which is normal. No uroliths or sediment were visualized and anechoic urine was present. No evidence of inflammatory or neoplastic changes were noted. Ureteral papillae were normal.

The **kidneys** revealed normal size and structure, corticomedullary definition and ratio for this age. The cortices presented largely uniform texture with normal echogenic relationship to liver and spleen. Medullary structure differed distinctly from the cortex and no evidence of pelvic dilation was present. The capsules were acceptably uniform without significant irregularities. The left kidney measured 4.76 cm. The right kidney measured 4.5 cm.

Adrenal Glands

The region of the **left adrenal gland** was imaged, no evident pathology.

The **right adrenal gland** was flattened and isoechoic.

Spleen

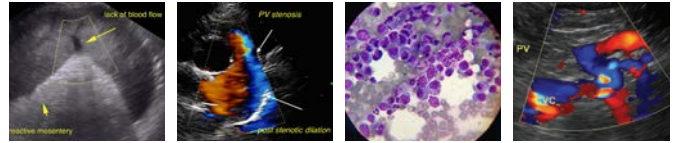
The **spleen** presented a smooth homogeneous parenchyma hyperechoic to liver and renal cortical parenchyma. The capsule was smooth without noticeable expansion or deviation from within the spleen or adjacent pathology. The splenic vasculature demonstrated normal volume without signs of congestion or thrombosis. No sonographic evidence of acute or chronic inflammatory, neoplastic, or infarctual changes were noted.

Liver

The **liver** images submitted revealed subjectively normal liver size, contour, and structure. Parenchymal echogenicity was naturally coarse and hypoechoic to the spleen. Vascular and biliary tracts were of normal volume with no evidence of congestion. The gallbladder presented acceptably thin walls with primarily anechoic content. The cystic and common bile ducts were normal. No pathological hepatic lymphadenopathy was evident. No overt structural evidence of inflammatory, infiltrative or regenerative pathology was evident.

Gastrointestinal

Examination of the **gastrointestinal tract** revealed a stomach and intestine free of stasis, of normal wall thickness, acceptable curvilinear mural detail, and peristaltic activity. Small and large intestine demonstrated normal luminal chyme and stool consistency respectively. No obstructive or overt infiltrative disease was noted. No associated abnormal lymphatic activity was noted.



PATIENT

Pancreas

Flooffu Sood

The base and limbs of the **pancreas** were observed to be largely isoechoic to surrounding omental fat. Pancreatic duct and capsular contour were acceptably normal and parenchyma respected normal curvilinear patterns. No overt evidence of active inflammatory or neoplastic disease was noted.

SPECIES

Canine

ULTRASONOGRAPHIC FINDINGS

- Flattened adrenal glands
- Unremarkable abdomen otherwise

BREED

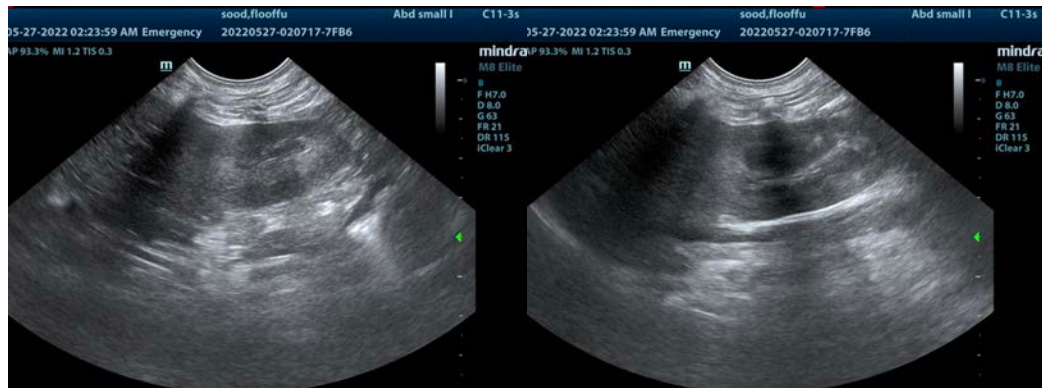
Mini Golden Doodle

INTERPRETATION OF THE FINDINGS & FURTHER RECOMMENDATIONS

Screening for congenital Addison's warranted in this patient. ACTH stimulation recommended. Otherwise, no evidence of pathology.

SEX

Male



AGE

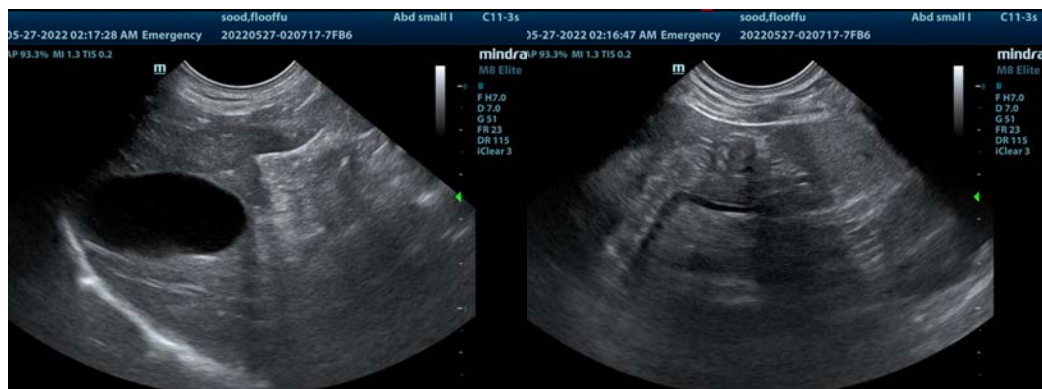
6 Months

WEIGHT

15.2 Pounds

INTERPRETED BY

Eric Lindquist, DMV
DABVP, Cert. IVUSS



IMAGING PERFORMED BY

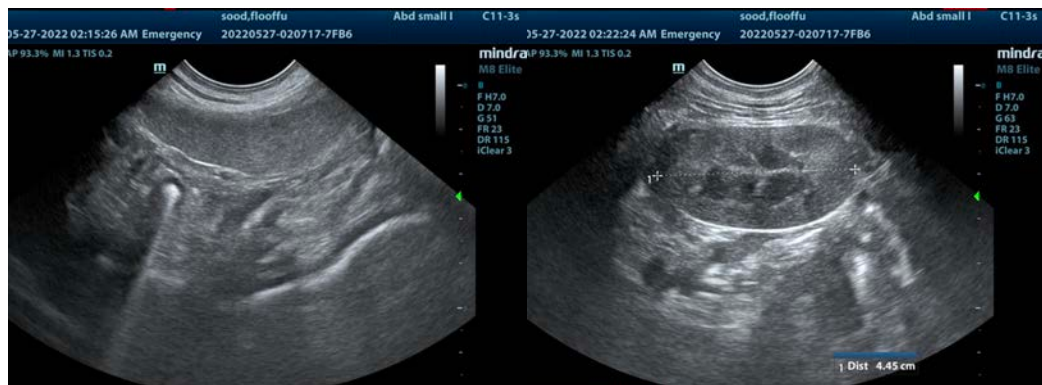
Dr. Mayra Sanchez

HOSPITAL NAME

Sunset Animal Hospital

REFERRING VET

Dr. Mayra Sanchez

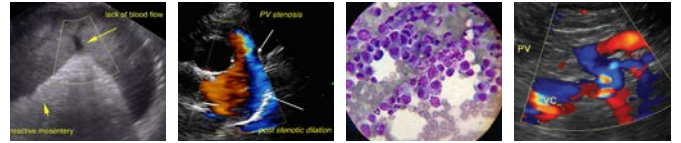


INVOICE

38093

DATE

5/27/22



PATIENT

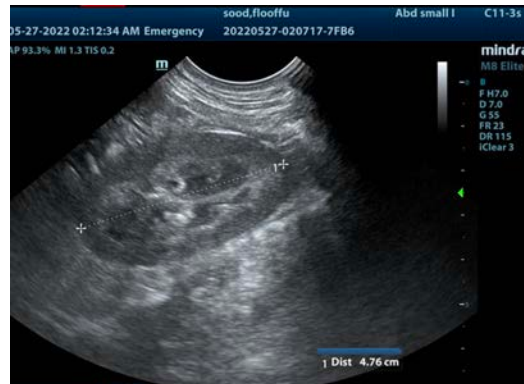Flooffu Sood

SPECIES

Canine

BREED

Mini Golden Doodle



SEX

Male

AGE

6 Months

WEIGHT

15.2 Pounds

INTERPRETED BY

Eric Lindquist, DMV

DABVP, Cert. IVUSS

IMAGING PERFORMED BY

Dr. Mayra Sanchez

HOSPITAL NAME

Sunset Animal Hospital

REFERRING VET

Dr. Mayra Sanchez

INVOICE

38093

DATE

5/27/22

The information and recommendations provided are based on the images presented by the referring veterinarian/sonographer. No evaluation can be communicated regarding pathology that was not visible in the image/video clips provided.

Thank you for this referral. If the clinical or image interpretation does not parallel your findings or if I can be of any further assistance please contact me.

Eric Lindquist, DMV, DABVP, Cert. IVUSS, CEO of SonoPath.com

info@SonoPath.com