



**PATIENT**

Lucky Pickens

**SPECIES**

Canine

**BREED**

Doodle

**SEX**

Spayed Female

**AGE**

12 Years 3 Months

**WEIGHT**

33

**INTERPRETED BY**

Eric Lindquist, DMV,  
DABVP(CFM), Cert.  
IVUSS

**IMAGING PERFORMED BY**

Dr. Michele  
Pffannenstiel

**HOSPITAL NAME**

Mill Brook Animal  
Clinic- VBF

**REFERRING VET**

Dr. Michele  
Pffannenstiel

**INVOICE**

16524

**DATE**

05/26/26

**PRESENTING CLINICAL SIGNS**

Has had UTIs since Dec 2025. Has had a round of amoxi clav which sounds like it did not help much. She pees 10-12 times a day when she has a spell of a UTI. I pulled another UA with culture today and changed to a 10 mg/kg Enro dose for a week. She also has a 2/6 heart murmur and mom wanted to get her echo done today.

Abnormal PE/Chem/CBC/UA Results: Low USG with pH 9+ and a Proteus inf that is susceptible to many drugs

**ULTRASONOGRAPHIC EXAMINATION OF THE HEART & ABDOMEN**

CANINE CARDIAC PARAMETERS	MR VMAX (m/s)	TR VMAX (m/s)	LA/AO (M-Mode)	LA/AO (Heart Base; Swe)	FS (%)	EF (%)	EPSS (cm)
NORMAL PARAMETER	4.5-5.5	<2.7	1.3	Up to 1.6	28-40	40-100	<0.6
PATIENT	--	--	1.3	--	35	90	0.1
CANINE CARDIAC PARAMETERS	HR (BPM)	AV VMAX (m/s)	PV MAX (m/s)	BODY WEIGHT	LAD LA MAX 4 Chamber	LVIDd Avg; 2D and m-mode short axis (cm)	LVIDs Avg; 2D and m-mode short axis (cm)
NORMAL PARAMETER	50-100	0.7-1.7	0.7-1.6				
PATIENT	110	--	--	33	~3.5	2.9	--

**Cardiac Presentation**

The echocardiogram in this patient demonstrated normal **left atrial** size based on 3 separate methods of LA evaluation. The cranial and caudal **mitral** valve leaflets presented normal linear structure, extension in systole, and union in diastole with normal kinesis. The **left ventricle** presented normal thicknesses with linear contour and was not dilated nor restricted. The **myocardium** presented normal echogenicity without subjective evidence of significant fibrotic or ischemic disease. **Contractility** of the ventricular walls was adequate and in normal range for this patient evidenced by the fractional shortening measurement and subjective evaluation of the different regions of the myocardium. The **left ventricular outflow** tract demonstrated normal laminar flow and subjective structural integrity. The **right atrium** and auricle revealed normal size, structure and content. No evidence of masses was noted. **Tricuspid** valvular assessment demonstrated adequate linear morphology and kinesis. The **right ventricle** was of normal size (1/3 diameter of LV), chordae structure, myocardial echogenicity and thickness. **Pulmonary outflow** tract assessment revealed normal valve structure, laminar flow, and diameter (approx.1:1 pa/ao ratio). No visible **pericardial** or free pleura fluid was noted. The cranial **mediastinum and pericardial and extra-cardiac regions** were free of masses in the visible window.

**Urinary System**



## PATIENT

Lucky Pickens

## SPECIES

Canine

## BREED

Doodle

## SEX

Spayed Female

## AGE

12 Years 3 Months

## WEIGHT

33

## INTERPRETED BY

Eric Lindquist, DMV,  
DABVP(CFM), Cert.  
IVUSS

## IMAGING PERFORMED BY

Dr. Michele  
Pffannenstiel

## HOSPITAL NAME

Mill Brook Animal  
Clinic- VBF

## REFERRING VET

Dr. Michele  
Pffannenstiel

## INVOICE

16524

## DATE

05/26/26

The **urinary bladder** presented a moderate thickening of the cranioventral and craniodorsal mucosae with micropolypoid mucosal changes without involvement of the submucosae. The urine presented some echogenicity consistent with suspended debris. No evidence of urethral pathology was present. This presentation is most consistent with chronic cystitis. Technically transitional cell carcinoma cannot be ruled out without histopathological review but is not overtly suspected based on this pattern. Cystocentesis and urine culture +/- pathological review of urine cytology would be warranted. A minor amount of sand accumulation was noted. The bladder wall at moderate repletion measured 0.7 cm. The urethra was visible to a depth of 2.0 cm.

The **kidneys** revealed largely normal size and structure, corticomedullary definition and ratio (cortex 1/3 of medulla) were essentially maintained with some mild age-related loss of curvilinear patterns regarding the capsule and C/M junction. The cortices presented largely uniform texture with some increased echogenicity expected for his age patient. Medullary structure differed distinctly from that of the cortex and no evidence of pelvic dilation was present. The left kidney measured 5.5 cm in length. The right kidney measured 5.6 cm in length.

### **Adrenal Glands**

Both **adrenal glands** were not visualized.

### **Spleen**

The **spleen** presented a smooth homogeneous parenchyma hyperechoic to liver and renal cortical parenchyma. The capsule was smooth without noticeable expansion or deviation from within the spleen or adjacent pathology. The splenic vasculature demonstrated normal volume without signs of congestion or thrombosis. No sonographic evidence of acute or chronic inflammatory, neoplastic, or infarctual changes were noted.

### **Liver**

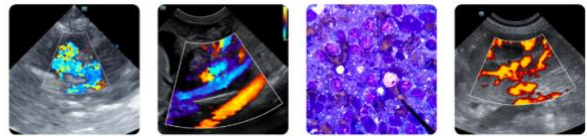
The **liver** images from right and left intercostal as well as subcostal views revealed subjectively normal liver size, contour, and structure. Some mild age-related parenchymal remodeling was noted but likely not clinically significant at this time. Vascular and biliary tracts were of normal volume and no evidence of congestion was noted. The gallbladder presented some dependent debris with essentially normal contour. The cystic and common bile ducts were normal. No overt evidence of active inflammatory, infiltrative or regenerative pathology was noted but should be paired with current or past LE elevations regarding any clinical significance to this presentation. The hepatic lymph nodes were unremarkable.

### **Gastrointestinal**

There was some residual chyme and gas was noted in the **stomach**, yet not pathological. This is consistent with end post prandial presentation. Transit of chyme into the small intestine was normal. Curvilinear patterns were maintained throughout the GI tract. No evidence of pathology. Small and large intestine demonstrated normal luminal chyme and stool consistency respectively. No obstructive or overt infiltrative disease was noted. No associated abnormal lymphatic activity was noted.

### **Pancreas**

The base and limbs of the **pancreas** were observed to be largely isoechoic to surrounding omental fat. Pancreatic duct and capsular contour were acceptably normal and parenchyma respected normal curvilinear patterns. No overt evidence of active inflammatory or neoplastic disease was noted.



## PATIENT

Lucky Pickens

## SPECIES

Canine

## BREED

Doodle

## SEX

Spayed Female

## AGE

12 Years 3 Months

## WEIGHT

33

## INTERPRETED BY

Eric Lindquist, DMV,  
DABVP(CFM), Cert.  
IVUSS

## IMAGING PERFORMED BY

Dr. Michele  
Pfannenstiel

## HOSPITAL NAME

Mill Brook Animal  
Clinic- VBF

## REFERRING VET

Dr. Michele  
Pfannenstiel

## INVOICE

16524

## DATE

05/26/26

## ULTRASONOGRAPHIC FINDINGS

- Chronic cystitis bladder pattern with minor amount of sand.
- Age-related abdominal changes.
- Normal echocardiogram.

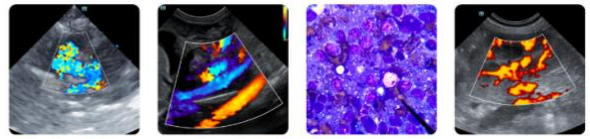
## INTERPRETATION OF THE FINDINGS & FURTHER RECOMMENDATIONS

The bladder sand should resolve with long-term antibiotic treatment for UTI with dissolution protocol based on urinalysis results. 4-6 weeks of antibiotic therapy is likely necessary. Recheck sonogram prior to stopping antibiotics.

### Canine Chronic UTI Protocol

**To be utilized for UTI with chronic urinary tract changes found sonographically that may serve as nidus of infection and history of chronic or recurrent UTI is an issue.**

I recommend Clavamox as a first level approach to chronic UTI at 12.5-25 mg/kg bid owing to optimal urinary concentrations. If bacterial resistance is an issue then **Enrofloxacin** (5-10 mg/kg SID PO) (In patients > 1 year of age) in late pm after urination to maximize urinary concentrations overnight. This assumes that culture supports this use. Repeat **culture** at 3-4 weeks and continue treatment at least 7-10 days post negative urinary sediment and negative culture. *Note: Negative culture does not necessarily mean lack of UTI.* Other favorite antibiotics for chronic UTI include third generation Cefa (Ceftiafur or similar s.i.d. injectable) or Clavamox. If suspicion of occult urinary incontinence is present, then **phenylpropanolamine (PPA)** (1-2 mg/kg BID) can be employed long term to enhance urethral tone.



## PATIENT

Lucky Pickens

## SPECIES

Canine

## BREED

Doodle

## SEX

Spayed Female

## AGE

12 Years 3 Months

## WEIGHT

33

## INTERPRETED BY

Eric Lindquist, DMV,  
DABVP(CFM), Cert.  
IVUSS

## IMAGING PERFORMED BY

Dr. Michele  
Pffannenstiel

## HOSPITAL NAME

Mill Brook Animal  
Clinic- VBF

## REFERRING VET

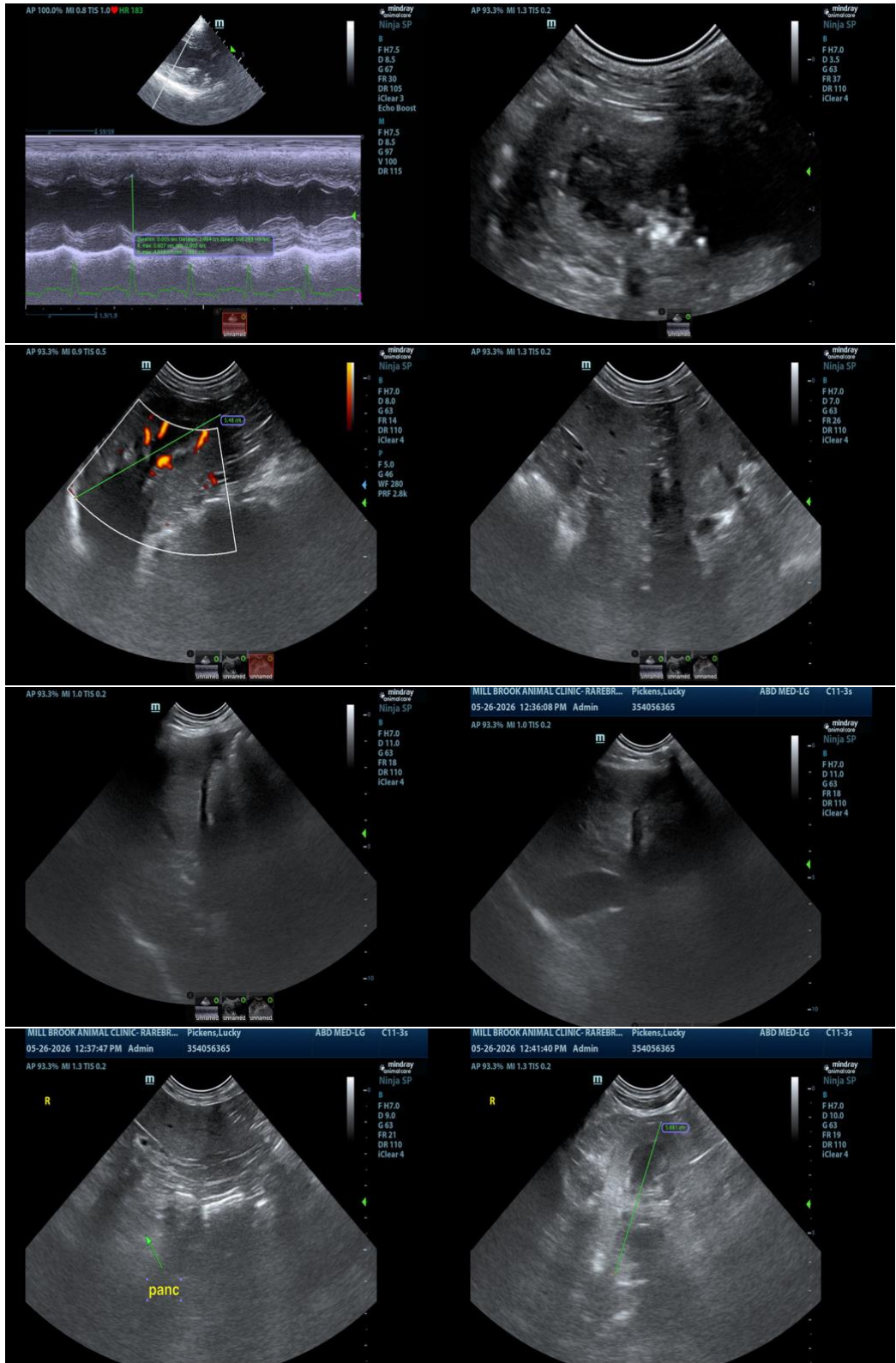
Dr. Michele  
Pffannenstiel

## INVOICE

16524

## DATE

05/26/26





## PATIENT

Lucky Pickens

## SPECIES

Canine

## BREED

Doodle

## SEX

Spayed Female

## AGE

12 Years 3 Months

## WEIGHT

33

## INTERPRETED BY

Eric Lindquist, DMV,  
DABVP(CFM), Cert.  
IVUSS

## IMAGING PERFORMED BY

Dr. Michele  
Pfannenstiel

## HOSPITAL NAME

Mill Brook Animal  
Clinic- VBF

## REFERRING VET

Dr. Michele  
Pfannenstiel

## INVOICE

16524

## DATE

05/26/26

The information and recommendations provided are based on the images presented by the referring veterinarian/sonographer. No evaluation can be communicated regarding pathology that was not visible in the image/video clips provided.

Thank you for this referral. If the clinical or image interpretation does not parallel your findings or if I can be of any further assistance, please contact me.

**Eric Lindquist, DMV, DABVP(CFM), Cert. IVUSS,**

CEO, Owner, Founder -- SonoPath.com

[info@SonoPath.com](mailto:info@SonoPath.com)