



PATIENT

Duke Edwards

SPECIES

Canine

BREED

American Pit Bull
Terrier

SEX

Neutered male

AGE

11 years

WEIGHT

63 lbs

INTERPRETED BY

Eric Lindquist, DMV
DABVP, Cert. IVUSS

IMAGING PERFORMED BY

Jeremiah Gabriel

HOSPITAL NAME

Central Jersey AH

REFERRING VET

Dr. Gabriel

INVOICE

77935

DATE

5/26/26

PRESENTING CLINICAL SIGNS

History: tachypnea, anorexia, lethargic.
Abnormal PE/Chem/CBC/UA Results: x ray shows pleural effusion

ULTRASONOGRAPHIC EXAMINATION

The heart revealed volume contraction and tamponade effect.

The cardiac presentation in this patient revealed a right auricular mass. The right auricular mass measured 3.1 x 4.9 cm. The mass extended from the base of the right auricle into the pericardium. There was a large amount of pericardial effusion. Pericardial space measured 2.5 cm of effusion. Concurrent pleural effusion was noted. There are areas of lung consolidation were also noted.

ULTRASONOGRAPHIC FINDINGS

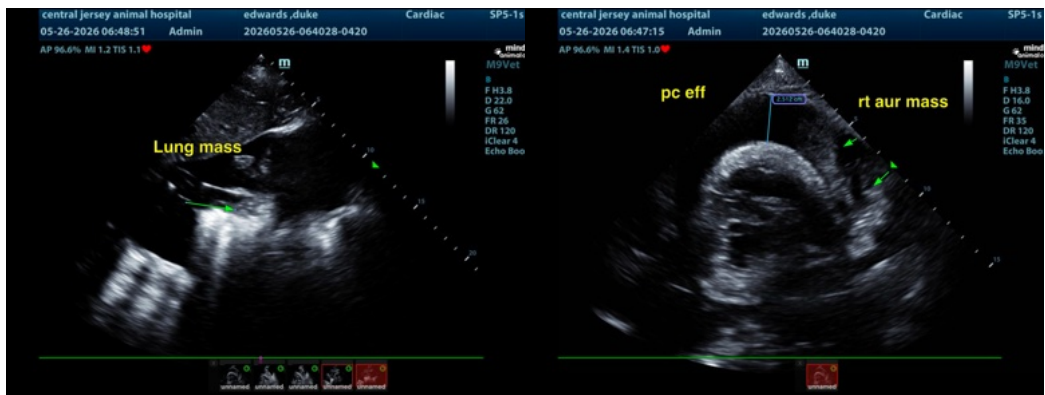Right auricular mass.

Pericardial effusion and concurrent pleural effusion.

Lung consolidation and lung masses noted in this patient.

INTERPRETATION OF THE FINDINGS & FURTHER RECOMMENDATIONS

Extensive thoracic neoplasia involving the heart base and lung tissue with pleural and pericardial effusion. Given the pleural effusion as well as the pericardial effusion, multi-centric thoracic neoplasia is suspected in addition to the right auricular mass. Hemangiosarcoma pattern. Prognosis is poor.





PATIENT

Duke Edwards

SPECIES

Canine

BREED

American Pit Bull
Terrier

SEX

Neutered male

AGE

11 years

WEIGHT

63 lbs

INTERPRETED BY

Eric Lindquist, DMV
DABVP, Cert. IVUSS

IMAGING PERFORMED BY

Jeremiah Gabriel

HOSPITAL NAME

Central Jersey AH

REFERRING VET

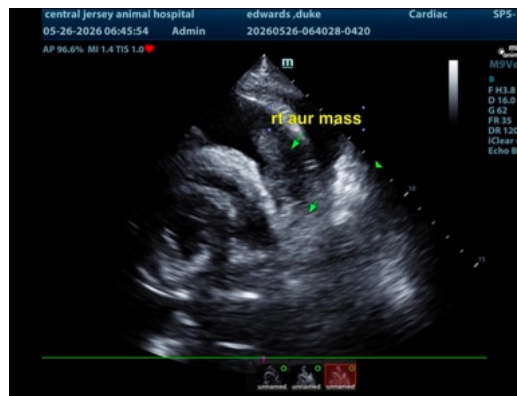
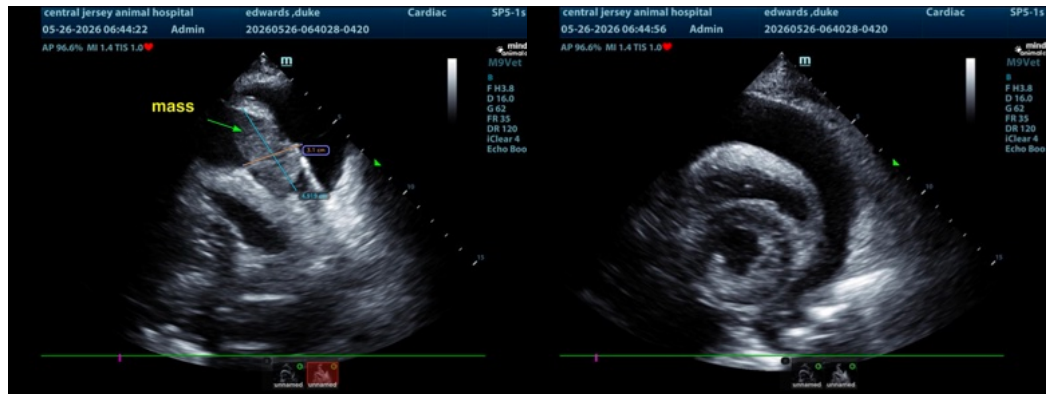
Dr. Gabriel

INVOICE

77935

DATE

5/26/26



The information and recommendations provided are based on the images presented by the referring veterinarian/sonographer. No evaluation can be communicated regarding pathology that was not visible in the image/video clips provided.

Thank you for this referral. If the clinical or image interpretation does not parallel your findings or if I can be of any further assistance please contact me.

Eric Lindquist, DMV, DABVP (CFM), Cert. IVUSS, CEO of SonoPath.com

info@SonoPath.com