



PATIENT

Angela Adamow-Wandall

SPECIES

Feline

BREED

Egyptian Mau

SEX

Spayed Female

AGE

14 Years

WEIGHT

8.13 lbs

PRESENTING CLINICAL SIGNS

Presented dyspneic. CXR showed fluid in her chest. The fluid is transparent serous fluid.

ULTRASONOGRAPHIC EXAMINATION OF THE HEART

FELINE CARDIAC PARAMETERS	BODY WEIGHT (lbs)	HR (BPM)	IVSd (cm)	LVIDd (cm)	LVWd (cm)	FS (%)	EF (%)
NORMAL PARAMETER	-----	150-240	0.3-0.6	1.0-2.1	0.25-0.6	35-67	80-100
PATIENT	8.13	180	0.57	1.35	0.31	44	79
FELINE CARDIAC PARAMETERS	LA/AO (M-mode)	LA/AO HEART BASE (Sisson)	LAD LA MAX 4 Chamber		LVOT VEL. (m/s)	RVOT VEL. (m/s)	IVRT (m/)
NORMAL PARAMETER	<1.5	1.6	0.7-1.7		<1.6	<1.3	40-60
PATIENT	1.7	>2.0	2.16		--	--	NM
Adapted from June Boon, Veterinary Echocardiography, 1998 Sisson D et al. JVIM 1991; 5: 232, Jacobs et al. Am J Vet Res 1985; 46:1705							

INTERPRETED BY

Eric Lindquist, DMV,
DABVP(CFM), Cert.
IVUSS

IMAGING PERFORMED BY

Dr. Renee Ziegler-Post

HOSPITAL NAME

For Cats Only
Veterinary Clinic

REFERRING VET

Dr. Renee Ziegler-Post

INVOICE

16523

DATE

05/26/26

Cardiac Presentation

The cardiac presentation in this patient presented with volume overload in all four chambers with slight pericardial effusion and severe mitral insufficiency. The pericardial effusion is owing to left-sided heart failure. Septal and free wall ventricular thicknesses were normal. Regional contractility was subnormal, consistent with unclassified cardiomyopathy. A moderate amount of myocardial remodeling was noted as well.

ULTRASONOGRAPHIC FINDINGS

- Left and right sided enlargement.

INTERPRETATION OF THE FINDINGS & FURTHER RECOMMENDATIONS

Management for left-sided heart failure is recommended. Recommend Pimobendan at 0.3 mg/kg BID, ACE inhibitor at 0.5 mg/kg SID, LASIX at 12.5 mg BID, reducing to 6.25 mg BID after 36 to 48 hours, depending upon blood pressures. BUN, creatinine, respiratory rate and Plavix™ are also indicated with recheck echo in three to four weeks.

The patient is at risk for sudden death. Prognosis is guarded. Taurine levels should be evaluated. Infectious disease screening should also be evaluated to ensure these are not complicating issues.



PATIENT

Angela Adamow-Wandall

SPECIES

Feline

BREED

Egyptian Mau

SEX

Spayed Female

AGE

14 Years

WEIGHT

8.13 lbs

INTERPRETED BY

Eric Lindquist, DMV,
DABVP(CFM), Cert.
IVUSS

IMAGING PERFORMED BY

Dr. Renee Ziegler-Post

HOSPITAL NAME

For Cats Only
Veterinary Clinic

REFERRING VET

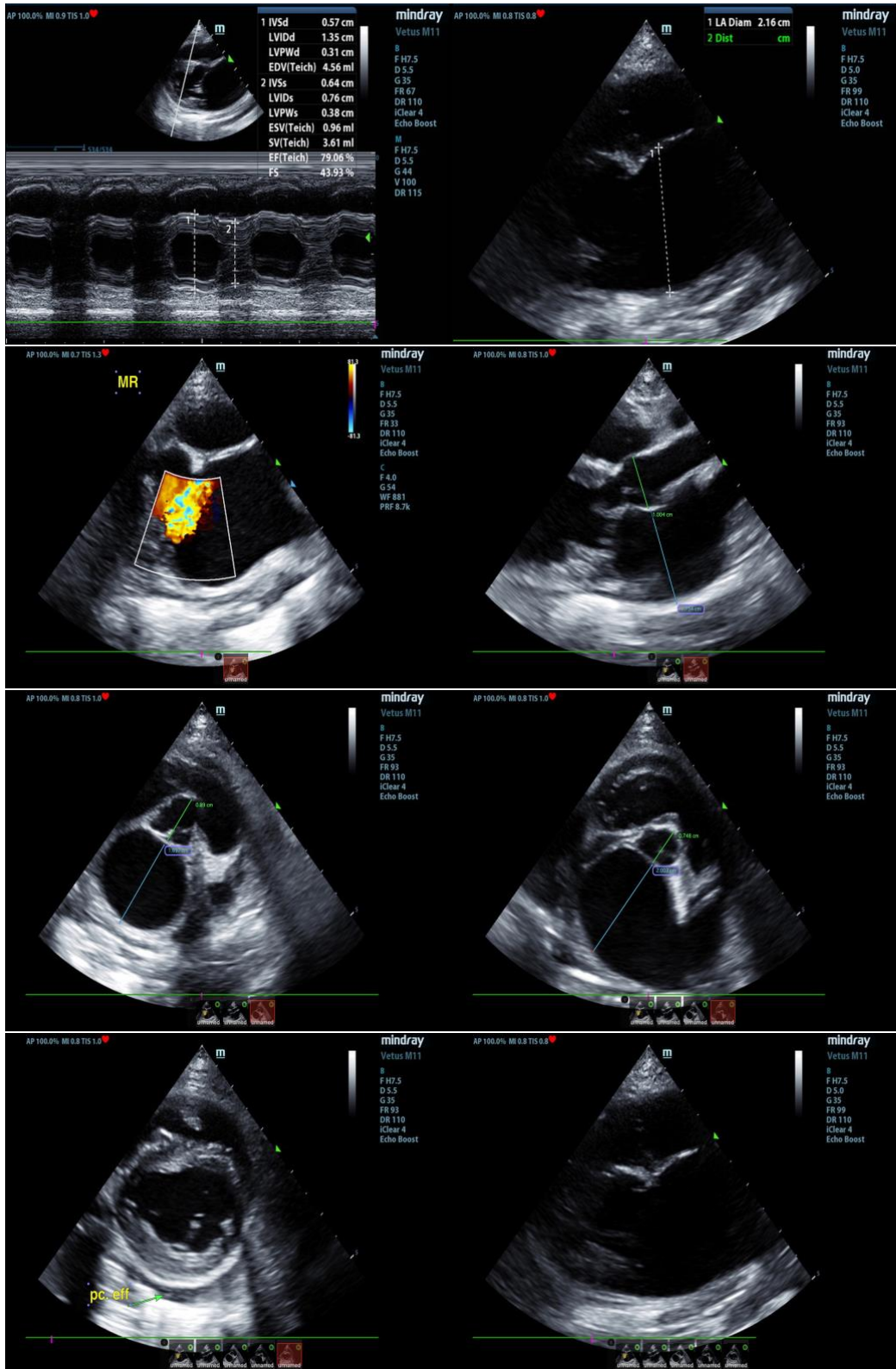
Dr. Renee Ziegler-Post

INVOICE

16523

DATE

05/26/26





PATIENT

Angela Adamow-Wandall

SPECIES

Feline

BREED

Egyptian Mau

SEX

Spayed Female

AGE

14 Years

WEIGHT

8.13 lbs

INTERPRETED BY

Eric Lindquist, DMV,
DABVP(CFM), Cert.
IVUSS

IMAGING PERFORMED BY

Dr. Renee Ziegler-Post

HOSPITAL NAME

For Cats Only
Veterinary Clinic

REFERRING VET

Dr. Renee Ziegler-Post

INVOICE

16523

DATE

05/26/26

The information and recommendations provided are based on the images presented by the referring veterinarian/sonographer. No evaluation can be communicated regarding pathology that was not visible in the image/video clips provided.

Thank you for this referral. If the clinical or image interpretation does not parallel your findings or if I can be of any further assistance, please contact me.

Eric Lindquist, DMV, DABVP(CFM), Cert. IVUSS,

CEO, Owner, Founder -- SonoPath.com

info@SonoPath.com