



PATIENT PRESENTING CLINICAL SIGNS

Zeus Murray History: left sided diastolic murmur

SPECIES ULTRASONOGRAPHIC EXAMINATION OF THE HEART

Canine

BREED

Bullmastiff

SEX

Intact male

AGE

1 year

WEIGHT

116 lbs

INTERPRETED BY

Eric Lindquist, DMV
DABVP, Cert. IVUSS

IMAGING PERFORMED BY

Diane McFadden, RVT

HOSPITAL NAME

North Warren AH

REFERRING VET

Dr. Corrado

INVOICE

30754

DATE

5/26/22

The echocardiogram in this patient demonstrated normal **left atrial** size based on 3 separate methods of LA evaluation. The cranial and caudal **mitral** valve leaflets presented normal linear structure, extension in systole, and union in diastole with normal kinesis. The **left ventricle** presented thicknesses with linear contour and was not dilated nor restricted. The **myocardium** presented normal echogenicity without subjective evidence of significant fibrotic or ischemic disease. **Contractility** of the ventricular walls was adequate and in normal range for this patient evidenced by the fractional shortening measurement and subjective evaluation of the different regions of the myocardium. The **left ventricular outflow** tract revealed minor idiopathic increased left ventricular outflow velocity. This is likely the source of the murmur. The **right atrium** and auricle revealed normal size, structure and content. No evidence of masses was noted. **Tricuspid** valvular assessment demonstrated adequate linear morphology and kinesis. The **right ventricle** was of normal size (1/3 diameter of LV), chordae structure, myocardial echogenicity and thickness. **Pulmonary outflow** tract assessment revealed normal valve structure, laminar flow, and diameter (approx.1:1 pa/ao ratio). No visible **pericardial** or free pleura fluid was noted. The cranial **mediastinum and pericardial and extra-cardiac regions** were free of masses in the visible window.

CANINE CARDIAC PARAMETERS	MR VMAX (m/s)	TR VMAX (m/s)	LA/AO (Boon method)	LA/AO (Heart Base; Swe)	FS (%)	EF (%)	EPSS (cm)
NORMAL PARAMETER	4.5-5.5	<2.7	1.3	<1.3	28-40	40-100	<0.6
PATIENT			1.36	1.25	48	80	0.39
CANINE CARDIAC PARAMETERS	HR (BPM)	AV VMAX (m/s)	PV MAX (m/s)	BODY WEIGHT (kg)	LA (2D short axis Base view) (cm)	LVIDd (Avg; 2D and m-mode short axis) (cm)	LVIDs (Avg; 2D and m-mode short axis) (cm)
NORMAL PARAMETER	50-100	0.7-1.7	0.7-1.6				
PATIENT	111	2.1	1.9	116 lbs	3.5	4.49	

ULTRASONOGRAPHIC FINDINGS

Mildly idiopathic increased LVOT, not clinically significant.

INTERPRETATION OF THE FINDINGS & FURTHER RECOMMENDATIONS

There is no evidence of congenital disease. This is essentially a flow murmur. No therapy is warranted. If the murmur increases in grade over the next year then recheck echocardiogram is recommended over a year.



PATIENT

Zeus Murray

SPECIES

Canine

BREED

Bullmastiff

SEX

Intact male

AGE

1 year

WEIGHT

116 lbs

INTERPRETED BY

Eric Lindquist, DMV
DABVP, Cert. IVUS

**IMAGING
PERFORMED BY**

Diane McFadden, RVT

HOSPITAL NAME

North Warren AH

REFERRING VET

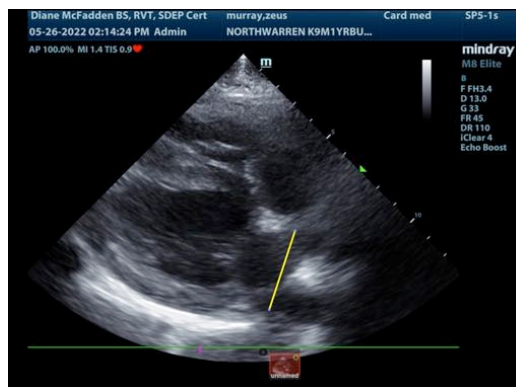
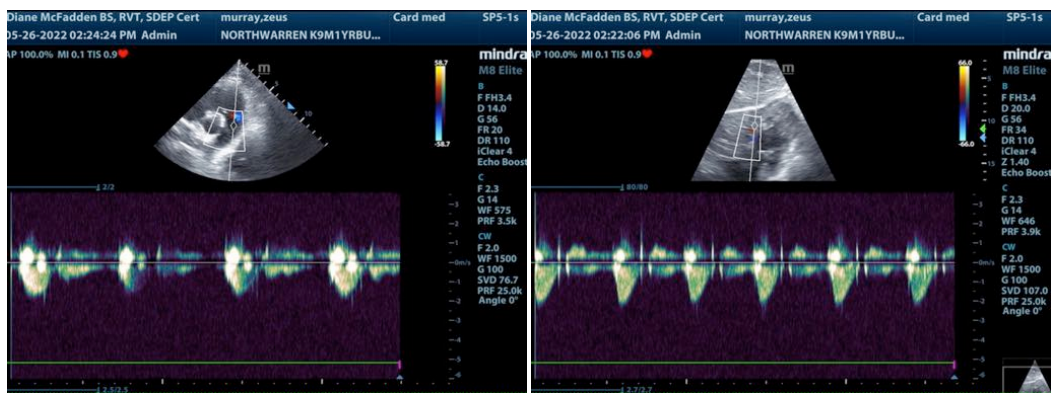
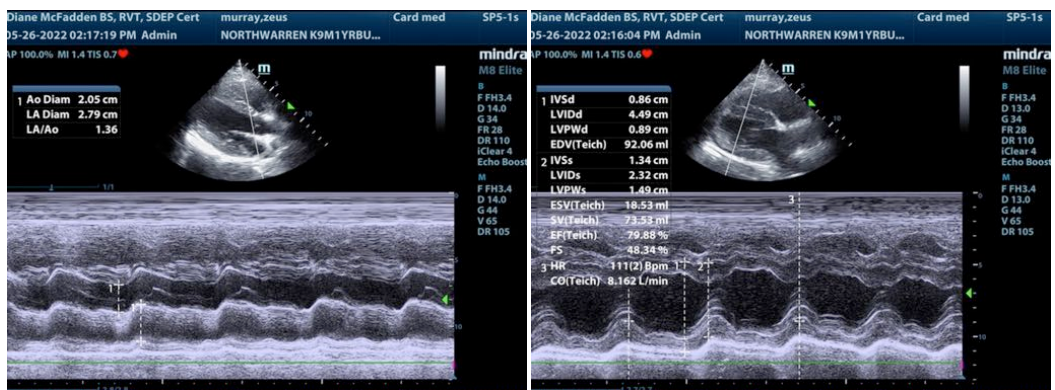
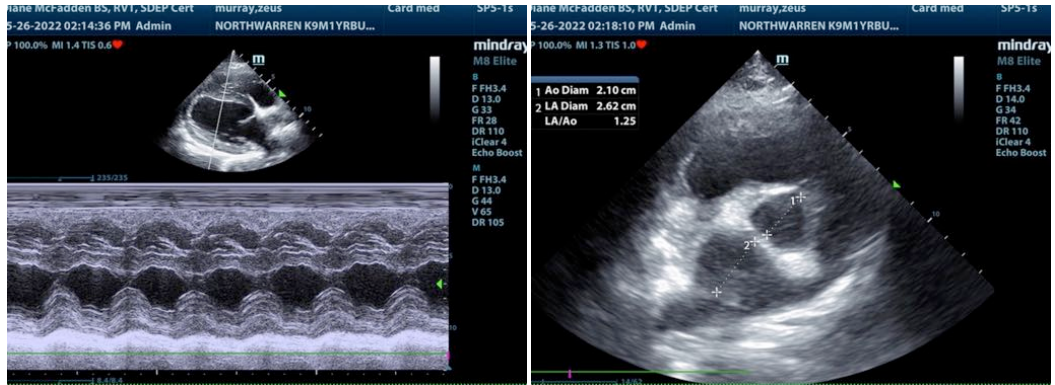
Dr. Corrado

INVOICE

30754

DATE

5/26/22





PATIENT

Zeus Murray

The information and recommendations provided are based on the images presented by the referring veterinarian/sonographer. No evaluation can be communicated regarding pathology that was not visible in the image/video clips provided.

SPECIES

Canine

Thank you for this referral. If the clinical or image interpretation does not parallel your findings or if I can be of any further assistance please contact me.

BREED

Bullmastiff

Eric Lindquist, DMV, DABVP, Cert. IVUSS, CEO of SonoPath.com
Info@SonoPath.com

SEX

Intact male

AGE

1 year

WEIGHT

116 lbs

INTERPRETED BY

Eric Lindquist, DMV
DABVP, Cert. IVUSS

**IMAGING
PERFORMED BY**

Diane McFadden, RVT

HOSPITAL NAME

North Warren AH

REFERRING VET

Dr. Corrado

INVOICE

30754

DATE

5/26/22