



PATIENT

Roscoe Maxwell

SPECIES

Canine

BREED

Terrier Cross

SEX

Neutered male

AGE

9 years

WEIGHT

17 lbs

INTERPRETED BY

Eric Lindquist, DMV
DABVP, Cert. IVUSS

IMAGING PERFORMED BY

Dr. Kitz

HOSPITAL NAME

Woodlands AH

REFERRING VET

Dr. Kitz

INVOICE

30764

DATE

5/26/22

PRESENTING CLINICAL SIGNS

History: patient presented for senior annual wellness with no history of issues
 Abnormal PE/Chem/CBC/UA Results: 3+ hematuria on free-catch urine sample, 11-20 RBCs/hpf, repeatable on multiple U/As with inactive sediment on all and high USG between 1.051 and 1.068; no crystals; no bacteria; negative urine culture from cysto normal BUN at 20, creatinine at 0.8 normal systolic BP at 130 normal penis on extrusion, and prepuce, normal rectal exam radiographs of urinary tract boring with no evidence of uroliths ultrasound performed to rule out other possible causes including neoplasia just don't see any obvious cause for significant and repeatable hematuria and the dog is acting fine

ULTRASONOGRAPHIC EXAMINATION OF THE ABDOMEN

Urinary System

The **urinary bladder**, trigone, and pelvic urethra presented normal thicknesses and normal tone. The pelvic urethra was imaged 2.0 cm beyond the cystourethral junction. The ureters were not visible which is normal. No uroliths or sediment were visualized and anechoic urine was present. No evidence of inflammatory or neoplastic changes was noted. Ureteral papillae were normal.

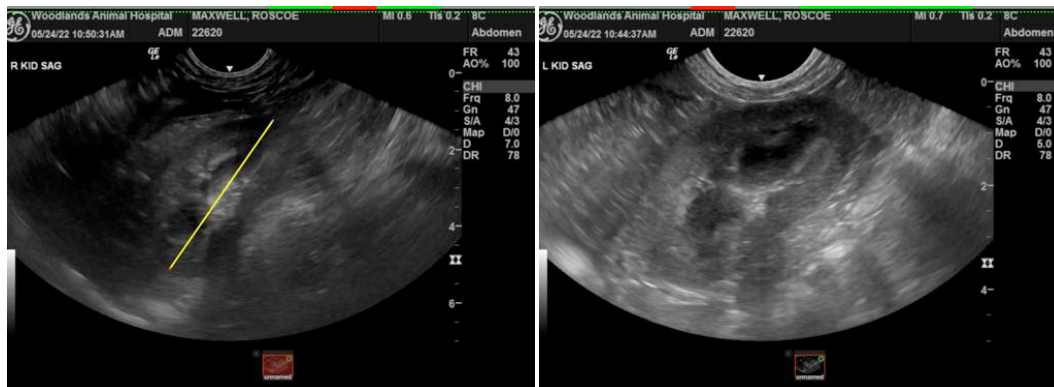
The **kidneys** revealed normal size and structure, corticomedullary definition and ratio for this age. The cortices presented largely uniform texture with normal echogenic relationship to liver and spleen. Medullary structure differed distinctly from the cortex and no evidence of pelvic dilation was present. The capsules were acceptably uniform without significant irregularities. The left kidney and the right kidney measured 4.7 cm.

ULTRASONOGRAPHIC FINDINGS

Structurally normal urinary tract.

INTERPRETATION OF THE FINDINGS & FURTHER RECOMMENDATIONS

There was no evidence of pathology. Occult UTI, underlying coagulopathy, idiopathic cystitis/hematuria are all possible.





PATIENT

Roscoe Maxwell

SPECIES

Canine

BREED

Terrier Cross

SEX

Neutered male

AGE

9 years

WEIGHT

17 lbs

INTERPRETED BY

Eric Lindquist, DMV
DABVP, Cert. IVUSS

**IMAGING
PERFORMED BY**

Dr. Kitz

HOSPITAL NAME

Woodlands AH

REFERRING VET

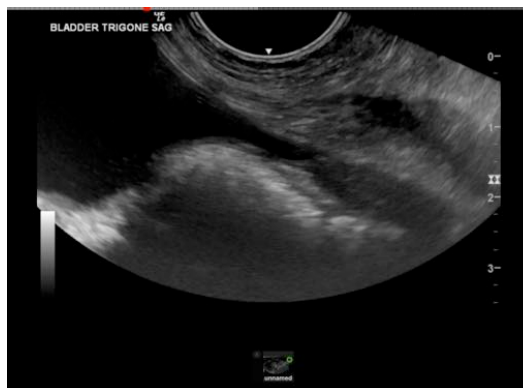Dr. Kitz

INVOICE

30764

DATE

5/26/22



The information and recommendations provided are based on the images presented by the referring veterinarian/sonographer. No evaluation can be communicated regarding pathology that was not visible in the image/video clips provided.

Thank you for this referral. If the clinical or image interpretation does not parallel your findings or if I can be of any further assistance please contact me.

Eric Lindquist, DMV, DABVP, Cert. IVUSS, CEO of SonoPath.com
info@SonoPath.com