



PATIENT PRESENTING CLINICAL SIGNS

Peach Giraldo Hepatopathy HGE poss fb

SPECIES ULTRASONOGRAPHIC EXAMINATION OF THE ABDOMEN

Canine **Urinary System**

BREED Corgi
The **urinary bladder**, trigone, and pelvic urethra presented normal thicknesses and normal tone. The ureters were not visible which is normal. No uroliths or sediment were visualized and anechoic urine was present. No evidence of inflammatory or neoplastic changes were noted. Ureteral papillae were normal.

SEX Female
The **kidneys** revealed normal size and structure, corticomedullary definition and ratio for this age. The cortices presented largely uniform texture with normal echogenic relationship to liver and spleen. Medullary structure differed distinctly from the cortex and no evidence of pelvic dilation was present. The capsules were acceptably uniform without significant irregularities. The right kidney measured 4.85 cm. The left kidney measured 4.8 cm.

AGE Adrenal Glands

5 Months
Both **adrenal glands** were visualized and recognized as having normal shape, size, position and echogenicity for this breed. The phrenic vasculature, glandular echogenicity and detail were unremarkable. Capsule, cortex, and medullary definition were normal for this age patient. The left adrenal gland measured 1.14 cm x 0.35 cm at the caudal pole and 0.37 cm at the cranial pole. The right adrenal gland measured 0.60 cm at the cranial pole and 0.40 cm at the caudal pole.

WEIGHT Spleen
18 Pounds

INTERPRETED BY
Eric Lindquist, DMV
DABVP, Cert. IVUSS
The **spleen** presented a smooth homogeneous parenchyma hyperechoic to liver and renal cortical parenchyma. The capsule was smooth without noticeable expansion or deviation from within the spleen or adjacent pathology. The splenic vasculature demonstrated normal volume without signs of congestion or thrombosis. No sonographic evidence of acute or chronic inflammatory, neoplastic, or infarctual changes were noted.

IMAGING PERFORMED BY Liver

Jenn
The **liver** images submitted revealed subjectively normal liver size, contour, and structure. Parenchymal echogenicity was naturally coarse and hypoechoic to the spleen. Vascular and biliary tracts were of normal volume with no evidence of congestion. The gallbladder presented acceptably thin walls with primarily anechoic content. The cystic and common bile ducts were normal. No pathological hepatic lymphadenopathy was evident. No overt structural evidence of inflammatory, infiltrative or regenerative pathology was evident.

HOSPITAL NAME Gastrointestinal
Rockaway AH

REFERRING VET
Dr. Maniar
Examination of the **gastrointestinal tract** revealed a stomach and intestine free of stasis, of normal wall thickness, acceptable curvilinear mural detail, and peristaltic activity. Small and large intestine demonstrated normal luminal chyme and stool consistency respectively. No obstructive or overt infiltrative disease was noted. No associated abnormal lymphatic activity was noted.

INVOICE Pancreas
37998

DATE
5/26/22
The base and limbs of the **pancreas** were observed to be largely isoechoic to surrounding omental fat. Pancreatic duct and capsular contour were acceptably normal and parenchyma respected normal curvilinear patterns. No overt evidence of active inflammatory or neoplastic disease was noted.



PATIENT

Peach Giraldo

ULTRASONOGRAPHIC FINDINGS

- Normal abdomen

SPECIES

Canine

INTERPRETATION OF THE FINDINGS & FURTHER RECOMMENDATIONS

Supportive care should prove effective. No evidence of obstruction. Dietary indiscretion, food intolerance, structurally insignificant inflammatory bowel or occult parasitism and occult Addison's are all potentials.

BREED

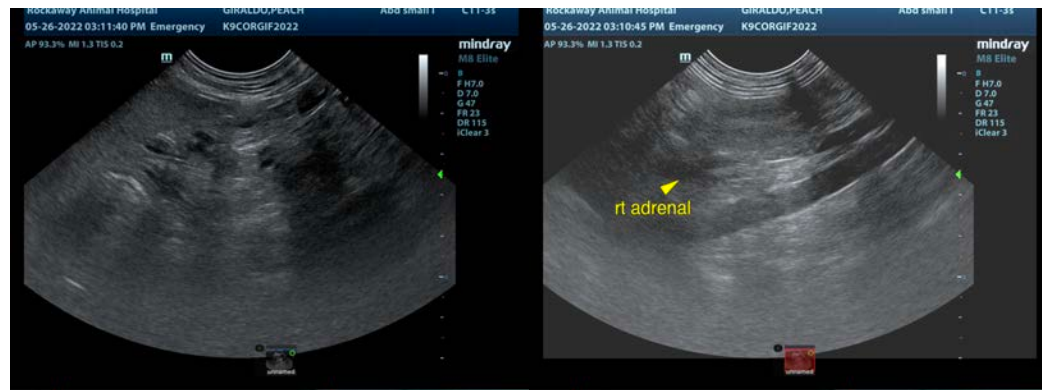
Corgi

SEX

Female

AGE

5 Months

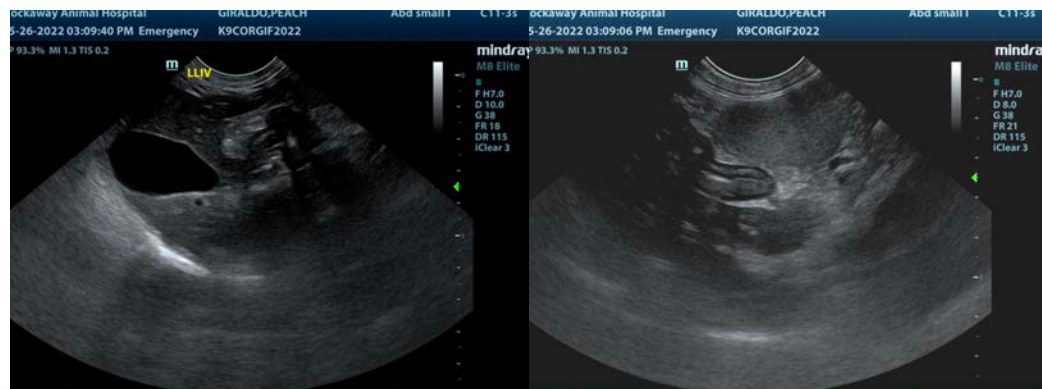


WEIGHT

18 Pounds

INTERPRETED BY

Eric Lindquist, DMV
DABVP, Cert. IVUSS

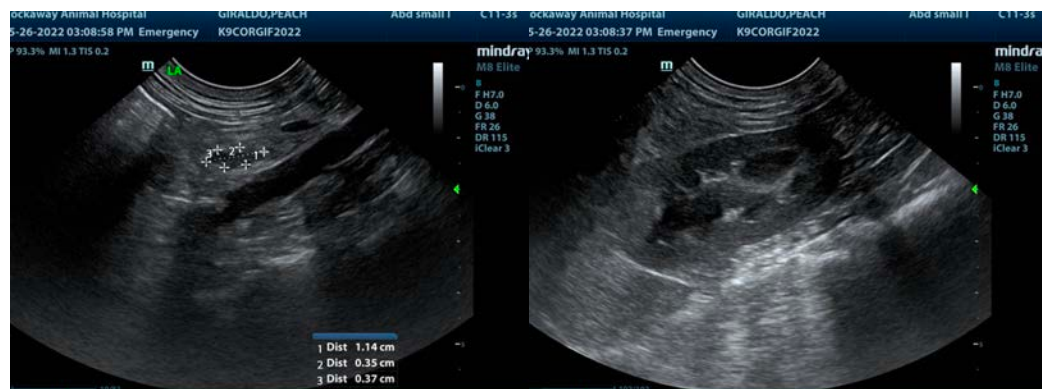


IMAGING PERFORMED BY

Jenn

HOSPITAL NAME

Rockway AH



REFERRING VET

Dr. Maniar

INVOICE

37998

DATE

5/26/22



PATIENT

Peach Giraldo

The information and recommendations provided are based on the images presented by the referring veterinarian/sonographer. No evaluation can be communicated regarding pathology that was not visible in the image/video clips provided.

SPECIES

Canine

Thank you for this referral. If the clinical or image interpretation does not parallel your findings or if I can be of any further assistance please contact me.

Eric Lindquist, DMV, DABVP, Cert. IVUSS, CEO of SonoPath.com

info@SonoPath.com

BREED

Corgi

SEX

Female

AGE

5 Months

WEIGHT

18 Pounds

INTERPRETED BY

Eric Lindquist, DMV

DABVP, Cert. IVUSS

IMAGING PERFORMED BY

Jenn

HOSPITAL NAME

Rockaway AH

REFERRING VET

Dr. Maniar

INVOICE

37998

DATE

5/26/22