



PATIENT PRESENTING CLINICAL SIGNS

Passion Bourassa Bred 4/4/22 and 4/6/22, took XRAY on 5/24/2022 and only saw 2 possible faint skeletons. Needing ultrasound to verify pregnancy and puppy count.

SPECIES LIMITED ULTRASONOGRAPHIC EXAMINATION

Canine

BREED

American Bully

SEX

Intact Female

AGE

3 Years

WEIGHT

96 Pounds

The reproductive tract was imaged. Two viable fetuses noted, measuring up to 7.7 cm from tail base to crown of the head. Anechoic amniotic fluid present. Placenta and uterus were unremarkable. Curvilinear patterns were maintained. No free fluid. No evidence of pathology. The skeletal structures were partially ossified. Fetal movement was normal.

One regressing amniotic sac appeared to be present. No evidence of inflammation.

ULTRASONOGRAPHIC FINDINGS

- Two live fetuses, one regressing amniotic sac

INTERPRETATION OF THE FINDINGS & FURTHER RECOMMENDATIONS

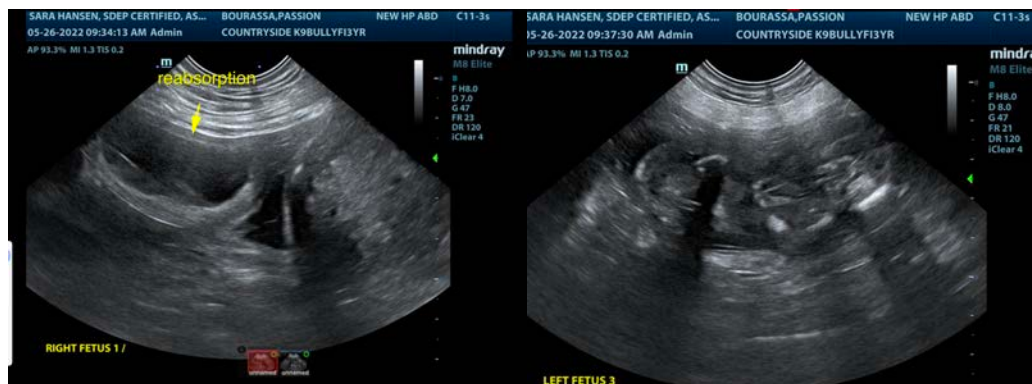
6-7 weeks gestation as far as fetal development. The two fetuses with solid skeletal structures appear to be viable with normal movement and heartbeats.

INTERPRETED BY

Eric Lindquist, DMV
DABVP, Cert. IVUSS

IMAGING PERFORMED BY

Sara Hansen



HOSPITAL NAME

Countryside AC

REFERRING VET

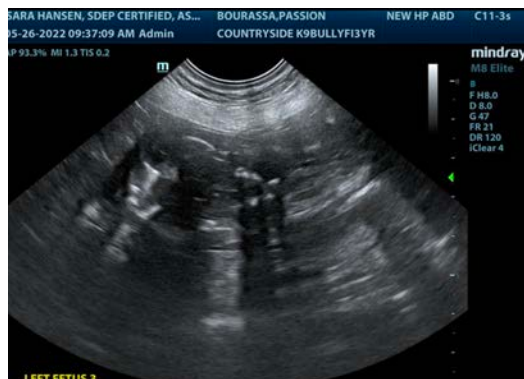Dr. Cox

INVOICE

38017

DATE

5/26/22





PATIENT

Passion Bourassa

The information and recommendations provided are based on the images presented by the referring veterinarian/sonographer. No evaluation can be communicated regarding pathology that was not visible in the image/video clips provided.

SPECIES

Canine

Thank you for this referral. If the clinical or image interpretation does not parallel your findings or if I can be of any further assistance please contact me.

BREED

American Bully

Eric Lindquist, DMV, DABVP, Cert. IVUSS, CEO of SonoPath.com

SEX

Intact Female

info@SonoPath.com

AGE

3 Years

WEIGHT

96 Pounds

INTERPRETED BY

Eric Lindquist, DMV
DABVP, Cert. IVUSS

**IMAGING
PERFORMED BY**

Sara Hansen

HOSPITAL NAME

Countryside AC

REFERRING VET

Dr. Cox

INVOICE

38017

DATE

5/26/22