



PATIENT PRESENTING CLINICAL SIGNS

Chanel Blethen

History: patient presented with facial swelling, and has a bad upper canine tooth that needs extracted pre-anesthetic work-up

SPECIES

Abnormal PE/Chem/CBC/UA Results: Grade II-III left sternal murmur detected on exam elevated cardiac pro BNP @ 946 normal thyroid @ 2.2 normal systolic Doppler BP @ 126

Feline

ULTRASONOGRAPHIC EXAMINATION OF THE HEART

BREED

The echocardiogram in this patient demonstrated normal **left atrial** size based on 3 separate LA measurements. The cranial and caudal **mitral** valve leaflets presented normal linear structure and kinetics.. The **left ventricle** presented normal thicknesses with linear contour and was not dilated nor restricted. The **myocardium** presented normal echogenicity without subjective evidence of significant fibrotic or ischemic disease. **Contractility** of the ventricular walls was adequate and in normal range for this patient evidenced by the fractional shortening measurement and subjective evaluation of the different regions and angles of the myocardium. Septal impingement upon the **left ventricular outflow** tract is present. This is likely the cause of murmur. The **right atrium** and auricle revealed normal size, structure and content. No evidence of masses was noted or chamber overload. **Tricuspid** valvular assessment demonstrated adequate linear morphology and kinetics. The **right ventricle** was of normal size (1/3 diameter of LV), chordae structure, myocardial echogenicity and thickness. **Pulmonic** tract assessment revealed normal valve structure, laminar flow, and diameter (approx.1:1 pa/ao ratio). No visible **pericardial** or free pleura fluid was noted or extra cardiac pathology in the visible planes. The cranial **mediastinum** and **pericardial regions** were free of masses in the visible window.

Domestic Medium Hair

SEX

Neutered male

AGE

13 years

WEIGHT

11.1 lbs

INTERPRETED BY

Eric Lindquist, DMV DABVP, Cert. IVUSS

IMAGING PERFORMED BY

Dr. Kitz

HOSPITAL NAME

Woodlands AH

REFERRING VET

Dr. Kitz

FELINE CARDIAC PARAMETERS	BODY WEIGHT (kg)	HR (BPM)	IVSd (cm)	LVIDd (cm)	LVWd (cm)	FS (%)	EF (%)
NORMAL PARAMETER	-----	150-240	0.3-0.6	1.0-2.1	0.25-0.6	35-67	80-100
PATIENT		NM	0.57	1.3	0.6	50	
FELINE CARDIAC PARAMETERS	LA/AO (Boon)	LA/AO HEART BASE (Sisson)	LA 2D 4-chamber long axis AS to FW (Sisson) (cm)	LVOT VEL. (m/s)	RVOT VEL. (m/s)	IVRT (m/)	
NORMAL PARAMETER	<1.5	0.88-1.79	0.7-1.7	<1.6	<1.3	40-60	
PATIENT	1.4	1.3		1.36		NM	

Adapted from June Boon, Veterinary Echocardiography, 1998
Sisson D et al. JVIM 1991; 5: 232, Jacobs et al. Am J Vet Res 1985; 46:1705

INVOICE ULTRASONOGRAPHIC FINDINGS

30763

Essentially normal echocardiogram.

Trivial left ventricular hypertrophy.

DATE

5/27/22

Minor, compensated left ventricular hypertrophy with slight fixed LVOT impingement. This is not clinically significant.



PATIENT

Chanel Blethen

INTERPRETATION OF THE FINDINGS & FURTHER RECOMMENDATIONS

There is no evidence of volume overload. No contraindication to anesthetic procedure as long as tricuspid and blood pressure measurements are normal. Torbutrol premed, Propofol induction, and Isoflurane maintenance is recommended.

SPECIES

Feline

BREED

Domestic Medium Hair

SEX

Neutered male

AGE

13 years

WEIGHT

11.1 lbs

INTERPRETED BY

Eric Lindquist, DMV
DABVP, Cert. IVUSS

IMAGING PERFORMED BY

Dr. Kitz

HOSPITAL NAME

Woodlands AH

REFERRING VET

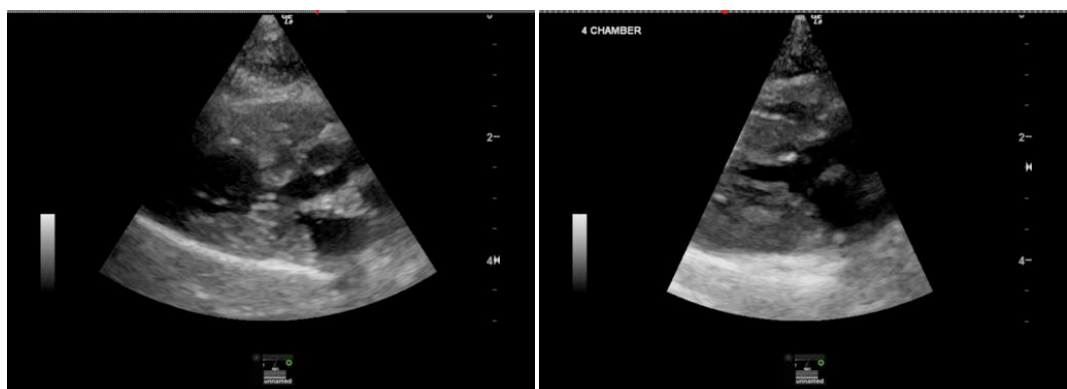
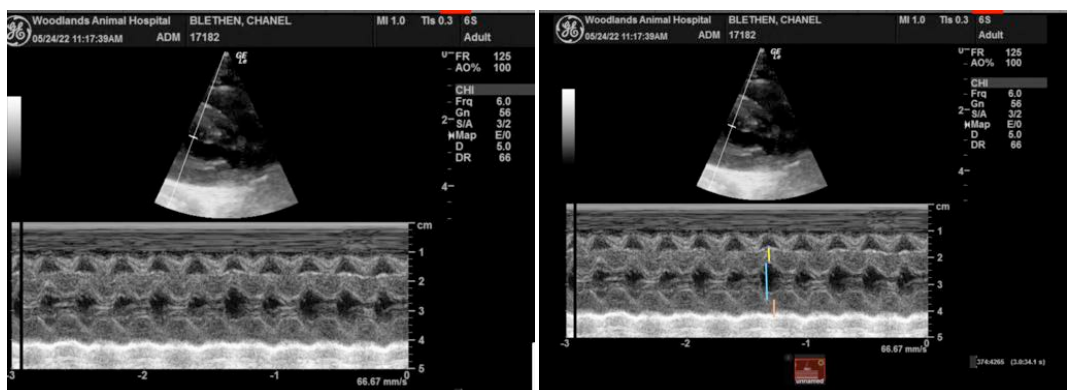
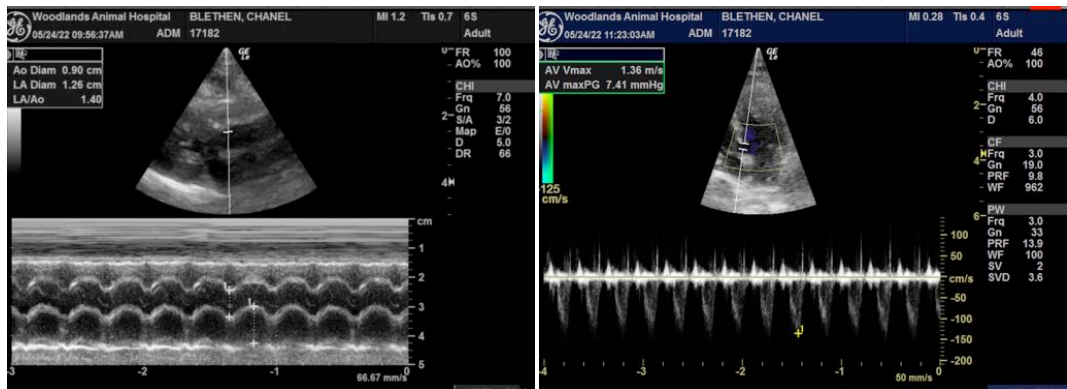
Dr. Kitz

INVOICE

30763

DATE

5/27/22



The information and recommendations provided are based on the images presented by the referring veterinarian/sonographer. No evaluation can be communicated regarding pathology that was not visible in the image/video clips provided.



PATIENT

Chanel Blethen

Thank you for this referral. If the clinical or image interpretation does not parallel your findings or if I can be of any further assistance please contact me.

SPECIES

Feline

Eric Lindquist, DMV, DABVP, Cert. IVUSS, CEO of SonoPath.com
info@SonoPath.com

BREED

Domestic Medium Hair

SEX

Neutered male

AGE

13 years

WEIGHT

11.1 lbs

INTERPRETED BY

Eric Lindquist, DMV
DABVP, Cert. IVUSS

**IMAGING
PERFORMED BY**

Dr. Kitz

HOSPITAL NAME

Woodlands AH

REFERRING VET

Dr. Kitz

INVOICE

30763

DATE

5/27/22