



PATIENT

Mars Kumar

SPECIES

Canine

BREED

Terrier Mix

SEX

Neutered male

AGE

1 year

WEIGHT

22 lbs

INTERPRETED BY

Eric Lindquist, DMV
DABVP, Cert. IVUSS

IMAGING PERFORMED BY

Juli Sorenson

HOSPITAL NAME

Emergency
Veterinarians of Idaho

REFERRING VET

Dr. Sorenson

INVOICE

77906

DATE

5/24/26

PRESENTING CLINICAL SIGNS

History: 48hr history of vomiting, hypersalivation, anorexia. Bloodwork at pDVM shows pancreatic lipase >2000, rads concerning for pyloric outflow obstruction.

ULTRASONOGRAPHIC EXAMINATION OF THE ABDOMEN

Urinary System

The **urinary bladder**, trigone, and pelvic urethra presented normal thicknesses and normal tone. The ureters were not visible which is normal. No uroliths or sediment were visualized and anechoic urine was present. No evidence of inflammatory or neoplastic changes was noted. Ureteral papillae were normal.

The **kidneys** revealed normal size and structure, corticomedullary definition and ratio for this age. The cortices presented largely uniform texture with normal echogenic relationship to liver and spleen. Medullary structure differed distinctly from the cortex and no evidence of pelvic dilation was present. The capsules were acceptably uniform without significant irregularities. The left kidney measured 3.1 cm. The right kidney measured 4.8 cm.

Adrenal Glands

Both **adrenal glands** were visualized and recognized as having normal shape, size, position and echogenicity for this breed. The phrenic vasculature, glandular echogenicity and detail were unremarkable. Capsule, cortex, and medullary definition were normal for this age patient. The left adrenal gland measured 0.3 cm. The right adrenal gland measured 0.4 cm.

Spleen

The **spleen** presented a smooth homogeneous parenchyma hyperechoic to liver and renal cortical parenchyma. The capsule was smooth without noticeable expansion or deviation from within the spleen or adjacent pathology. The splenic vasculature demonstrated normal volume without signs of congestion or thrombosis. No sonographic evidence of acute or chronic inflammatory, neoplastic, or infarctual changes was noted.

Liver

The **liver** images submitted revealed subjectively normal liver size, contour, and structure. Parenchymal echogenicity was naturally coarse and hypoechoic to the spleen. Vascular and biliary tracts were of normal volume with no evidence of congestion. The gallbladder presented acceptably thin walls with primarily anechoic content. The cystic and common bile ducts were normal. No pathological hepatic lymphadenopathy was evident. No overt structural evidence of inflammatory, infiltrative or regenerative pathology was evident. Some **pleural effusion** was noted through the diaphragm.



PATIENT

Mars Kumar

SPECIES

Canine

BREED

Terrier Mix

SEX

Neutered male

AGE

1 year

WEIGHT

22 lbs

INTERPRETED BY

Eric Lindquist, DMV
DABVP, Cert. IVUSS

IMAGING PERFORMED BY

Juli Sorenson

HOSPITAL NAME

Emergency Veterinarians of Idaho

REFERRING VET

Dr. Sorenson

INVOICE

77906

DATE

5/24/26

Gastrointestinal

A **gastroduodenal** fabric foreign body noted in this patient with some gastric fundic thickening. Gastric fundic thickening was noted as well as gastric stasis. The small intestines and colon were unremarkable with normal curvilinear mural patterns and content.

Pancreas

The base and limbs of the **pancreas** were observed to be largely isoechoic to surrounding omental fat. Pancreatic duct and capsular contour were acceptably normal and parenchyma respected normal curvilinear patterns. No overt evidence of active inflammatory or neoplastic disease was noted.

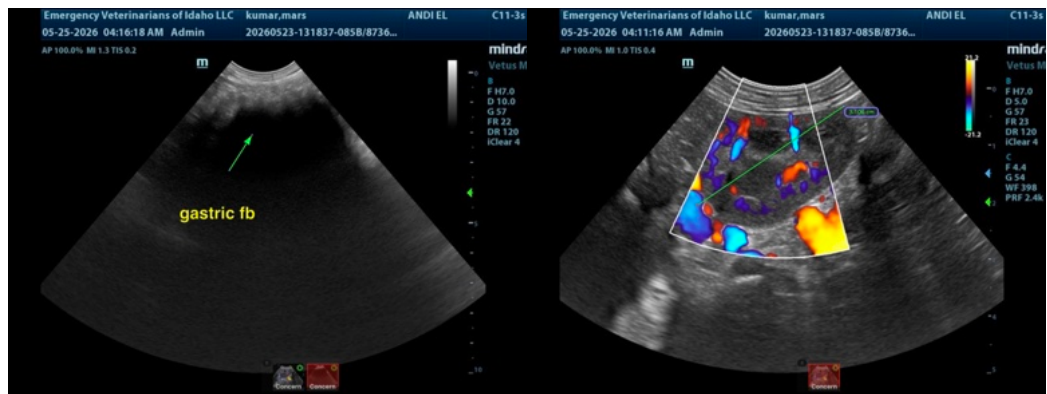
ULTRASONOGRAPHIC FINDINGS

Fabric foreign matter.

Pleural effusion.

INTERPRETATION OF THE FINDINGS & FURTHER RECOMMENDATIONS

Surgery is necessary. GI biopsies are warranted at the time of surgery to rule out underlying disease.





PATIENT

Mars Kumar

SPECIES

Canine

BREED

Terrier Mix

SEX

Neutered male

AGE

1 year

WEIGHT

22 lbs

INTERPRETED BY

Eric Lindquist, DMV
DABVP, Cert. IVUSS

IMAGING PERFORMED BY

Juli Sorenson

HOSPITAL NAME

Emergency Veterinarians of Idaho

REFERRING VET

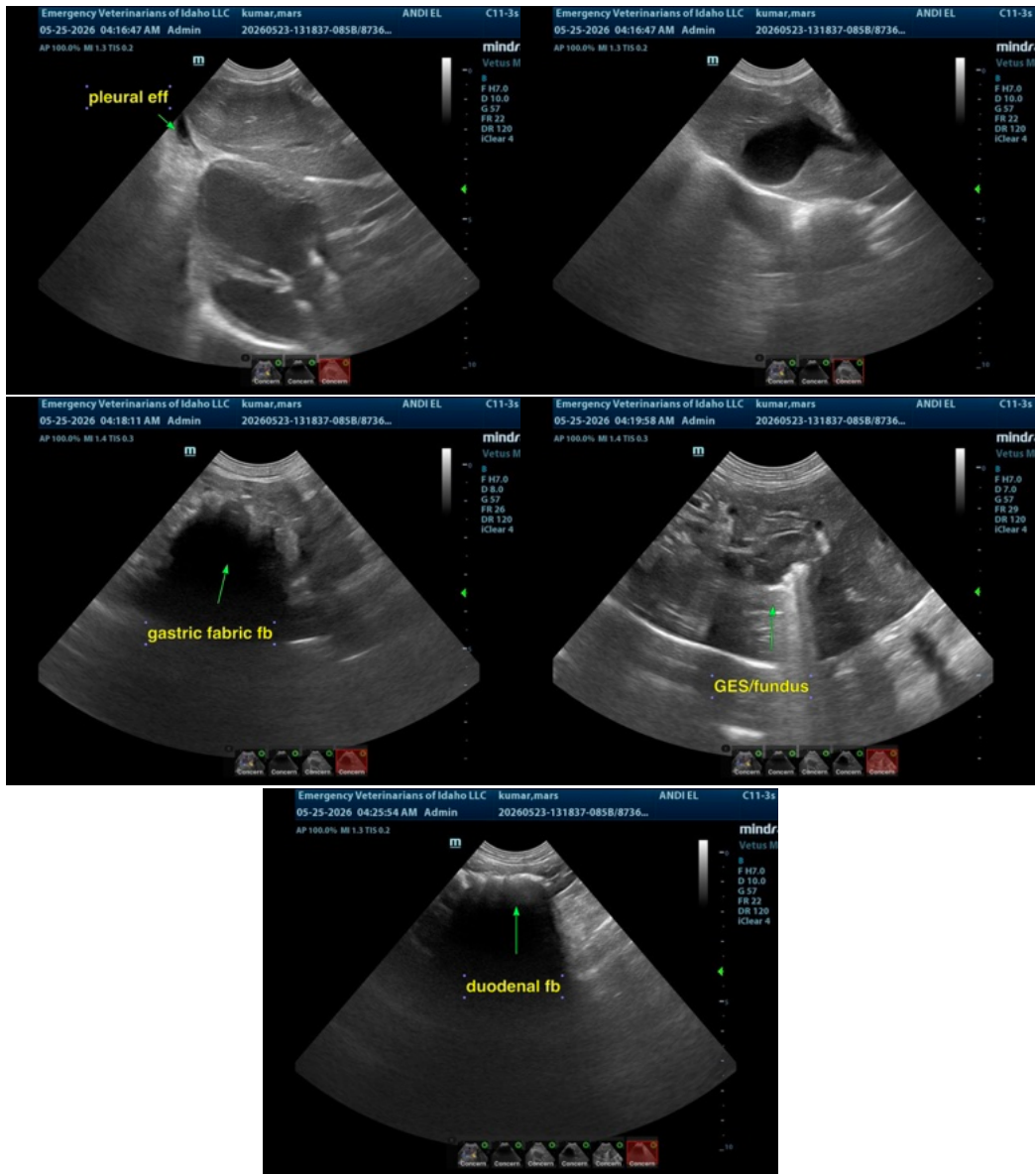
Dr. Sorenson

INVOICE

77906

DATE

5/24/26



The information and recommendations provided are based on the images presented by the referring veterinarian/sonographer. No evaluation can be communicated regarding pathology that was not visible in the image/video clips provided.

Thank you for this referral. If the clinical or image interpretation does not parallel your findings or if I can be of any further assistance please contact me.

Eric Lindquist, DMV, DABVP (CFM), Cert. IVUSS, CEO of SonoPath.com

info@SonoPath.com