

PATIENT

Clifford Rodriguez

SPECIES

Canine

BREED

Dachshund

SEX

MN

AGE

11 yr

WEIGHT

12.1 lb

INTERPRETED BY

Eric Lindquist, DMV
DABVP, Cert. IVUSS

IMAGING PERFORMED BY

Kelly Vazquez

HOSPITAL NAME

Animal General on
Hudson

REFERRING VET

Dr. Vivian Ng

INVOICE

10670ag

DATE

05/25/2022

PRESENTING CLINICAL SIGNS

History: History of severe diarrhea in April 2022, resolved with Tylan. TLI high 46.4 on G.I. profile 5/2022. No reported meds.

Abnormal PE/Chem/CBC/UA Results: 4/2022: phos 1.8, lymphs low, TLI 46.4.

ULTRASONOGRAPHIC EXAMINATION OF THE ABDOMEN

Urinary System

The urinary bladder, trigone, and pelvic urethra presented normal thicknesses and normal tone. The ureters were not visible which is normal. No uroliths or sediment were visualized and anechoic urine was present. No evidence of inflammatory or neoplastic changes were noted. Ureteral papillae were normal.

The kidneys revealed normal size and structure, corticomedullary definition and ratio for this age. The cortices presented largely uniform texture with normal echogenic relationship to liver and spleen. Medullary structure differed distinctly from the cortex and no evidence of pelvic dilation was present. The capsules were acceptably uniform without significant irregularities. The left kidney measured 3.15 cm in length. The right kidney measured 3.79 cm in length.

The residual prostate was slightly heterogeneous measuring up to 1 cm in width.

Adrenal Glands

Both adrenal glands were visualized and recognized as having normal shape, size, position and echogenicity for this breed. The phrenic vasculature, glandular echogenicity and detail were unremarkable. Capsule, cortex, and medullary definition were normal for this age patient. The left adrenal gland measured 1.39 cm in length by 0.53 cm caudal pole width by 0.5 cm cranial pole width. The right adrenal gland measured 0.96 cm in length by 0.26 cm caudal pole width by 0.32 cm cranial pole width.

Spleen

The spleen presented a smooth homogeneous parenchyma hyperechoic to liver and renal cortical parenchyma. The capsule was smooth without noticeable expansion or deviation from within the spleen or adjacent pathology. The splenic vasculature demonstrated normal volume without signs of congestion or thrombosis. No sonographic evidence of acute or chronic inflammatory, neoplastic, or infarctual changes were noted.

Liver

The liver images from right and left intercostal as well as subcostal views revealed subjectively normal liver size, contour, and structure. Some mild age-related parenchymal remodeling was noted but likely not clinically significant at this time. Vascular and biliary tracts were of normal volume and no evidence of congestion was noted.

The gallbladder presented some dependent debris with essentially normal contour. The cystic and common bile ducts were normal. No overt evidence of active inflammatory, infiltrative or regenerative pathology was noted but should be paired with current or past LE elevations regarding any clinical significance to this presentation. The hepatic lymph nodes were unremarkable.



PATIENT

Clifford Rodriguez

SPECIES

Canine

BREED

Dachshund

SEX

MN

AGE

11 yr

WEIGHT

12.1 lb

INTERPRETED BY

Eric Lindquist, DMV
DABVP, Cert. IVUSS

IMAGING PERFORMED BY

Kelly Vazquez

HOSPITAL NAME

Animal General on
Hudson

REFERRING VET

Dr. Vivian Ng

INVOICE

10670ag

DATE

05/25/2022

Gastrointestinal

Examination of the gastrointestinal tract revealed a stomach and intestine free of stasis, of normal wall thickness, acceptable curvilinear mural detail, and peristaltic activity. Small and large intestine demonstrated normal luminal chyme and stool consistency respectively. No obstructive or overt infiltrative disease was noted. No associated abnormal lymphatic activity was noted.

Pancreas

The base and limbs of the pancreas were observed to be largely isoechoic to surrounding omental fat. Some mild parenchymal remodeling, however, with mild deviation from curvilinear normalcy was observed. Pancreatic duct and capsular irregularities were present consistent with age related changes. If pain upon imaging (+ Murphy sign) was present or if the patient is focally painful in subxiphoid palpation then low-grade smoldering chronic pancreatitis should be suspected.

ULTRASONOGRAPHIC FINDINGS

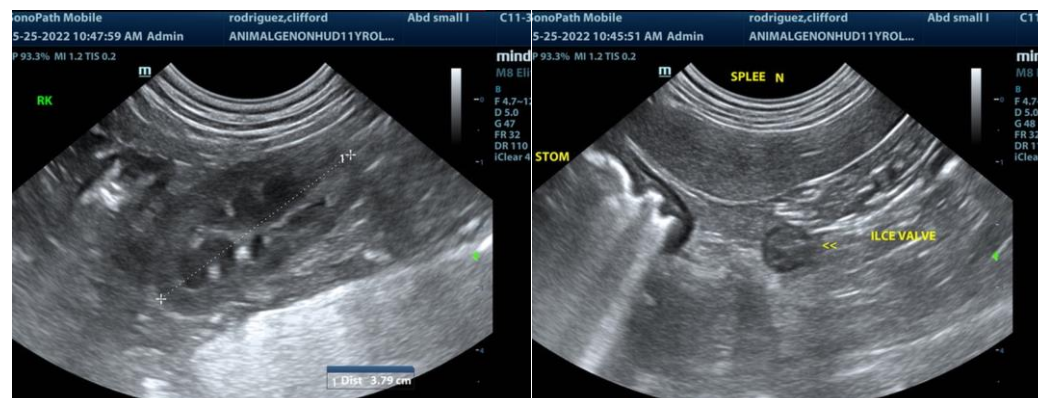
- Unremarkable abdomen, no evidence of specific changes/disease

INTERPRETATION OF THE FINDINGS & FURTHER RECOMMENDATIONS

Pancreatic supplementation and diet change to hydrolyzed geriatric diet may prove beneficial. Internal medicine consult may be considered.

For an additional charge, internal medicine consult can be utilized through SonoPath.com. You can select the internal medicine drop down at <http://spa.sonopath.com/>.

One of the world's top internists & SonoPath associate Dr. Remo Lobetti BVSc, MMedVet, PhD, DECVIM can evaluate your case through SonoPath. <https://sonopath.com/resources/sonopath-services/internal-medicine-teleconsultation-services>





PATIENT

Clifford Rodriguez

SPECIES

Canine

BREED

Dachshund

SEX

MN

AGE

11 yr

WEIGHT

12.1 lb

INTERPRETED BY

Eric Lindquist, DMV
DABVP, Cert. IVUSS

IMAGING PERFORMED BY

Kelly Vazquez

HOSPITAL NAME

Animal General on
Hudson

REFERRING VET

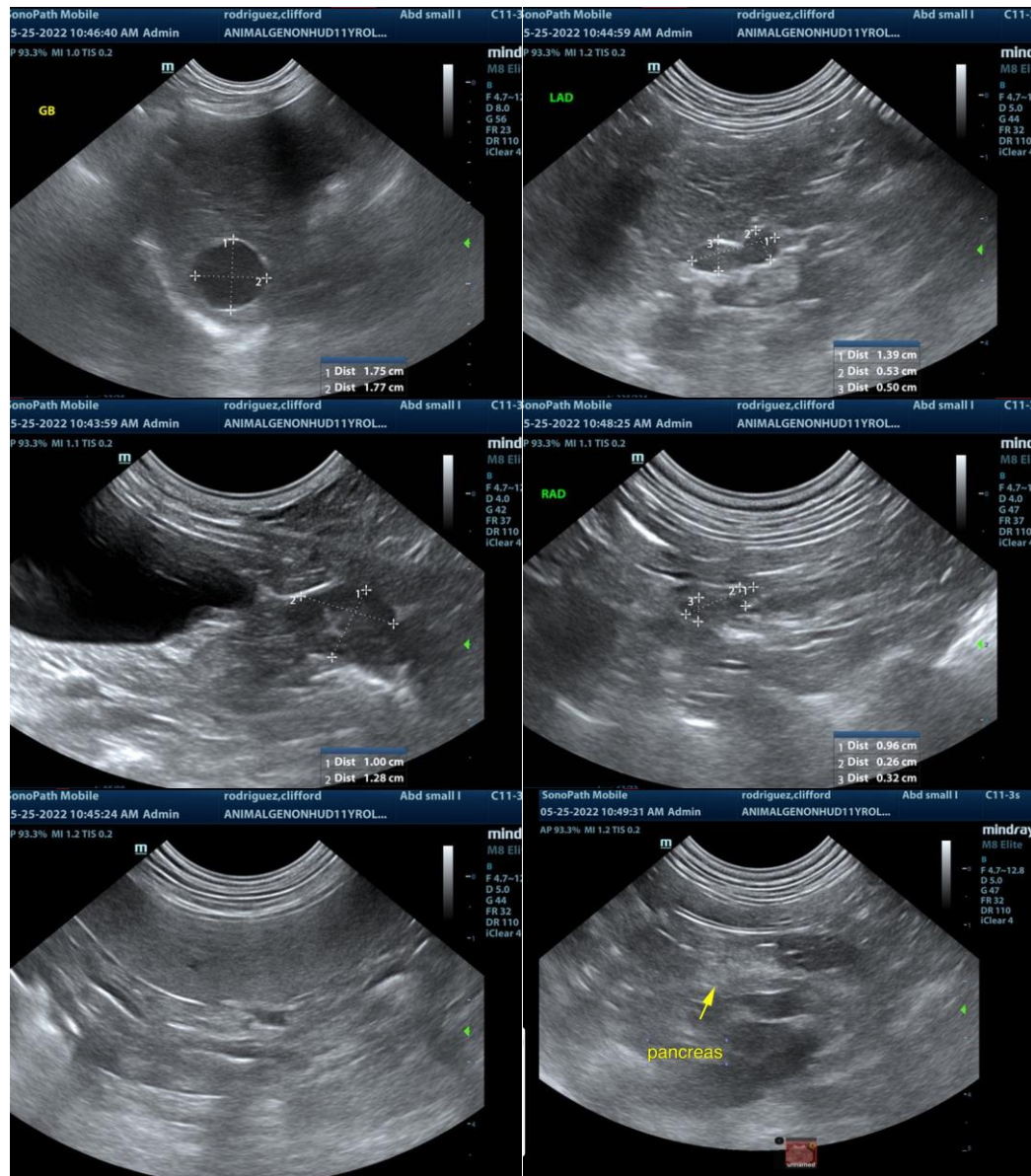
Dr. Vivian Ng

INVOICE

10670ag

DATE

05/25/2022



The information and recommendations provided are based on the images presented by the referring veterinarian. No evaluation can be communicated regarding pathology that was not visible in the image/video clips provided.

Thank you for this referral. If the clinical or image interpretation does not parallel your findings or if I can be of any further assistance please contact me.

Eric Lindquist, DMV, DABVP, Cert. IVUSS, CEO of SonoPath.com
Eric.Lindquist@SonoPath.com