



PATIENT PRESENTING CLINICAL SIGNS

PATIENT Ziggy Cohen
SPECIES Canine
BREED Golden
SEX Neutered male
AGE 12 years
WEIGHT 87.6 lbs

History: was in emergency room last 24 hours-- cc : discomfort , panting, severe lethargy owner brought pet here for second opinion pet is very weak, panting, crt wnl, pink gum, no heart murmur no wt loss normal temp bp=140 pulse ox 92/3 % chest rads and echo done no fluids seen around heart possible tumor seen ? pending results abdominal sonogram done - no obvious tumor seen ,no hemoabdomen observed , pending results . bw done at emergency room wnl hct dropped overnight while on iv fluids from 33 to 28 all else wnl

ULTRASONOGRAPHIC EXAMINATION OF THE ABDOMEN

Urinary System

The **urinary bladder**, trigone, and pelvic urethra presented normal thicknesses and normal tone. The ureters were not visible which is normal. No uroliths or sediment were visualized and anechoic urine was present. No evidence of inflammatory or neoplastic changes was noted. Ureteral papillae were normal.

The **kidneys** revealed largely normal size and structure, corticomedullary definition and ratio (cortex 1/3 of medulla) were essentially maintained with some age-related loss of curvilinear patterns regarding the capsule and C/M junction. The cortices presented largely uniform texture with some increased echogenicity expected for this age patient. Medullary structure differed distinctly from that of the cortex and no evidence of pelvic dilation was present. The left kidney measured 6.77 cm. The right kidney measured 7.37 cm.

Adrenal Glands

Both **adrenal glands** were visualized and recognized as having normal shape, size, position and echogenicity for this breed. The phrenic vasculature, glandular echogenicity and detail were unremarkable. Capsule, cortex, and medullary definition were normal for this age patient. The left adrenal gland measured 0.5 cm. The right adrenal gland measured 0.7 cm and was visualized obliquely.

Spleen

The **spleen** presented a smooth homogeneous parenchyma hyperechoic to liver and renal cortical parenchyma. The capsule was smooth without noticeable expansion or deviation from within the spleen or adjacent pathology. The splenic vasculature demonstrated normal volume without signs of congestion or thrombosis. No sonographic evidence of acute or chronic inflammatory, neoplastic, or infarctual changes was noted.

Liver

The **liver** images from right and left intercostal as well as subcostal views revealed subjectively normal liver size, contour, and structure. Some age-related parenchymal remodeling was noted but likely not clinically significant at this time. Vascular and biliary tracts were of normal volume and no evidence of congestion was noted. The gallbladder presented some dependent debris with essentially normal contour. The cystic and common bile ducts were normal. No overt evidence of active inflammatory,

INTERPRETED BY

Eric Lindquist, DMV
DABVP, Cert. IVUSS

IMAGING PERFORMED BY

Dr. Barnea

HOSPITAL NAME

Tenaflly VC

REFERRING VET

Dr. Barnea

INVOICE

30666

DATE

5/23/22



PATIENT

infiltrative or regenerative pathology was noted but should be paired with current or past LE elevations regarding any clinical significance to this presentation. The hepatic lymph nodes were unremarkable.

Ziggy Cohen

SPECIES

Gastrointestinal

Canine

Examination of the **gastrointestinal tract** revealed a stomach and intestine free of stasis, of normal wall thickness, acceptable curvilinear mural detail, and peristaltic activity. Small and large intestine demonstrated normal luminal chyme and stool consistency respectively. No obstructive or overt infiltrative disease was noted. No associated abnormal lymphatic activity was noted.

BREED

Golden

SEX

Pancreas

Neutered male

The base and limbs of the **pancreas** were observed to be largely isoechoic to surrounding omental fat. Pancreatic duct and capsular contour were acceptably normal and parenchyma respected normal curvilinear patterns. No overt evidence of active inflammatory or neoplastic disease was noted.

AGE

12 years

ULTRASONOGRAPHIC FINDINGS

Normal geriatric abdomen.

WEIGHT

87.6 lbs

INTERPRETATION OF THE FINDINGS & FURTHER RECOMMENDATIONS

There was no evidence of pathology related to the clinical signs. The changes are expected for this age and breed.

INTERPRETED BY

Eric Lindquist, DMV
DABVP, Cert. IVUSS

IMAGING PERFORMED BY

Dr. Barnea

HOSPITAL NAME

Tenaflly VC

REFERRING VET

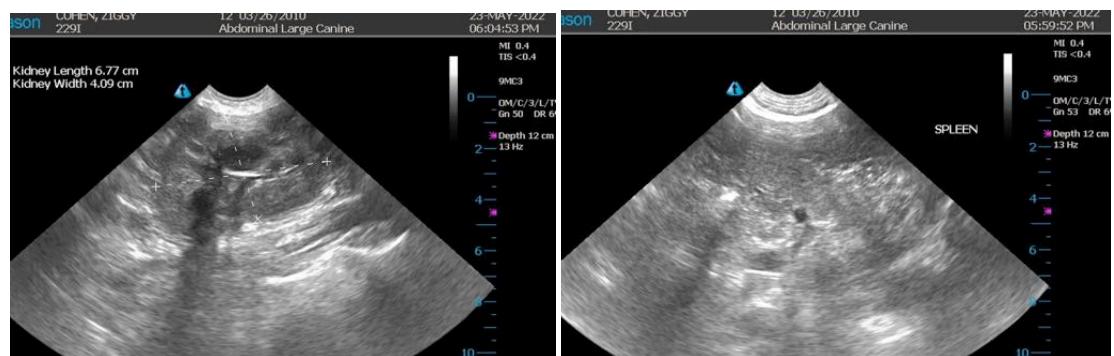
Dr. Barnea

INVOICE

30666

DATE

5/23/22





PATIENT

Ziggy Cohen

SPECIES

Canine

BREED

Golden

SEX

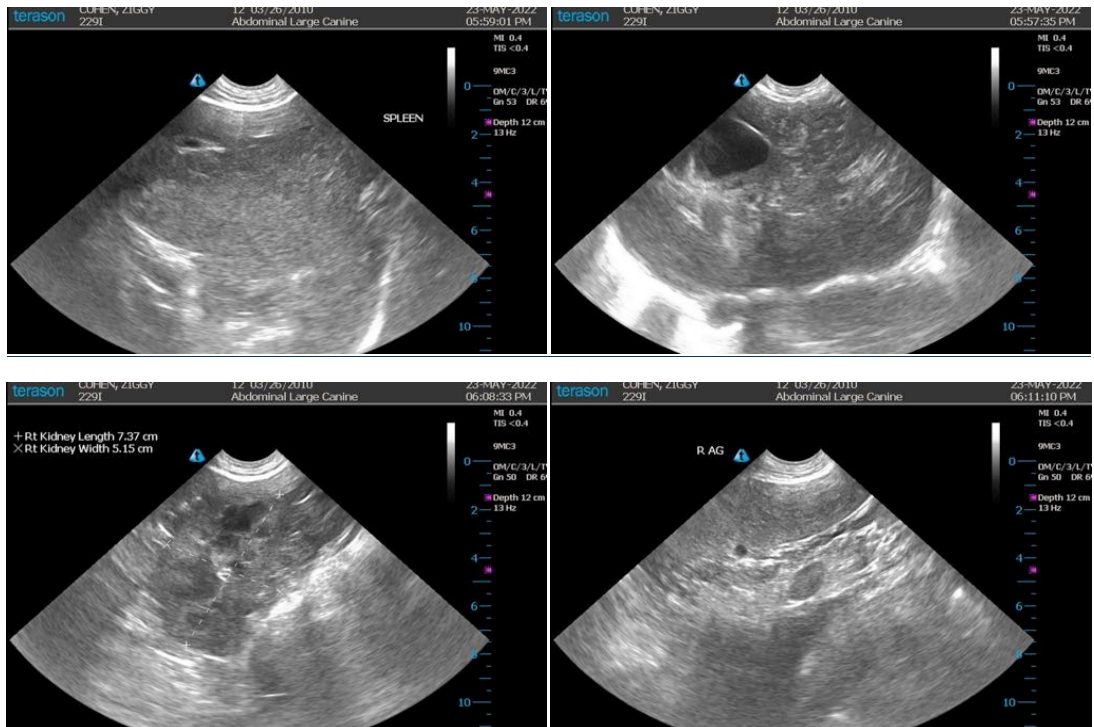
Neutered male

AGE

12 years

WEIGHT

87.6 lbs



INTERPRETED BY

Eric Lindquist, DMV
DABVP, Cert. IVUSS

IMAGING PERFORMED BY

Dr. Barnea

HOSPITAL NAME

Tenaflly VC

REFERRING VET

Dr. Barnea

INVOICE

30666

DATE

5/23/22

The information and recommendations provided are based on the images presented by the referring veterinarian/sonographer. No evaluation can be communicated regarding pathology that was not visible in the image/video clips provided.

Thank you for this referral. If the clinical or image interpretation does not parallel your findings or if I can be of any further assistance please contact me.

Eric Lindquist, DMV, DABVP, Cert. IVUSS, CEO of SonoPath.com
info@SonoPath.com