



PATIENT

Velasco Chester

PRESENTING CLINICAL SIGNS

History: Follow-up echo from 9/22/21. Currently on 2.5mg felimazole T4 1.9

SPECIES

Feline

ULTRASONOGRAPHIC EXAMINATION OF THE HEART

BREED

Domestic Longhair

The echocardiogram in this patient demonstrated normal **left atrial** size based on 3 separate LA measurements. Minor **mitral** valve insufficiency was noted at 5.5 m/sec, yet compensated. Concentric **left ventricular** hypertrophy noted with myocardial remodeling. The **myocardium** presented normal echogenicity without subjective evidence of significant fibrotic or ischemic disease. **Contractility** of the ventricular walls was adequate and in normal range for this patient evidenced by the fractional shortening measurement and subjective evaluation of the different regions and angles of the myocardium. Septal impingement on the **left ventricular outflow** tract was noted. However, there was no systolic anterior motion noted at the time of the sonogram. The **right atrium** and auricle revealed normal size, structure and content. No evidence of masses was noted or chamber overload. **Tricuspid** valvular assessment demonstrated adequate linear morphology and kinetics. The **right ventricle** was of normal size (1/3 diameter of LV), chordae structure, myocardial echogenicity and thickness. **Pulmonic** tract assessment revealed normal valve structure, laminar flow, and diameter (approx.1:1 pa/ao ratio). No visible **pericardial** or free pleura fluid was noted or extra cardiac pathology in the visible planes. The cranial **mediastinum** and **pericardial** regions were free of masses in the visible window.

SEX

Neutered male

AGE

4 years

WEIGHT

14 lbs

INTERPRETED BY

Eric Lindquist, DMV
DABVP, Cert. IVUSS

IMAGING PERFORMED BY

Dr. Rodriguez

HOSPITAL NAME

Foxfield VS

REFERRING VET

Dr. Rodriguez

FELINE CARDIAC PARAMETERS	BODY WEIGHT (kg)	HR (BPM)	IVSd (cm)	LVIDd (cm)	LVWd (cm)	FS (%)	EF (%)
NORMAL PARAMETER	-----	150-240	0.3-0.6	1.0-2.1	0.25-0.6	35-67	80-100
PATIENT		NM	0.99	1.38	0.83	50	90
FELINE CARDIAC PARAMETERS	LA/AO (Boon)	LA/AO HEART BASE (Sisson)	LA 2D 4-chamber long axis AS to FW (Sisson) (cm)	LVOT VEL. (m/s)	RVOT VEL. (m/s)	IVRT (m/)	
NORMAL PARAMETER	<1.5	0.88-1.79	0.7-1.7	<1.6	<1.3	40-60	
PATIENT	1.1	1.48	1.4 max	1.5	1.1	NM	
Adapted from June Boon, Veterinary Echocardiography, 1998 Sisson D et al. JVIM 1991; 5: 232, Jacobs et al. Am J Vet Res 1985; 46:1705							

INVOICE

30654

DATE

5/23/22

ULTRASONOGRAPHIC FINDINGS

Compensated hypertrophic cardiomyopathy.

No volume overload.



PATIENT

Velasco Chester

SPECIES

Feline

BREED

Domestic Longhair

SEX

Neutered male

AGE

4 years

WEIGHT

14 lbs

INTERPRETED BY

Eric Lindquist, DMV
DABVP, Cert. IVUSS

IMAGING PERFORMED BY

Dr. Rodriguez

HOSPITAL NAME

Foxfield VS

REFERRING VET

Dr. Rodriguez

INVOICE

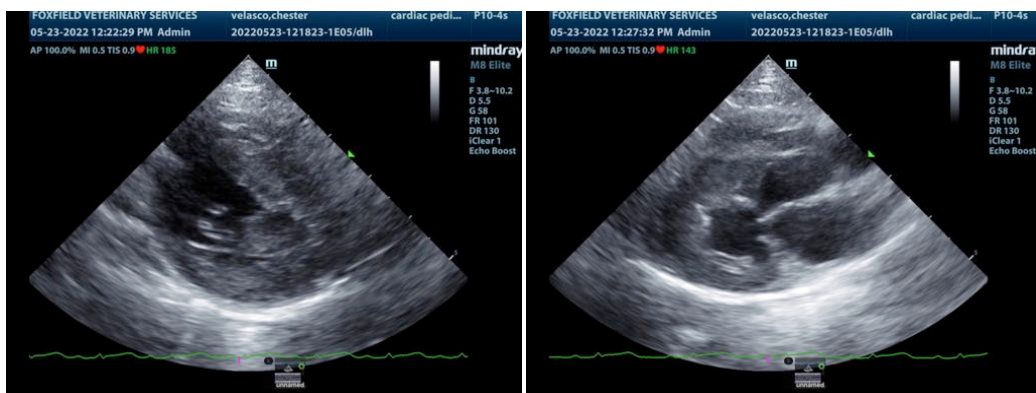
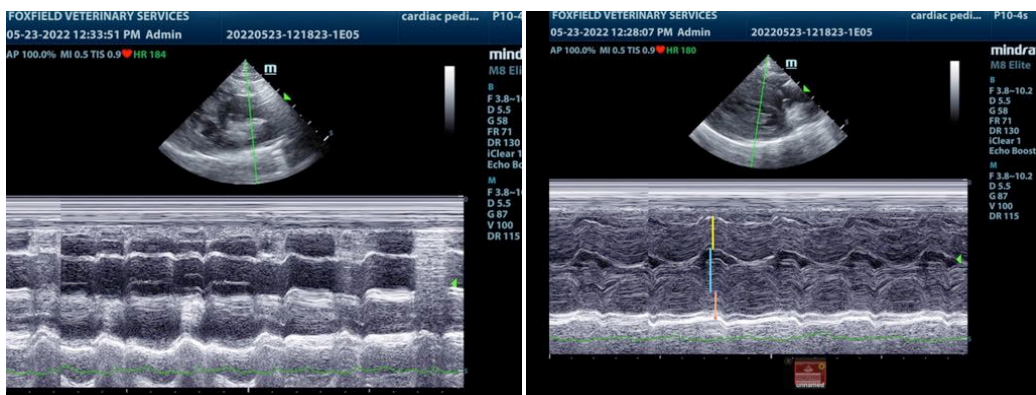
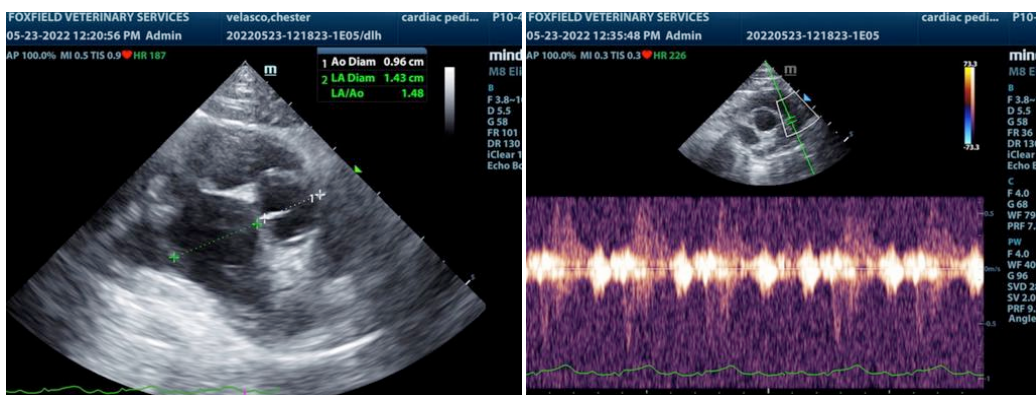
30654

DATE

5/23/22

INTERPRETATION OF THE FINDINGS & FURTHER RECOMMENDATIONS

If no clinical signs are present then no specific treatment is recommended at this time. Recheck echocardiogram is recommended in 6 months.





PATIENT

Velasco Chester

SPECIES

Feline

BREED

Domestic Longhair

SEX

Neutered male

AGE

4 years

WEIGHT

14 lbs

INTERPRETED BY

Eric Lindquist, DMV
DABVP, Cert. IVUSS

**IMAGING
PERFORMED BY**

Dr. Rodriguez

HOSPITAL NAME

Foxfield VS

REFERRING VET

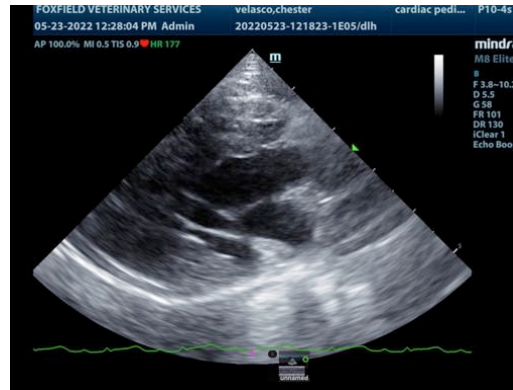
Dr. Rodriguez

INVOICE

30654

DATE

5/23/22



The information and recommendations provided are based on the images presented by the referring veterinarian/sonographer. No evaluation can be communicated regarding pathology that was not visible in the image/video clips provided.

Thank you for this referral. If the clinical or image interpretation does not parallel your findings or if I can be of any further assistance please contact me.

Eric Lindquist, DMV, DABVP, Cert. IVUSS, CEO of SonoPath.com
info@SonoPath.com