

**DATE**

5/23/22

PRESENTING CLINICAL SIGNS

CC- Cough, started past weekend, progressed to all day coughing, lethargy, not eating 5/17/22; O was diagnosed with COVID 5/11/22

PATIENT

Ralphie Lundin

PE- Heart WNL, chest- not harsh; +cough on exertion; no weight loss

T- 101.3, HR- 120; RR- ~40. Meds: Optimune OU SID- BID

Diet- Some k/d + chicken, treats.

Current Medications: Optimune OU SID- BID, Sentinel monthly

Radiographs: Metastatic lung dz (Viewed by radiologist/Synergy)

Date of Previous IntraPet Ultrasound: 2/4/21. See attached.

SPECIES

Canine

Sedation: Not required to complete full diagnostic ultrasound.

Stat Report: Not requested.

Imaging Performed By: Rachel Brillhart, RDMS.

BREED

Shih Tzu

ULTRASONOGRAPHIC EXAMINATION OF THE ABDOMEN**Urinary System**

The **urinary bladder**, trigone, and pelvic urethra presented normal thicknesses and normal tone. The ureters were not visible which is normal. No uroliths or sediment were visualized and anechoic urine was present. No evidence of inflammatory or neoplastic changes was noted. Ureteral papillae were normal.

AGE

2/14/10

The **kidneys** revealed largely normal size and structure, corticomedullary definition and ratio (cortex 1/3 of medulla) were essentially maintained with some age-related loss of curvilinear patterns regarding the capsule and C/M junction. The cortices presented largely uniform texture with some increased echogenicity expected for this age patient. Medullary structure differed distinctly from that of the cortex. The right kidney measured 4.48 cm with slight pyelectasia that measured 0.46 cm. The left kidney measured 4.3 cm with pyelectasia that measured 0.3 cm.

WEIGHT

19 lbs

INTERPRETED BYEric Lindquist, DMV
DABVP, Cert. IVUSS**Adrenal Glands**

Both **adrenal glands** were visualized and recognized as having normal shape, size, position and echogenicity for this breed. The phrenic vasculature, glandular echogenicity and detail were unremarkable. Capsule, cortex, and medullary definition were normal for this age patient. The right adrenal gland measured 2.1 x 0.6 cm at the cranial pole and 0.46 cm at the caudal pole. The left adrenal gland measured 1.7 x 0.63 cm at the caudal pole and 0.53 cm at the cranial pole.

HOSPITAL NAME

Essex Middle River VC

Spleen

The **spleen** revealed splenic nodules, similar to the prior sonogram. Minor progressive remodeling was noted measuring up to 1.72 cm and 1.62 cm.

REFERRING VET

Dr. Hicks

Liver

The **liver** images from right and left intercostal as well as subcostal views revealed subjectively normal liver size, contour, and structure. Some age-related parenchymal remodeling was noted but likely not clinically significant at this time. Vascular and biliary tracts were of normal volume and no evidence of congestion was noted. The gallbladder presented some dependent debris with essentially normal contour. The cystic and common bile ducts were normal. No overt evidence of active inflammatory, infiltrative or regenerative pathology was noted but should be paired with current or past LE elevations regarding any clinical significance to this presentation. The hepatic lymph nodes were unremarkable. Transdiaphragmatic view revealed hypoechoic lung nodule measuring 1.46 cm.

INVOICE

30660

Gastrointestinal

Examination of the **gastrointestinal tract** revealed a stomach and intestine free of stasis, of normal wall thickness, acceptable curvilinear mural detail, and peristaltic activity. Small and large intestine demonstrated normal luminal chyme and stool consistency respectively. No obstructive or overt infiltrative disease was noted. No associated abnormal lymphatic activity was noted.

Pancreas

The base and limbs of the **pancreas** were observed to be largely isoechoic to surrounding omental fat. Pancreatic duct and capsular contour were acceptably normal and parenchyma respected normal curvilinear patterns. No overt evidence of active inflammatory or neoplastic disease was noted.

Thorax

The thorax revealed hypoechoic, nodular changes that measured up to 0.9 cm and up to 1.2 cm. This is strongly suggestive for metastatic lesions. Rapid view of the heart revealed no evidence of pathology.

ULTRASONOGRAPHIC FINDINGS

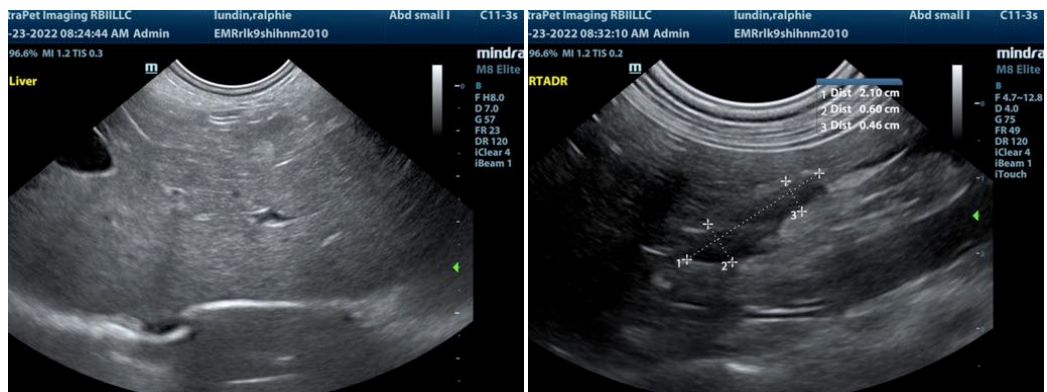
Multi-focal lung nodules. Neoplasia versus granulomas.

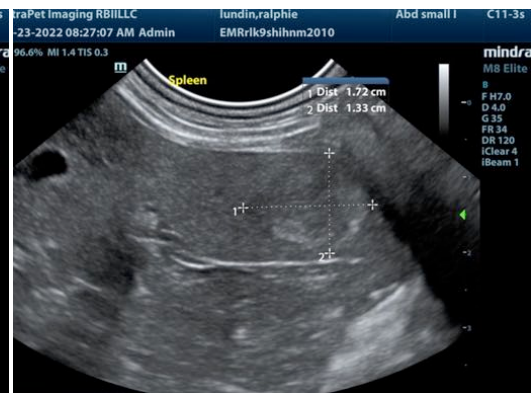
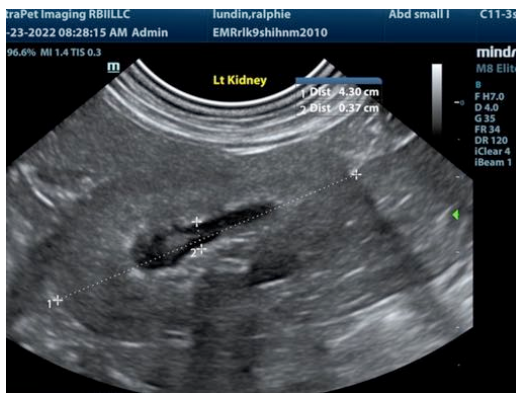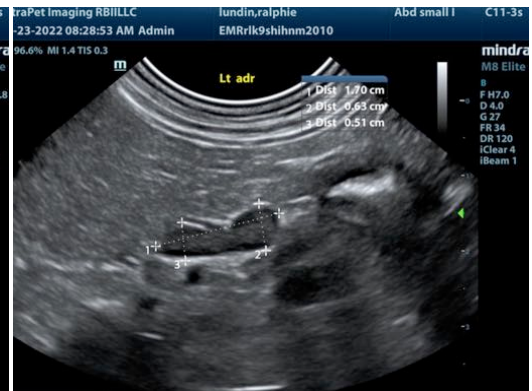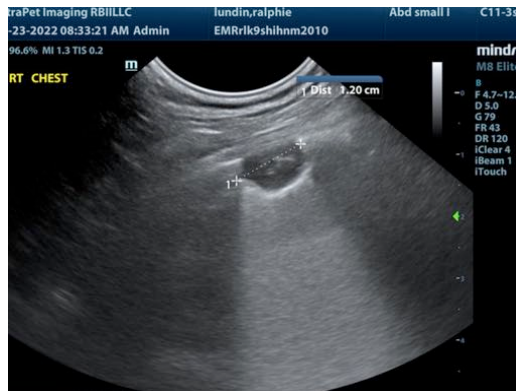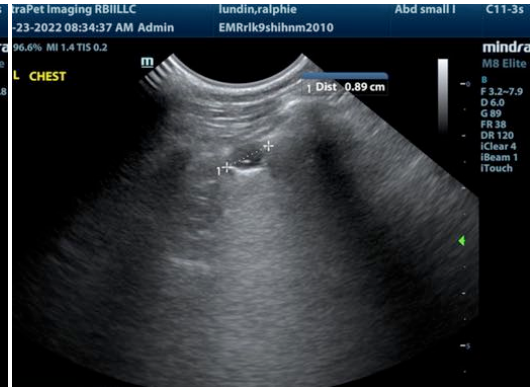
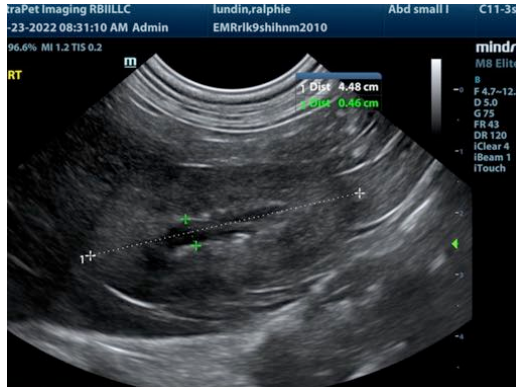
Mild to moderate chronic renal changes.

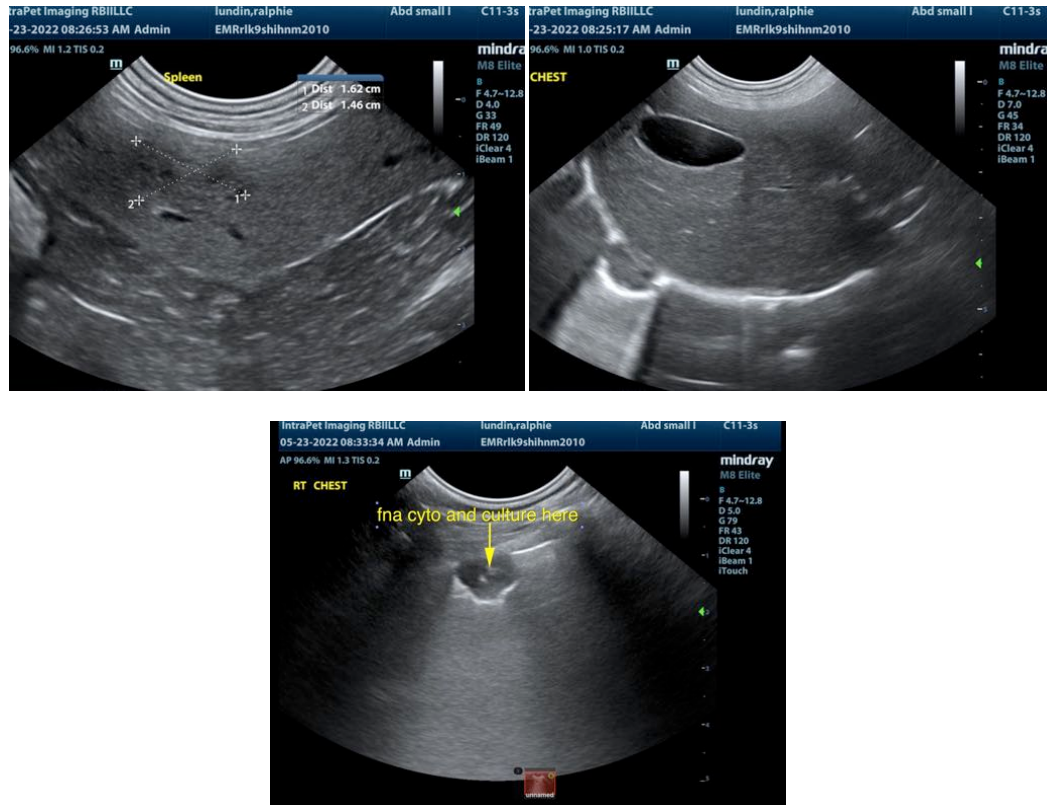
Splenic nodules. Nodular hyperplasia is likely the cause of the splenic presentation. However, conversion to a neoplastic event cannot be ruled out. Hypoechoic nodular changes in the thorax.

INTERPRETATION OF THE FINDINGS & FURTHER RECOMMENDATIONS

FNA of the lung nodules and splenic nodules are recommended. Chest CT would be ideal to assess distribution of the lesions. I recommend focusing further diagnostic work-up on the thorax.







The information and recommendations provided are based on the images presented by the referring veterinarian. No evaluation can be communicated regarding pathology that was not visible in the image/video clips provided.

Thank you for this referral. If the clinical or image interpretation does not parallel your findings or if I can be of any further assistance please contact me.

Eric Lindquist, DMV, DABVP, Cert. IVUSS, CEO of SonoPath.com
 Eric.Lindquist@SonoPath.com