**DATE**

5/23/22

PRESENTING CLINICAL SIGNS

Pt presents for slowing down more in the past couple months, pt also has been urinating in the house about every other day. Pt sometimes has energy then tail will go down and seems uncomfortable.

Current Medications: Galliprant 50mg SID started 5/17/2022

Dasuquin.

Lab Results: ALP 418 3/2022. Was 187 1 yr before in 4/2021

Date of Previous IntraPet Ultrasound: No previous.

Sedation: Not required to complete full diagnostic ultrasound.

Stat Report: Not requested.

Imaging Performed By: Rachel Brillhart, RDMS.

PATIENT

Gaz Fraser

SPECIES

Canine

BREED

Hound Mix

SEX

Neutered male

AGE

6/20/2011

WEIGHT

56.2 lbs

INTERPRETED BY

Eric Lindquist, DMV
DABVP, Cert. IVUSS

HOSPITAL NAME

Everhart VH WellPet

REFERRING VET

Dr. Rubinstein

INVOICE

30662

ULTRASONOGRAPHIC EXAMINATION OF THE ABDOMEN**Urinary System**

The **urinary bladder**, trigone, and pelvic urethra presented normal thicknesses and normal tone. The ureters were not visible which is normal. No uroliths or sediment were visualized and anechoic urine was present. No evidence of inflammatory or neoplastic changes was noted. Ureteral papillae were normal.

The **kidneys** revealed normal size and structure, corticomedullary definition and ratio for this age. The cortices presented largely uniform texture with normal echogenic relationship to liver and spleen. Medullary structure differed distinctly from the cortex and no evidence of pelvic dilation was present. The capsules were acceptably uniform without significant irregularities. The right kidney measured 7.69 cm. The left kidney measured 6.66 cm.

Adrenal Glands

The right **adrenal gland** was uniform and measured 2.54 x 0.71 cm at the caudal pole and 0.6 cm at the cranial pole. The left adrenal gland was at the upper limits of normal to slightly enlarged and measured 2.55 x 0.89 cm at the caudal pole and 0.79 cm at the cranial pole.

Spleen

The **spleen** presented a smooth homogeneous parenchyma hyperechoic to liver and renal cortical parenchyma. The capsule was smooth without noticeable expansion or deviation from within the spleen or adjacent pathology. The splenic vasculature demonstrated normal volume without signs of congestion or thrombosis. No sonographic evidence of acute or chronic inflammatory, neoplastic, or infarctual changes was noted.

Liver

The **liver** images submitted revealed subjectively normal liver size, contour, and structure. Pinpoint mineralization was noted in the liver. Parenchymal echogenicity was naturally coarse and hypoechoic to the spleen. Vascular and biliary tracts were of normal volume with no evidence of congestion. The gallbladder was mildly over distended with suspended and dependent debris, yet not to the level of emerging mucocele. However, the sludge appears to be mildly excessive. No adjunctive inflammation was noted.

Gastrointestinal

Examination of the **gastrointestinal tract** revealed a stomach and intestine free of stasis, of normal wall thickness, acceptable curvilinear mural detail, and peristaltic activity. Small and large intestine demonstrated normal luminal chyme and stool consistency respectively. No obstructive or overt infiltrative disease was noted. No associated abnormal lymphatic activity was noted.

Pancreas

The base and limbs of the **pancreas** were observed to be largely isoechoic to surrounding omental fat. Pancreatic duct and capsular contour were acceptably normal and parenchyma respected normal curvilinear patterns. No overt evidence of active inflammatory or neoplastic disease was noted.

ULTRASONOGRAPHIC FINDINGS

Benign hepatopathy.

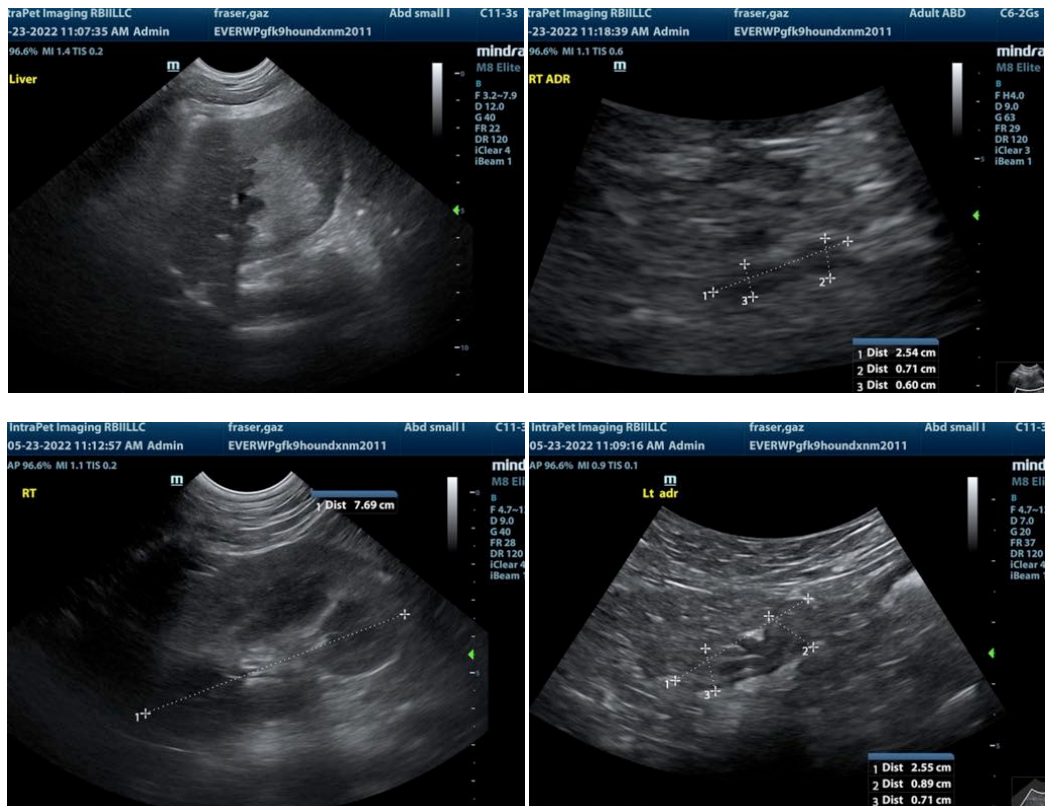
Minor age related changes.

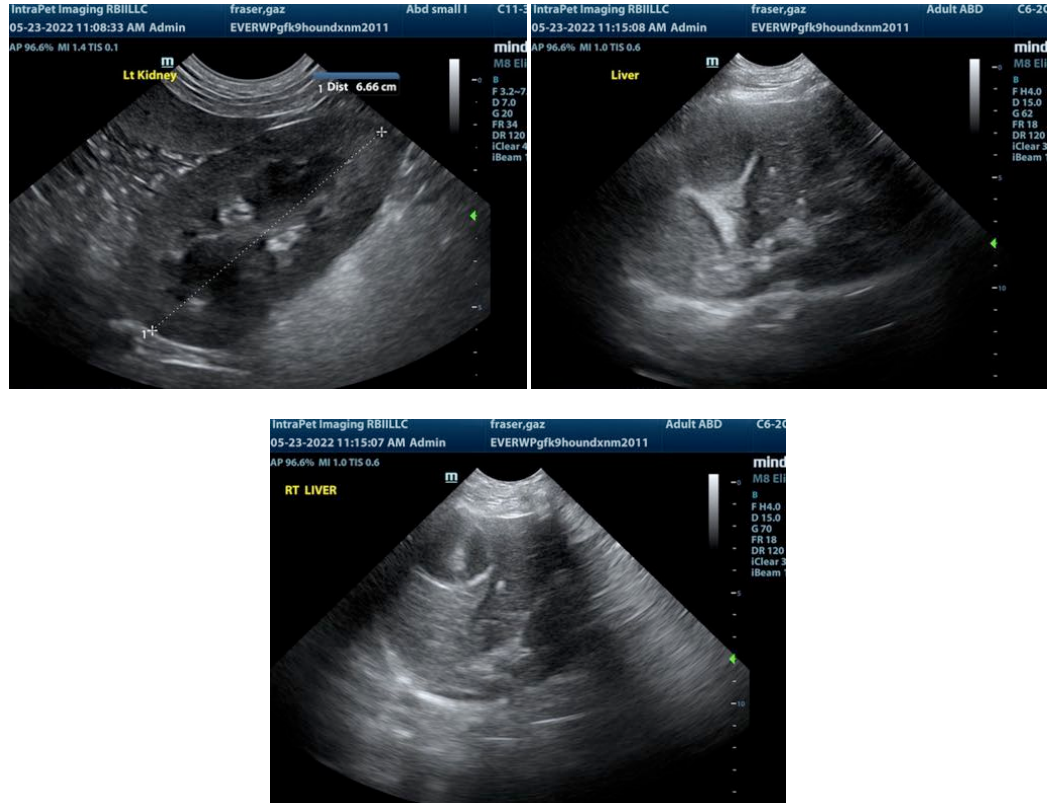
Minor excessive gallbladder debris.

Normal right adrenal gland and upper limits of normal to slightly enlarged left adrenal gland. Potential emerging PDH.

INTERPRETATION OF THE FINDINGS & FURTHER RECOMMENDATIONS

Given that the urine specific gravity is well concentrated typical Cushing's is unlikely. Ursodiol therapy is warranted as a preventative. If the urine specific gravity drops less than 1.020 then work-up for PDH is indicated if the patient appears Cushingoid.





The information and recommendations provided are based on the images presented by the referring veterinarian. No evaluation can be communicated regarding pathology that was not visible in the image/video clips provided.

Thank you for this referral. If the clinical or image interpretation does not parallel your findings or if I can be of any further assistance please contact me.

Eric Lindquist, DMV, DABVP, Cert. IVUSS, CEO of SonoPath.com
Eric.Lindquist@SonoPath.com