



PATIENT

Theodore Morse

SPECIES

Canine

BREED

Pug

SEX

Neutered Male

AGE

10 Years 3 Months

WEIGHT

21.8 lbs

INTERPRETED BY

Eric Lindquist, DMV,
DABVP(CFM), Cert.
IVUSS

IMAGING PERFORMED BY

Brittney Beigel, DVM

HOSPITAL NAME

Bayside Animal
Medical Center

REFERRING VET

Katie Buchanan, VMD

INVOICE

16487

DATE

05/22/26

PRESENTING CLINICAL SIGNS

Hx of recent worsening seizures (hx of seizures as a young dog but hadn't had any in years). Recently started on thyroid medication, slightly over corrected thyroid on BW today, will lower dose to half 0.1mg tablet BID. Recently drinking a lot and lethargic, no energy. Not eating well. No sedation needed. Concern for insulinoma vs other

ULTRASONOGRAPHIC EXAMINATION OF THE ABDOMEN

Urinary System

The **urinary bladder**, trigone, and pelvic urethra to a depth of 1.0 cm presented normal thicknesses and normal tone. The ureters were not visible which is normal. No uroliths or sediment were visualized, and anechoic urine was present. No evidence of inflammatory or neoplastic changes were noted. Ureteral papillae were normal.

The **kidneys** revealed normal size and structure, corticomedullary definition and ratio for this age. The cortices presented largely uniform texture with normal echogenic relationship to liver and spleen. Medullary structure differed distinctly from the cortex and no evidence of pelvic dilation was present. The capsules were acceptably uniform without significant irregularities. The left kidney measured 4.5 cm in length. The right kidney measured 4.9 cm in length.

Adrenal Glands

Both **adrenal glands** were visualized and recognized as having normal shape, size, position and echogenicity for this breed. The phrenic vasculature, glandular echogenicity and detail were unremarkable. Capsule, cortex, and medullary definition were normal for this age patient. The right adrenal gland measured 0.72 cm width at the cranial pole and 0.39 cm width at the caudal pole.

Spleen

The **spleen** presented a smooth homogeneous parenchyma hyperechoic to liver and renal cortical parenchyma. The capsule was smooth without noticeable expansion or deviation from within the spleen or adjacent pathology. The splenic vasculature demonstrated normal volume without signs of congestion or thrombosis. No sonographic evidence of acute or chronic inflammatory, neoplastic, or infarctual changes were noted. The spleen was folded upon itself cranially (positional variant).

Liver

The **liver** revealed a hypoechoic nodule in the mid cranial liver measuring 1.05 cm x 0.99 cm with two separate hypoechoic nodules measuring 0.68 cm and 0.7 cm. Increased portal markings were present. A larger nodule in the mid liver measured 1.2 cm.

Gastrointestinal

Examination of the **gastrointestinal tract** revealed a stomach and intestine free of stasis, of normal wall thickness, acceptable curvilinear mural detail, and peristaltic activity. Small and large intestine demonstrated normal luminal chyme and stool consistency respectively. No obstructive or overt infiltrative disease was noted. No associated abnormal lymphatic activity was noted.

Pancreas



PATIENT

Theodore Morse

SPECIES

Canine

BREED

Pug

SEX

Neutered Male

AGE

10 Years 3 Months

WEIGHT

21.8 lbs

INTERPRETED BY

Eric Lindquist, DMV,
DABVP(CFM), Cert.
IVUSS

IMAGING PERFORMED BY

Brittney Beigel, DVM

HOSPITAL NAME

Bayside Animal
Medical Center

REFERRING VET

Katie Buchanan, VMD

INVOICE

16487

DATE

05/22/26

The right body of the **pancreas** revealed a hypoechoic nodule measuring approximately 1.0 cm, potential insulinoma.

Free Abdomen

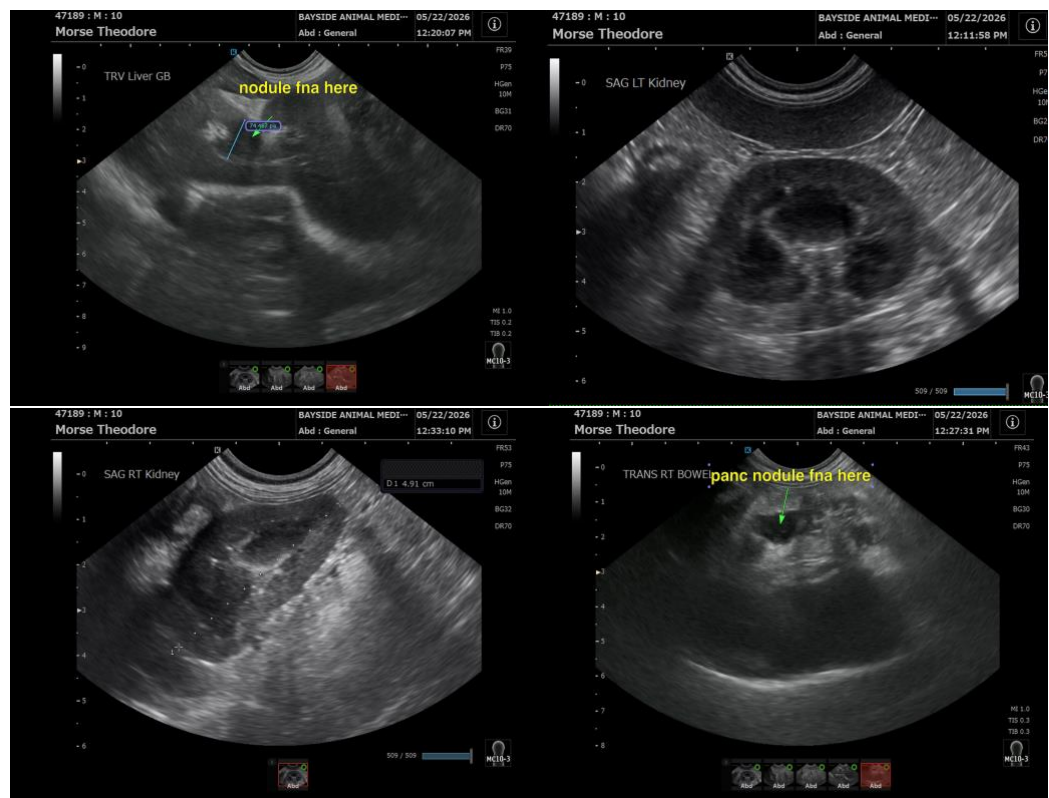
The enlarged mesenteric **lymph nodes** presented normal length to width ratio with slight, swollen contour. There was no loss of parenchymal detail. This is most consistent with reactive lymphadenitis or lymphatic hyperplasia. The lymph nodes measured up to 2.37 cm x 0.73 cm.

ULTRASONOGRAPHIC FINDINGS

- Hepatic nodules.
- Potential metastatic lesions.

INTERPRETATION OF THE FINDINGS & FURTHER RECOMMENDATIONS

Insulin glucose ratio is recommended in this patient. I am strongly concerned for metastatic insulinoma. 25-gauge FNA of the pancreatic lesion as well as the hepatic lesions are warranted.





PATIENT

Theodore Morse

SPECIES

Canine

BREED

Pug

SEX

Neutered Male

AGE

10 Years 3 Months

WEIGHT

21.8 lbs

INTERPRETED BY

Eric Lindquist, DMV,
DABVP(CFM), Cert.
IVUSS

IMAGING PERFORMED BY

Brittney Beigel, DVM

HOSPITAL NAME

Bayside Animal
Medical Center

REFERRING VET

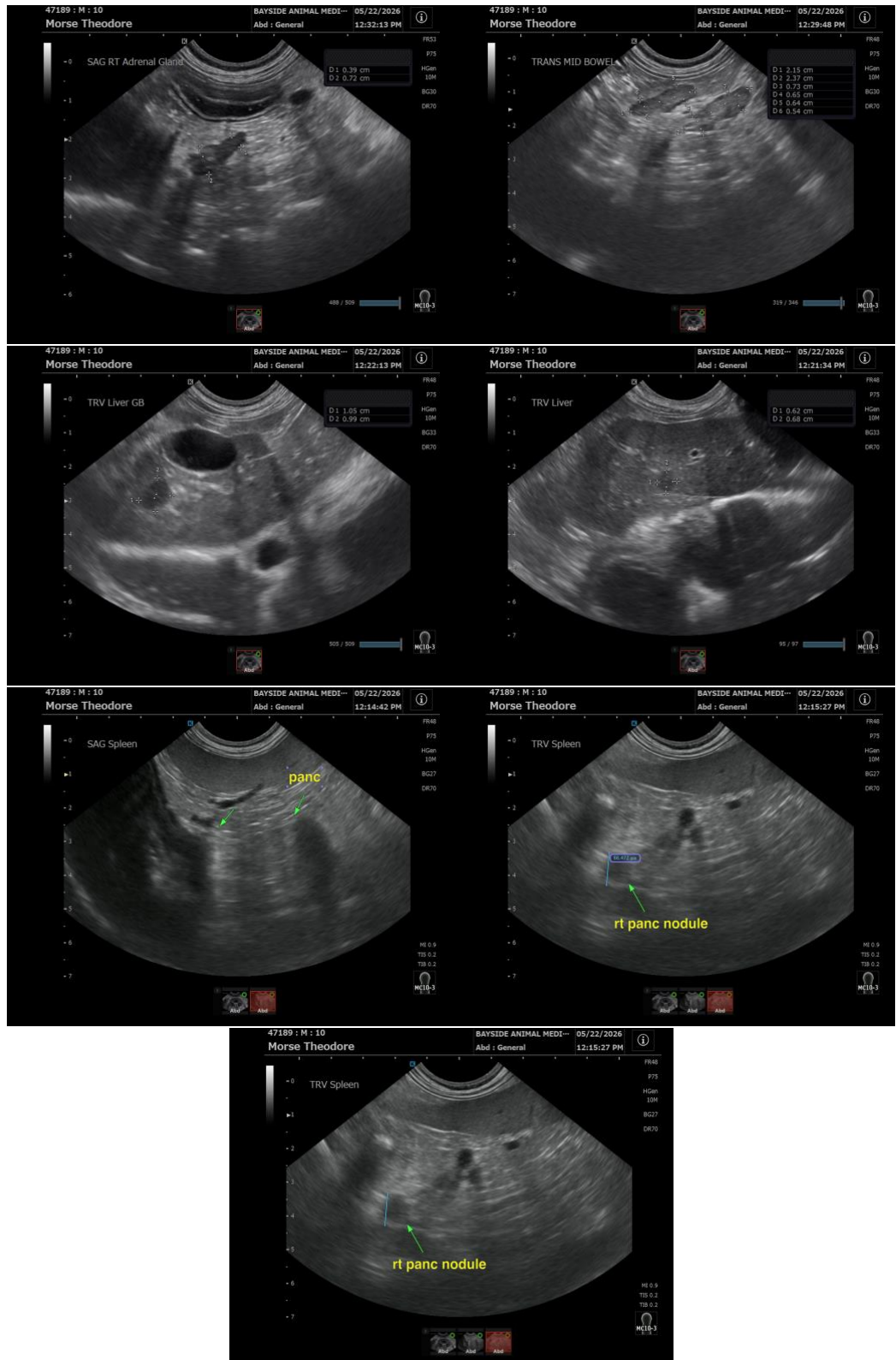
Katie Buchanan, VMD

INVOICE

16487

DATE

05/22/26





PATIENT

Theodore Morse

The information and recommendations provided are based on the images presented by the referring veterinarian/sonographer. No evaluation can be communicated regarding pathology that was not visible in the image/video clips provided.

SPECIES

Canine

Thank you for this referral. If the clinical or image interpretation does not parallel your findings or if I can be of any further assistance, please contact me.

BREED

Pug

Eric Lindquist, DMV, DABVP(CFM), Cert. IVUSS,

CEO, Owner, Founder -- SonoPath.com

SEX

Neutered Male

The following is an applicable excerpt from the *Curbside Guide to Diagnosis & Treatment of Sonographic Disease* offered by SonoPath.com Lindquist, Frank, Lobetti, and Modler.

AGE

10 Years 3 Months

An essential quick guide for every general practitioner and sonographer.


WEIGHT

21.8 lbs

info@SonoPath.com

INTERPRETED BY

Eric Lindquist, DMV,
DABVP(CFM), Cert.
IVUSS



IMAGING PERFORMED BY

Brittney Beigel, DVM

Hypoglycemic Syndrome: Insulinoma and Other

HOSPITAL NAME

Bayside Animal
Medical Center

<http://www.sonopath.com/Hypoglycemia>

REFERRING VET

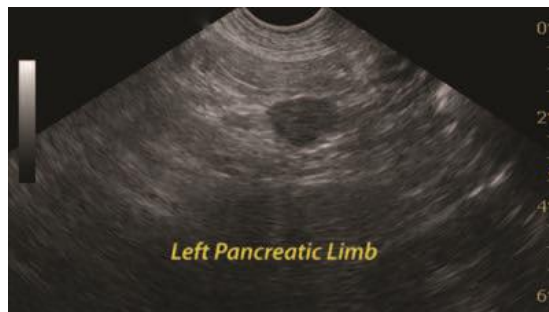Katie Buchanan, VMD

INVOICE

16487

DATE

05/22/26



Short axis of the left pancreatic limb in a dog with an insulinoma seen as an ovoid hypochoic mass lesion expanding the pancreatic capsule.



PATIENT

Theodore Morse

Description: Hypoglycemia can be found incidentally or associated with non-specific clinical signs, such as listlessness and weakness. It is essential to consider the multiple differentials for hypoglycemia in order to avoid a potential hypoglycemic crisis. One must perform a rapid and efficient workup to arrive at a diagnosis and prescribe the proper therapy.

SPECIES

Canine

Differentials for hypoglycemia include: laboratory or handling error; sepsis; toxins (e.g. xylitol, ethylene glycol); hunting dog hypoglycemia; Addison's disease; polycythemia; liver failure; poorly regulated diabetes mellitus; and neoplasia (e.g. leiomyosarcoma, hepatic, lymphoma, and insulinoma).

BREED

Pug

Once other causes of hypoglycemia have been ruled out, one may initiate an investigation into the possibility of insulinoma. Insulinoma is a tumor of the pancreas that originates in the beta cells and leads to the unregulated secretion of insulin and hypoglycemic syndrome. The tumor can be a malignant carcinoma or a more benign form of adenoma. There is, however, controversy regarding the exact histopathology associated with insulinoma types.

SEX

Neutered Male

AGE

10 Years 3 Months

Insulinoma patients are usually middle-aged dogs. Half of all cases present with metastasis to the lymph nodes, liver, and mesentery at the time of diagnosis. There are 3 stages of insulinoma:

WEIGHT

21.8 lbs

Stage 1: Pancreatic localization

Stage 2: Pancreas and lymph nodes with a median survival time (MST) of 1.5 years

Stage 3: Organ metastasis with an MST of 6 months.

INTERPRETED BY

Eric Lindquist, DMV,
DABVP(CFM), Cert.
IVUSS

Clinical Signs: Neuroglycopenia syndrome results in lethargy, ataxia, collapse, and seizures. Catecholamine release from hypoglycemia leads to hunger, behavior changes, and muscle tremors. Postprandial exacerbation of clinical signs can occur.

IMAGING PERFORMED BY

Brittney Beigel, DVM

Diagnostics: When investigating for insulinoma, one should use a fluoride-containing tube (i.e., a grey top tube) to obtain an accurate glucose level. A fasting glucose level below 60 mg/dl is diagnostic for hypoglycemia. Insulinoma is indicated when one observes the Whipple's triad of hypoglycemia, clinical signs consistent are with hypoglycemia, and the latter resolve with the administration of dextrose.

HOSPITAL NAME

Bayside Animal
Medical Center

REFERRING VET

Katie Buchanan, VMD

Fasting insulin and glucose ratio: A high normal to elevated insulin level with glucose < 60 mg/dl is diagnostic for insulinoma.

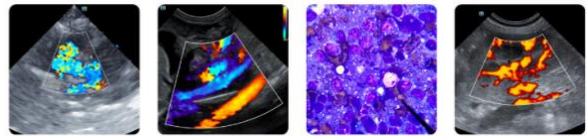
INVOICE

16487

Imaging: Localizing the lesion with staging is best approached by ultrasound. The ability to localize the lesion may be highly operator- and/or machine-dependent given the often small or even microscopic nature of insulinoma, especially early on in the disease. Primary or secondary lesions associated with insulinoma can often be identified with higher resolution sonography. Appropriate ultrasound-guided sampling (FNA or core biopsy) can be performed of any enlarged lymph node or hepatic nodule if a primary pancreatic lesion is not seen.

DATE

05/22/26



PATIENT

Theodore Morse

Computed tomography (CT) with contrast is likely more sensitive than the average sonographer when it comes to assessing insulinoma.

SPECIES

Canine

Tumor staging and histopathological characterization in conjunction with the Ki67 biomarker index will yield solid criteria for the prognostic evaluation of insulinoma.

BREED

Pug

Treatment:

In cases of emergency hypoglycemic crisis, apply corn syrup to the gums. Administer a dextrose bolus (0.5g/kg IV) and maintain 2.5-10% dextrose solution. If cerebral edema occurs, one should administer dexamethasone (2 mg/kg IV) and give mannitol (0.5 mg/kg IV) over a 20-minute period.

SEX

Neutered Male

AGE

10 Years 3 Months

One should perform a surgical pancreatectomy if the tumor is localized (i.e., stage 1 insulinoma). Given that the lesion may be difficult to locate with the naked surgical eye or via palpation, the surgical procedure can be enhanced by intraoperative ultrasound.

WEIGHT

21.8 lbs

In cases of stage 2 and 3 insulinoma, administer prednisolone (0.25 mg/kg PO BID). A glucagon IV infusion has also been suggested; it should be infused with saline at 5 mg/kg/min for refractory cases. If prednisone is not adequate, one can supplement with benzothiadiazide diazoxide (5 mg/kg PO BID).

INTERPRETED BY

Eric Lindquist, DMV,
DABVP(CFM), Cert.
IVUSS

Patients should be fed small, frequent portions of a diet high in fat, complex carbohydrates, and protein.

IMAGING PERFORMED BY

Brittney Beigel, DVM

Chemotherapy: In some cases, the use of alloxan (65 mg/ kg IV) has been shown to be helpful.

HOSPITAL NAME

Bayside Animal
Medical Center

Conclusion: The largest study of insulinoma patients identified a general MST of 547 days; however, the MST was 785 days for those undergoing pancreatectomy and 1316 days for those that relapsed after surgery and received treatment with prednisone. Other studies have reported an MST of 258 days with pancreatectomy. All of these results indicate that insulinoma is treatable. Using ultrasonography for staging and histopathological characterization is essential in order to determine whether the appropriate treatment should be surgical, medical, or both.

REFERRING VET

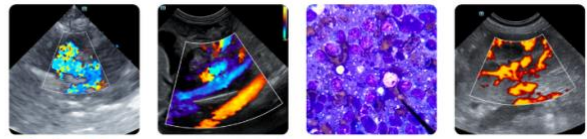
Katie Buchanan, VMD

INVOICE

16487

DATE

05/22/26



PATIENT

Theodore Morse

SPECIES

Canine

BREED

Pug

SEX

Neutered Male

AGE

10 Years 3 Months

WEIGHT

21.8 lbs

INTERPRETED BY

Eric Lindquist, DMV,
DABVP(CFM), Cert.
IVUSS

IMAGING PERFORMED BY

Brittney Beigel, DVM

HOSPITAL NAME

Bayside Animal
Medical Center

REFERRING VET

Katie Buchanan, VMD

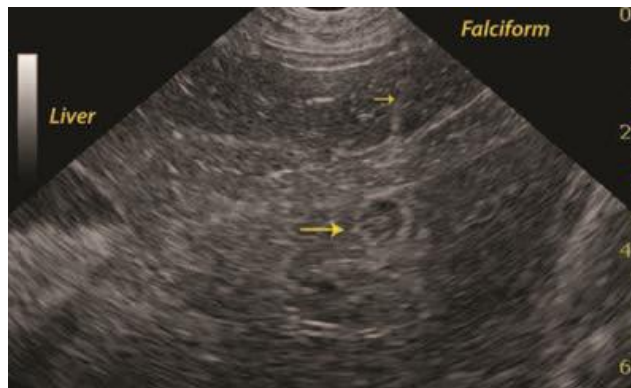
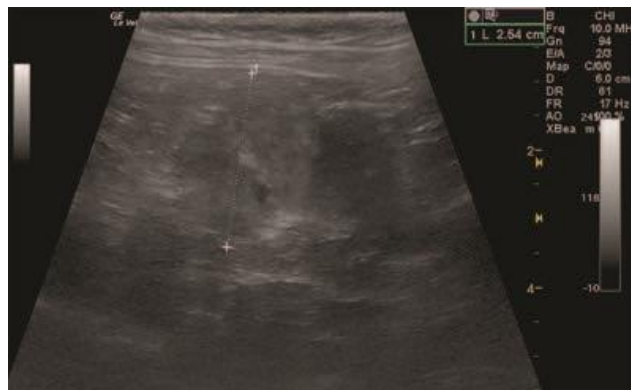INVOICE

16487

DATE

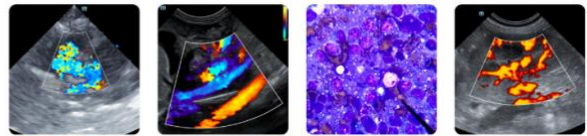
05/22/26

Short axis of the left pancreatic limb in a cat with an insulinoma seen as a complex heterogenous mass lesion expanding the pancreatic capsule (between calipers). Note the mass effect of the tumor displacing the transverse colon caudally.



Subxiphoidal short axis of the liver in a dog with an insulinoma during ultrasound guided sampling of a suspected metastatic lesion.

The needle trajectory is seen as a hyperechoic line (small arrow) approaching the hypoechoic nodule (large arrow) within the liver parenchyma.



PATIENT

Theodore Morse

SPECIES

Canine

BREED

Pug

SEX

Neutered Male

AGE

10 Years 3 Months

WEIGHT

21.8 lbs

INTERPRETED BY

Eric Lindquist, DMV,
DABVP(CFM), Cert.
IVUSS

IMAGING PERFORMED BY

Brittney Beigel, DVM

HOSPITAL NAME

Bayside Animal
Medical Center

REFERRING VET

Katie Buchanan, VMD

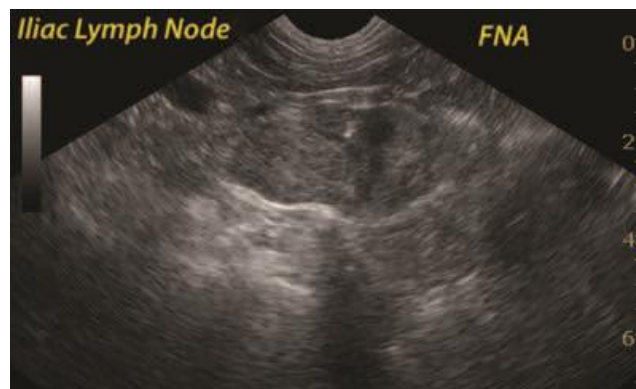
INVOICE

16487

DATE

05/22/26

Long axis of the medial iliac lymph node during needle aspiration in a dog with multifocal metastatic spread of an insulinoma. The echogenic needle tip is seen within the lymph node. The metastatic lymph node is enlarged, rounded, hypoechoic and heterogenous. The primary metastatic loci in insulinoma are the regional lymph nodes (hepatic, pancreaticoduodenal, gastric) and the liver. Hence, metastatic insulinoma lesions in the iliac lymph node in this case was not a typical occurrence.



References:

Buishand FO, Kik M, Kirpensteijn J. Evaluation of clinico-pathological criteria and the Ki67 index as prognostic indicators in canine insulinoma. *Vet J* 2010;185:62-67.

Fischer JR, Smith SA, Harkin KR: Glucagon constant-rate infusion: A novel strategy for management of hyperinsulinemic-hypoglycemia crisis in the dog. *J Am Anim Hosp Assoc* 2000;36:27-32.

Polton GA, White RN, Brearley MJ, et al. Improved survival in a retrospective cohort of 28 dogs with insulinoma. *J Small Anim Pract* 2000;48:151-56.

Steiner JM, Bruyette DS: Canine insulinoma. *Compend Contin Educ Pract Vet* 1996;18:31-36.

Tobin RL, Nelson RW, Lucroy MD, et al. Outcome of surgical versus medical treatment of dogs with beta cell neoplasia: 39 cases (1990-1997). *JAVMA* 1999;215:226-30.