



PATIENT

Quincy Abrahamsen

SPECIES

Feline

BREED

DSH

SEX

Neutered Male

AGE

15

WEIGHT

10.7

INTERPRETED BY

Eric Lindquist, DMV,
DABVP (CFM), Cert.
IVUSS

IMAGING PERFORMED BY

Jenn

HOSPITAL NAME

Rockaway Animal
Hospital

REFERRING VET

Dr. Daly

INVOICE

75363

DATE

5/22/26

PRESENTING CLINICAL SIGNS

Cat was diagnosed with diabetes , started on Bexacat which decreased appetite , stopped Bexacat appetite did not improve . Vomited food and bile PU/PD r/o pancreatitis, metabolic issue, neoplasia
Current meds Cerenia

ULTRASONOGRAPHIC EXAMINATION OF THE ABDOMEN

Urinary System

The **urinary bladder**, trigone, and pelvic urethra presented normal thicknesses and normal tone. The ureters were not visible which is normal. No uroliths or sediment were visualized and anechoic urine was present. No evidence of inflammatory or neoplastic changes were noted. Ureteral papillae were normal. The pelvic urethra was imaged 2.0 cm beyond the cystourethral junction.

The **kidneys** revealed largely normal size and structure, corticomedullary definition and ratio (cortex 1/3 of medulla) were essentially maintained with some age-related loss of curvilinear patterns regarding the capsule and C/M junction. The cortices presented largely uniform texture with some increased echogenicity expected for his age patient. Medullary structure differed distinctly from that of the cortex and no evidence of pelvic dilation was present. Right kidney measured 4.33 cm. Left kidney measured 4.37 cm.

Adrenal Glands

The regions of the **adrenal glands** were unremarkable.

Spleen

The **spleen** was subnormal in size with slight micronodular changes noted.

Liver

The **liver** images from right and left intercostal as well as subcostal views revealed subjectively normal liver size, contour, and structure. Some age-related parenchymal remodeling was noted but likely not clinically significant at this time. Vascular and biliary tracts were of normal volume and no evidence of congestion was noted. The gallbladder presented some dependent debris with essentially normal contour. The cystic and common bile ducts were normal. No overt evidence of active inflammatory, infiltrative or regenerative pathology was noted but should be paired with current or past LE elevations regarding any clinical significance to this presentation. The hepatic lymph nodes were unremarkable.

Gastrointestinal

The **gastrointestinal tract** revealed minor variable thickening and echogenic submucosal changes most consistent with low grade end result of chronic GI disease such as IBD and may be related to malassimilation of nutrients if any weight loss is present. No obvious neoplastic patterns were noted and luminal content as unremarkable.

Pancreas

The base and limbs of the **pancreas** were observed to be largely isoechoic to surrounding omental fat. Pancreatic duct and capsular contour were acceptably normal and parenchyma respected normal curvilinear patterns. No overt evidence of active inflammatory or neoplastic disease was noted.



PATIENT

Free Abdomen

Quincy Abrahamsen

Multiple enlarged, hypoechoic mesenteric lymph nodes were noted, measuring up to 2.0 cm x 1.0 cm with reactive surrounding mesentery.

SPECIES

Feline

BREED

DSH

SEX

Neutered Male

AGE

15

WEIGHT

10.7

INTERPRETED BY

Eric Lindquist, DMV,
DABVP (CFM), Cert.
IVUSS

IMAGING PERFORMED BY

Jenn

HOSPITAL NAME

Rockaway Animal
Hospital

REFERRING VET

Dr. Daly

INVOICE

75363

DATE

5/22/26

ULTRASONOGRAPHIC FINDINGS

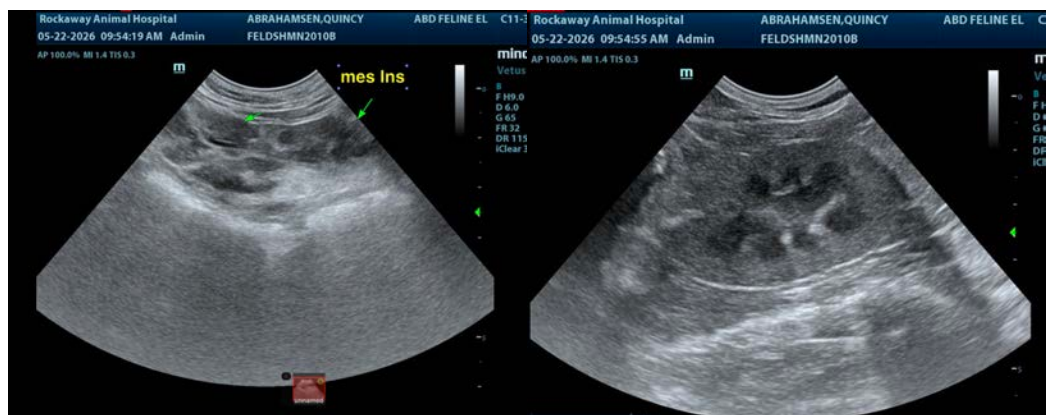- Mesenteric lymphadenopathy.
- Chronic GI and hepatic changes.
- Slight micronodular spleen.
- Age related renal changes.

INTERPRETATION OF THE FINDINGS & FURTHER RECOMMENDATIONS

Ultrasound guided FNA of the mesenteric lymph node with cytology and culture indicated. Mild potential for emerging round cell neoplasia versus lymphadenitis.

This is a suggestive checkoff list when faced with an unregulated diabetic patient:

- UTI
- Dietary indiscretion/intolerance
- Pancreatitis
- Hyperthyroidism/hypothyroidism
- Exogenous steroids (including topical eye meds)
- Cushing's
- Acromegaly
- Owner compliance
- Insulin quality issues
- Antibodies to insulin
- Underlying Neoplasia
- Diffuse liver disease





PATIENT

Quincy Abrahamsen

SPECIES

Feline

BREED

DSH

SEX

Neutered Male

AGE

15

WEIGHT

10.7

INTERPRETED BY

Eric Lindquist, DMV,
DABVP (CFM), Cert.
IVUSS

IMAGING PERFORMED BY

Jenn

HOSPITAL NAME

Rockaway Animal
Hospital

REFERRING VET

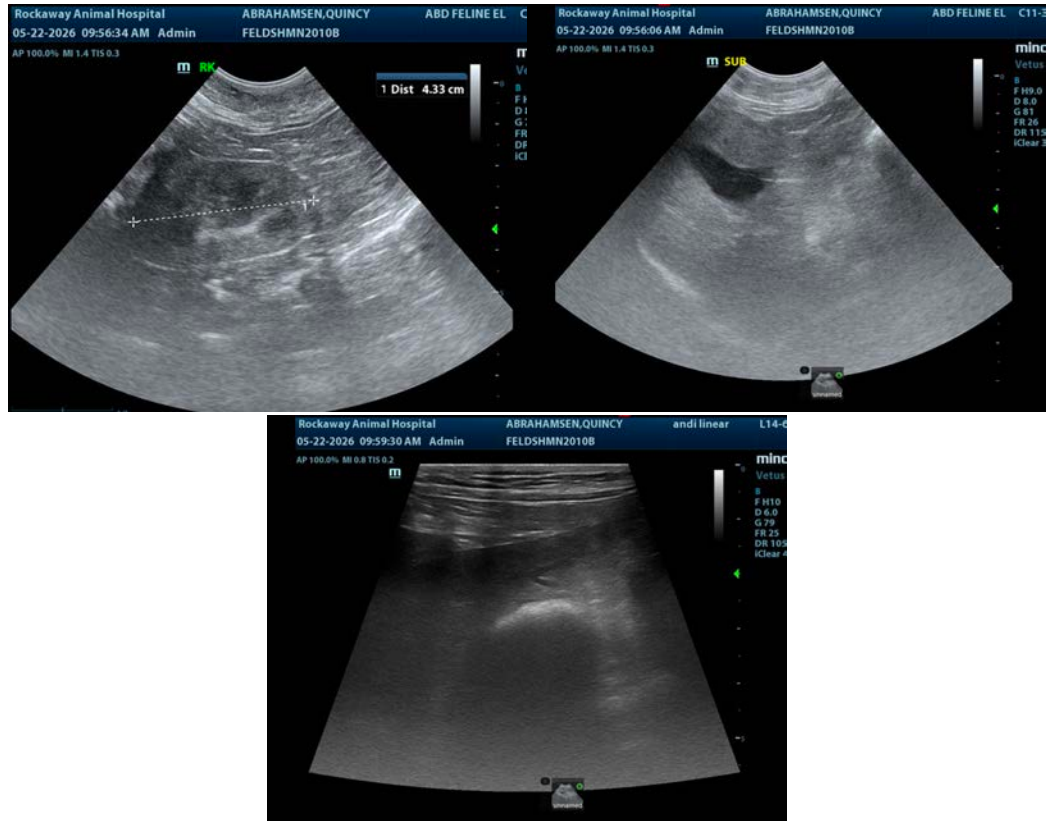
Dr. Daly

INVOICE

75363

DATE

5/22/26



The information and recommendations provided are based on the images presented by the referring veterinarian/sonographer. No evaluation can be communicated regarding pathology that was not visible in the image/video clips provided.

Thank you for this referral. If the clinical or image interpretation does not parallel your findings or if I can be of any further assistance please contact me.

Eric Lindquist, DMV, DABVP(CFM), Cert. IVUSS,
CEO, Owner, Founder -- SonoPath.com
info@SonoPath.com