



PATIENT

Puck Peters

SPECIES

Feline

BREED

Maine Coon

SEX

Neutered Male

AGE

12 Years

WEIGHT

16.8

INTERPRETED BY

Eric Lindquist, DMV,
DABVP (CFM), Cert.
IVUSS

IMAGING PERFORMED BY

Dr. Andrew Keller

HOSPITAL NAME

Birch Bark Veterinary
Clinic

REFERRING VET

Dr. Andrew Keller

INVOICE

75378

DATE

5/22/26

PRESENTING CLINICAL SIGNS

Presenting Complaint: Cardiorespiratory. Patient History, Physical Exam & Diagnostics. Past pertinent medical history: history of chronic respiratory issues, otitis media with suspected polyps and recurrent struvite crystalluria. Clinical Signs and duration: coughing since 2017. Physical exam summary: excessive phlegm increased upper respiratory noise. Treatment: prednisolone 5mg SID. Last meal and mealtime: Last night. Clinical Concerns: Coughing gagging chronic but signs worsening - minimal response to low dose steroids

ULTRASONOGRAPHIC EXAMINATION OF THE ABDOMEN

Urinary System

The **urinary bladder**, trigone, and pelvic urethra presented normal thicknesses and normal tone. The ureters were not visible which is normal. No uroliths or sediment were visualized and anechoic urine was present. No evidence of inflammatory or neoplastic changes were noted. Ureteral papillae were normal. The pelvic urethra was imaged 2.0 cm beyond the cystourethral junction.

The **kidneys** revealed normal size and structure, corticomedullary definition and ratio for this age. The cortices presented largely uniform texture with normal echogenic relationship to liver and spleen. Medullary structure differed distinctly from the cortex and no evidence of pelvic dilation was present. The capsules were acceptably uniform without significant irregularities. Left kidney measured 4.4 cm. Right kidney measured 5.2 cm.

Adrenal Glands

Both **adrenal glands** were visualized and recognized as having normal shape, size, position and echogenicity for this breed. The phrenic vasculature, glandular echogenicity and detail were unremarkable. Capsule, cortex, and medullary definition were normal for this age patient. The adrenals measured 0.40 cm each.

Spleen

The **spleen** presented a smooth homogeneous parenchyma hyperechoic to liver and renal cortical parenchyma. The capsule was smooth without noticeable expansion or deviation from within the spleen or adjacent pathology. The splenic vasculature demonstrated normal volume without signs of congestion or thrombosis. No sonographic evidence of acute or chronic inflammatory, neoplastic, or infarctual changes were noted.

Liver

The **liver** images submitted revealed subjectively normal liver size, contour, and structure. Parenchymal echogenicity was naturally coarse and hypoechoic to the spleen. Vascular and biliary tracts were of normal volume with no evidence of congestion. The gallbladder presented acceptably thin walls with primarily anechoic content. The cystic and common bile ducts were normal. No pathological hepatic lymphadenopathy was evident. No overt structural evidence of inflammatory, infiltrative or regenerative pathology was evident.



PATIENT

Puck Peters

SPECIES

Feline

BREED

Maine Coon

SEX

Neutered Male

AGE

12 Years

WEIGHT

16.8

INTERPRETED BY

Eric Lindquist, DMV,
DABVP (CFM), Cert.
IVUSS

IMAGING PERFORMED BY

Dr. Andrew Keller

HOSPITAL NAME

Birch Bark Veterinary
Clinic

REFERRING VET

Dr. Andrew Keller

INVOICE

75378

DATE

5/22/26

Gastrointestinal

Trace luminal fluid noted in the **stomach**, unremarkable otherwise. Small and large intestine demonstrated normal luminal chyme and stool consistency respectively. No obstructive or overt infiltrative disease was noted. No associated abnormal lymphatic activity was noted.

Pancreas

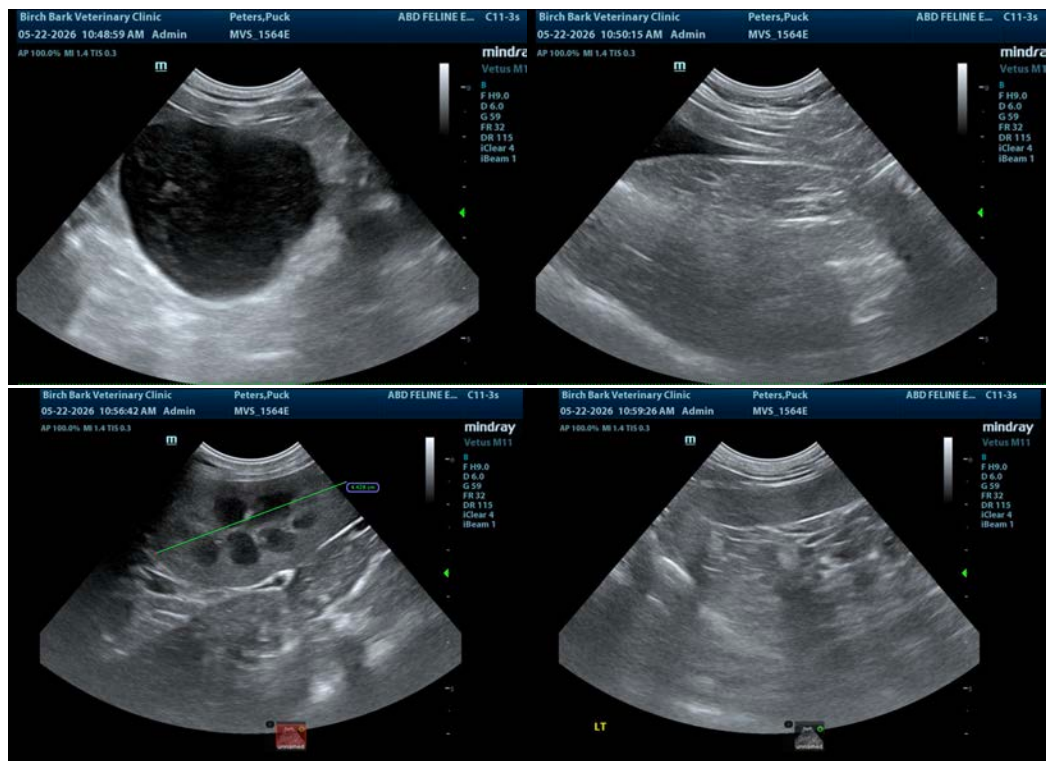
The base and limbs of the **pancreas** were observed to be largely isoechoic to surrounding omental fat. Pancreatic duct and capsular contour were acceptably normal and parenchyma respected normal curvilinear patterns. No overt evidence of active inflammatory or neoplastic disease was noted.

ULTRASONOGRAPHIC FINDINGS

- Structurally unremarkable abdomen.

INTERPRETATION OF THE FINDINGS & FURTHER RECOMMENDATIONS

No evidence of primary disease. *Note the Prednisone treatment could be suppressing a more significant presentation yet no evidence of significant visceral pathology noted on this ultrasound.





PATIENT

Puck Peters

SPECIES

Feline

BREED

Maine Coon

SEX

Neutered Male

AGE

12 Years

WEIGHT

16.8

INTERPRETED BY

Eric Lindquist, DMV,
DABVP (CFM), Cert.
IVUSS

IMAGING PERFORMED BY

Dr. Andrew Keller

HOSPITAL NAME

Birch Bark Veterinary
Clinic

REFERRING VET

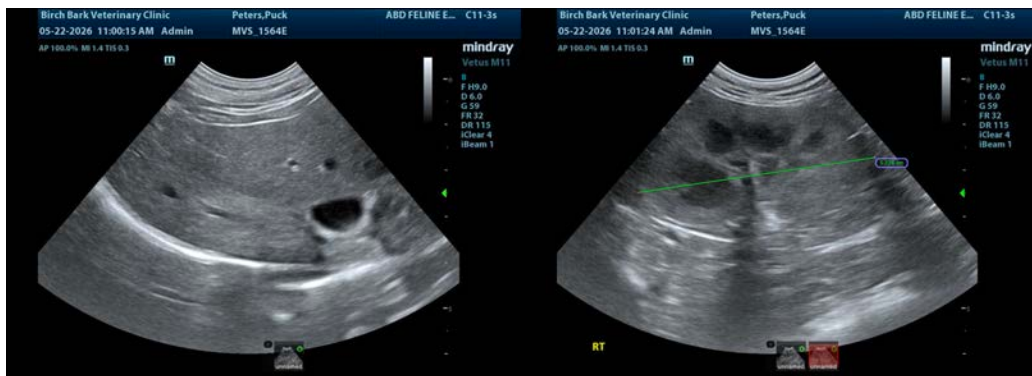
Dr. Andrew Keller

INVOICE

75378

DATE

5/22/26



The information and recommendations provided are based on the images presented by the referring veterinarian/sonographer. No evaluation can be communicated regarding pathology that was not visible in the image/video clips provided.

Thank you for this referral. If the clinical or image interpretation does not parallel your findings or if I can be of any further assistance please contact me.

Eric Lindquist, DMV, DABVP(CFM), Cert. IVUSS,
CEO, Owner, Founder -- SonoPath.com
info@SonoPath.com