



## PATIENT

Leia Cambruzzi

## SPECIES

Canine

## BREED

Border Collie x

## SEX

Spayed Female

## AGE

12 Years 5 Months

## WEIGHT

21 kg

## INTERPRETED BY

Eric Lindquist, DMV,  
DABVP (CFM), Cert.  
IVUSS

## IMAGING PERFORMED BY

Dr. Kaitlyn Varga

## HOSPITAL NAME

Shuswap Veterinary  
Clinic

## REFERRING VET

Dr. Kaitlyn Varga

## INVOICE

75389

## DATE

5/22/26

## PRESENTING CLINICAL SIGNS

Re-check cardiac ultrasound. Clinically doing well. Currently on 6.25mg pimobendan (0.3mg/kg) PO q12hr + benazapril 10mg PO q24hr. Slight weight loss. Resting respiratory rates are WNL (<24/minute)

Abnormal PE/Chem/CBC/UA Results: Grade 5-6/6 holosystolic murmur. Normal sinus arrhythmia. Pulses are strong and synchronus. Pulmonary auscultation WNL. Senior bloodwork relatively unremarkable- very mild hypoalbuminemia 29.5 (RR 30-40). Thoxic radiographs VHS= 11.2

## ULTRASONOGRAPHIC EXAMINATION OF THE HEART

CANINE CARDIAC PARAMETERS	MR VMAX (m/s)	TR VMAX (m/s)	LA/AO (M-Mode)	LA/AO (Heart Base; Swe)	FS (%)	EF (%)	EPSS (cm)
NORMAL PARAMETER	4.5-5.5	<2.7	1.3	Up to 1.6	28-40	40-100	<0.6
PATIENT	--	--	1.5	2.1	27	55	0.1
CANINE CARDIAC PARAMETERS	HR (BPM)	AV VMAX (m/s)	PV MAX (m/s)	BODY WEIGHT (kg)	LAD LA MAX 4 Chamber	LVIDd Avg; 2D and m-mode short axis (cm)	LVIDs Avg; 2D and m-mode short axis (cm)
NORMAL PARAMETER	50-100	0.7-1.7	0.7-1.6				
PATIENT	80	--	0.65	21.0	4.87	2.83	--

## Cardiac Presentation

The cardiac presentation presented mild persistent volume overload of the left atrium and left ventricle. Contractility appeared adequate. Mitral insufficiency noted. Minor tricuspid insufficiency noted. No pericardial or pleural effusion noted.

## ULTRASONOGRAPHIC FINDINGS

- Fairly stable B2 valvular disease on Pimobendan and Benazepril.

## INTERPRETATION OF THE FINDINGS & FURTHER RECOMMENDATIONS

Recommend adding Spironolactone at 1-2 mg /kg SID in this patient. Abdominal sonogram recommended to assess for cause of weight loss. Recheck echo in 6-12 months depending upon clinical status.



## PATIENT

Leia Cambruzzi

## SPECIES

Canine

## BREED

Border Collie x

## SEX

Spayed Female

## AGE

12 Years 5 Months

## WEIGHT

21 kg

## INTERPRETED BY

Eric Lindquist, DMV,  
DABVP (CFM), Cert.  
IVUSS

## IMAGING PERFORMED BY

Dr. Kaitlyn Varga

## HOSPITAL NAME

Shuswap Veterinary  
Clinic

## REFERRING VET

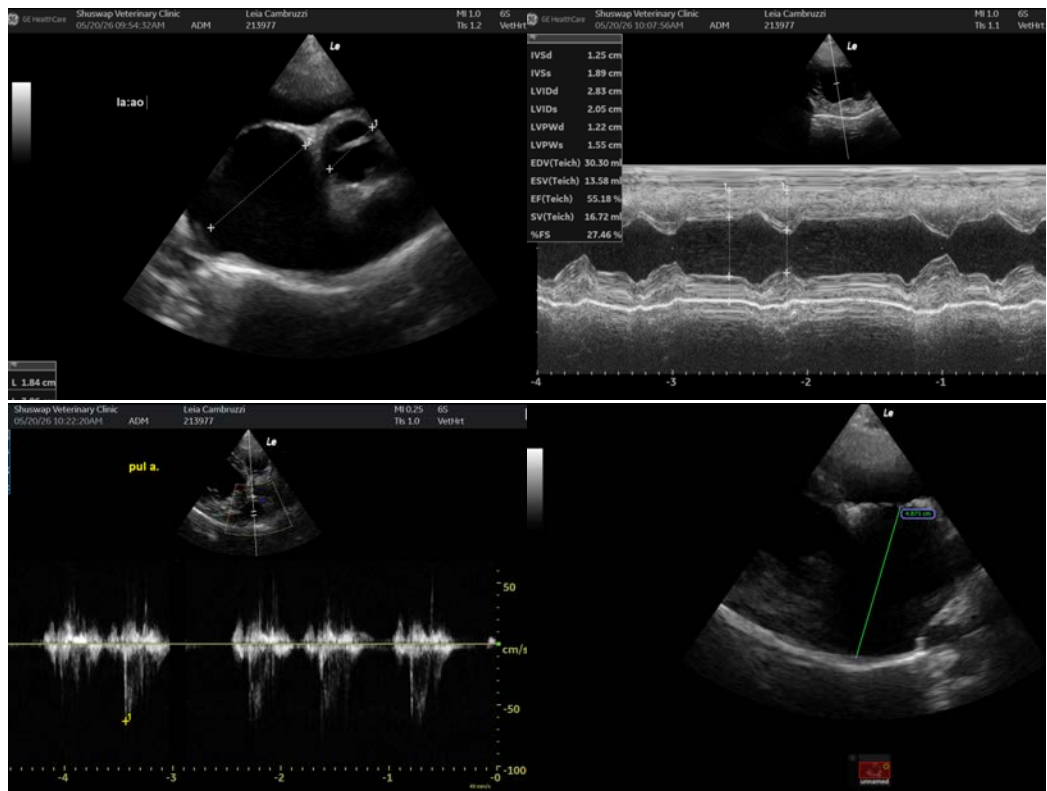
Dr. Kaitlyn Varga

## INVOICE

75389

## DATE

5/22/26



The information and recommendations provided are based on the images presented by the referring veterinarian/sonographer. No evaluation can be communicated regarding pathology that was not visible in the image/video clips provided.

Thank you for this referral. If the clinical or image interpretation does not parallel your findings or if I can be of any further assistance please contact me.

**Eric Lindquist**, DMV, DABVP(CFM), Cert. IVUSS,  
CEO, Owner, Founder -- SonoPath.com  
[info@SonoPath.com](mailto:info@SonoPath.com)