

PATIENT

Buster Burgher

SPECIES

Feline

BREED

DSH

SEX

Neutered Male

AGE

1 Year 11 Months

WEIGHT

8.0 lbs

INTERPRETED BY

Eric Lindquist, DMV,
DABVP (CFM), Cert.
IVUSS

IMAGING PERFORMED BY

Dr. Kathleen Laux

HOSPITAL NAME

Rondout Valley
Veterinary Associates

REFERRING VET

Dr. Kathleen Laux

INVOICE

75379

DATE

5/22/26

PRESENTING CLINICAL SIGNS

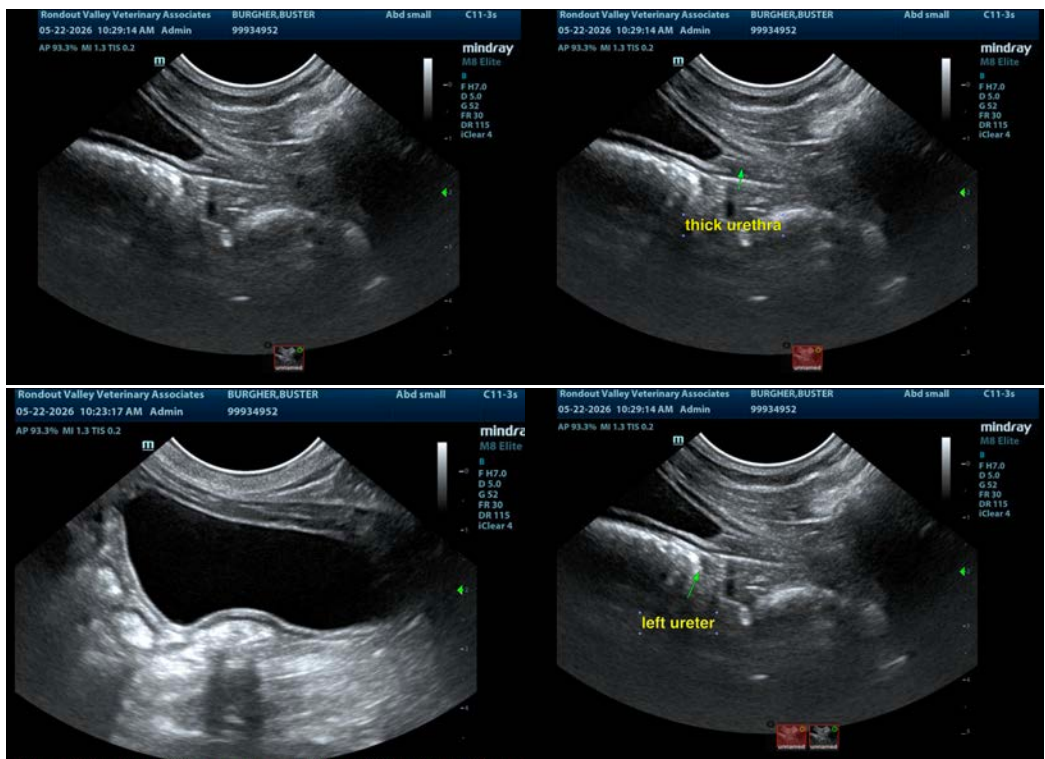
Been leaking urine per owner. Sometimes blood present per owner. Also sprays sometimes per owner
Abnormal PE/Chem/CBC/UA Results: UA: sp Gr 1.030, pH 5.0, prot trace, RBC 56, cocci many

LIMITED ULTRASONOGRAPHIC EXAMINATION

The cranial aspect and body of the urinary bladder appeared normal. Ureteral jets appeared to enter into the cystourethral junction further caudal than normal. The left ureter was visible yet slightly dilated.

INTERPRETATION OF THE FINDINGS & FURTHER RECOMMENDATIONS

There is a strong potential for ectopic ureter in this patient. However, this is difficult to confirm on sonogram. Recommend CT with contrast to assess for possible placement. Renal ultrasound warranted as well to assess for concurrent anomalies. No significant ureteral dilation or abnormal hyperperistalsis of the ureters noted which are negative predictive factors for ectopic ureters. Management for the UTI warranted with urine culture and sensitivity, and antibiotic therapy empirically. If clinical signs persist then CT with contrast is strongly encouraged.





PATIENT

Buster Burgher

SPECIES

Feline

BREED

DSH

SEX

Neutered Male

AGE

1 Year 11 Months

WEIGHT

8.0 lbs

INTERPRETED BY

Eric Lindquist, DMV,
DABVP (CFM), Cert.
IVUSS

IMAGING PERFORMED BY

Dr. Kathleen Laux

HOSPITAL NAME

Rondout Valley
Veterinary Associates

REFERRING VET

Dr. Kathleen Laux

INVOICE

75379

DATE

5/22/26

The information and recommendations provided are based on the images presented by the referring veterinarian/sonographer. No evaluation can be communicated regarding pathology that was not visible in the image/video clips provided.

Thank you for this referral. If the clinical or image interpretation does not parallel your findings or if I can be of any further assistance please contact me.

Eric Lindquist, DMV, DABVP(CFM), Cert. IVUSS,
CEO, Owner, Founder -- SonoPath.com
info@SonoPath.com