



## PATIENT

Winston Weakleand

## SPECIES

Canine

## BREED

Cavalier King Charles

## SEX

Neutered male

## AGE

5 years

## WEIGHT

15.4 lbs

## INTERPRETED BY

Eric Lindquist, DMV  
DABVP, Cert. IVUSS

## IMAGING PERFORMED BY

Gillian Striano Kaplan

## HOSPITAL NAME

Ramsey VH

## REFERRING VET

Dr. Kaplan

## INVOICE

77851

## DATE

5/21/26

## PRESENTING CLINICAL SIGNS

History: 5/15--II/VI heart murmur  
H/O analsaculectomy--5/22/25  
BP--120 mmHg, 3cm, lf

## ULTRASONOGRAPHIC EXAMINATION OF THE HEART

The echocardiogram in this patient demonstrated enlarged **left atrial** size based on 3 different LA measurement methods. Chamber volumes and echogenicity were normal. The cranial and caudal **mitral** valve leaflets presented vegetative thickening consistent with endocardiosis. Doppler indicated measurable insufficiency. The **left ventricle** presented normal thicknesses with linear contour and was not dilated nor restricted. The **myocardium** presented normal echogenicity without subjective evidence of significant fibrotic or ischemic disease. **Contractility** of the ventricular walls was adequate and in normal range for this patient evidenced by the fractional shortening measurement and subjective evaluation of the different regions of the myocardium. The **left ventricular outflow** tract demonstrated normal laminar flow and subjective structural integrity. The **right atrium** and auricle revealed normal size, structure and content. No evidence of masses was noted or chamber overload. **Tricuspid** valvular assessment demonstrated adequate linear morphology. The **right ventricle** was of normal size (1/3 diameter of LV), chordae structure, myocardial echogenicity and thickness. **Pulmonic** tract assessment revealed normal valve structure, laminar flow, and diameter (approx. 1:1 pa/ao ratio). No visible **pericardial** or free pleura fluid was noted. No echographically detectable evidence of infiltrative disease was visible. The cranial **mediastinum and pericardial regions** were free of masses in the visible window.

CANINE CARDIAC PARAMETERS	MR VMAX (m/s)	TR VMAX (m/s)	LA/AO	LA/AO (Heart Base)	FS (%)	EF (%)	EPSS (cm)
NORMAL PARAMETER	4.5-5.5	<2.7	1.3	<1.6	28-40	40-100	<0.6
PATIENT	-	-	2.05	1.9	25	51	0.1
CANINE CARDIAC PARAMETERS	HR (BPM)	AV VMAX (m/s)	PV MAX (m/s)	BODY WEIGHT	LA 2D short axis Base view (cm)	LVIDd Avg; 2D and m-mode short axis (cm)	LVIDs Avg; 2D and m-mode short axis (cm)
NORMAL PARAMETER	50-100	0.7-1.7	0.7-1.6	BELOW	BELOW	BELOW	BELOW
PATIENT	-	1.5	-	15.4 lbs	3.3	3.07	

## ULTRASONOGRAPHIC FINDINGS

Mitral insufficiency.  
Mild left atrial enlargement.  
Stage B2 valvular disease.



## PATIENT

Winston Weakland

## SPECIES

Canine

## BREED

Cavalier King Charles

## SEX

Neutered male

## AGE

5 years

## WEIGHT

15.4 lbs

## INTERPRETED BY

Eric Lindquist, DMV  
DABVP, Cert. IVUSS

## IMAGING PERFORMED BY

Gillian Striano Kaplan

## HOSPITAL NAME

Ramsey VH

## REFERRING VET

Dr. Kaplan

## INVOICE

77851

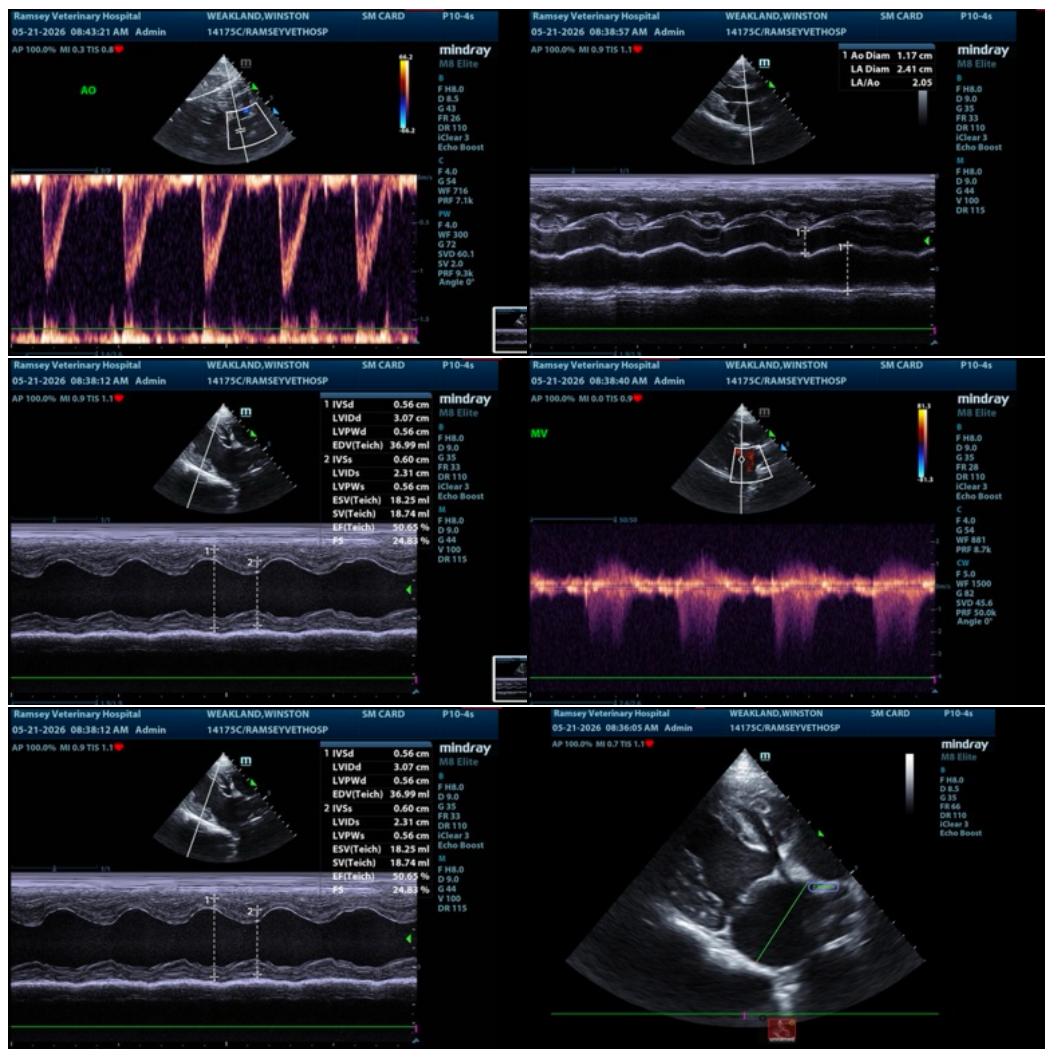
## DATE

5/21/26

## INTERPRETATION OF THE FINDINGS & FURTHER RECOMMENDATIONS

Pimobendan is indicated at 0.3 mg/kg b.i.d. Blood pressure measurements, EKG and chest radiographs are all warranted if not already performed.

The heart has minor volume overload and is working to compensate for the valvular insufficiency. Target respiratory rate is < 20 resp/minute after therapy. After initiating or adjusting therapy, I recommend recheck on the clinical exam, BUN, Creatinine, USG, Chest radiographs & Blood pressure in 5-7 days. Recheck echo in 3-6 months, earlier if clinical decompensation is occurring. Minor anesthetic risk for a brief procedure at this time. Repeat preanesthetic echo is ideal if anesthesia is eventually necessary. A suggested anesthetic combination would involve Torbutrol premed, propofol induction, Isoflurane maintenance or equivalent protocol.





## PATIENT

Winston Weakland

## SPECIES

Canine

## BREED

Cavalier King Charles

## SEX

Neutered male

## AGE

5 years

## WEIGHT

15.4 lbs

## INTERPRETED BY

Eric Lindquist, DMV  
DABVP, Cert. IVUSS

## IMAGING PERFORMED BY

Gillian Striano Kaplan

## HOSPITAL NAME

Ramsey VH

## REFERRING VET

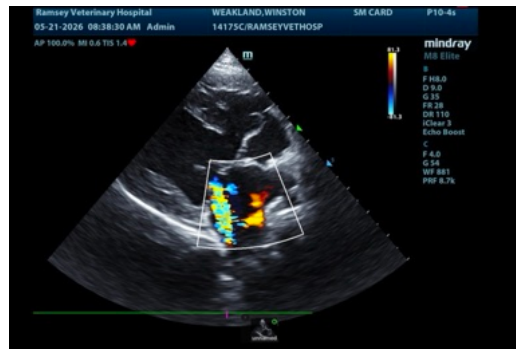Dr. Kaplan

## INVOICE

77851

## DATE

5/21/26



The information and recommendations provided are based on the images presented by the referring veterinarian/sonographer. No evaluation can be communicated regarding pathology that was not visible in the image/video clips provided.

Thank you for this referral. If the clinical or image interpretation does not parallel your findings or if I can be of any further assistance please contact me.

Eric Lindquist, DMV, DABVP (CFM), Cert. IVUSS, CEO of SonoPath.com

[info@SonoPath.com](mailto:info@SonoPath.com)