

PATIENT

Loki Raymond

SPECIES

Canine

BREED

Yorkshire Terrier

SEX

Neutered male

AGE

5 years

WEIGHT

14.8 lbs

INTERPRETED BY

Eric Lindquist, DMV
DABVP, Cert. IVUSS

IMAGING PERFORMED BY

Kathleen Laux

HOSPITAL NAME

Rondout Valley VA

REFERRING VET

Dr. Laux

INVOICE

77848

DATE

5/21/26

PRESENTING CLINICAL SIGNS

History: -been on metro and amoxi for 4 weeks now
-recheck pancreas US
-skips a meal occasionally, but mostly eating and no vomiting
-abdominal palpation comfortable

ULTRASONOGRAPHIC EXAMINATION

Four videos were submitted and revealed normal uniform left pancreatic limb. The curvilinear patterns were maintained. The right pancreas revealed minor, hypoechoic irregular parenchymal pattern. However, if inflammation is present, then it is minimal. This has largely resolved.

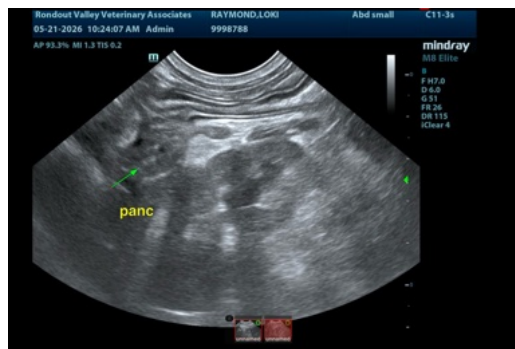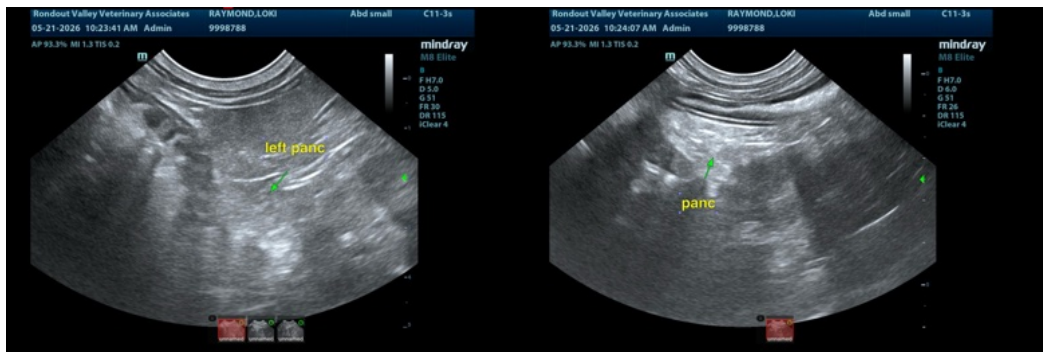
A minor amount of ingesta was noted in the stomach.

ULTRASONOGRAPHIC FINDINGS

90% resolved pancreatic presentation.

INTERPRETATION OF THE FINDINGS & FURTHER RECOMMENDATIONS

Antibiotics can likely be stopped at this point; however, strict dietary regimen is recommended long term. If clinical signs recur then a recheck sonogram is indicated.





PATIENT

Loki Raymond

SPECIES

Canine

BREED

Yorkshire Terrier

SEX

Neutered male

AGE

5 years

WEIGHT

14.8 lbs

INTERPRETED BY

Eric Lindquist, DMV
DABVP, Cert. IVUSS

IMAGING PERFORMED BY

Kathleen Laux

HOSPITAL NAME

Rondout Valley VA

REFERRING VET

Dr. Laux

INVOICE

77848

DATE

5/21/26

The information and recommendations provided are based on the images presented by the referring veterinarian/sonographer. No evaluation can be communicated regarding pathology that was not visible in the image/video clips provided.

Thank you for this referral. If the clinical or image interpretation does not parallel your findings or if I can be of any further assistance please contact me.

Eric Lindquist, DMV, DABVP (CFM), Cert. IVUSS, CEO of SonoPath.com

info@SonoPath.com