

PATIENT

Jojo Shufeldt

SPECIES

Canine

BREED

Chihuahua

SEX

Spayed female

AGE

7 years

WEIGHT

4.6 lbs

INTERPRETED BY

Eric Lindquist, DMV
DABVP, Cert. IVUSS

IMAGING PERFORMED BY

Kathleen Laux

HOSPITAL NAME

Rondout Valley VA

REFERRING VET

Dr. Laux

INVOICE

77849

DATE

5/21/26

PRESENTING CLINICAL SIGNS

History: -recheck on gallbladder growth
-dog has no clinical signs currently

ULTRASONOGRAPHIC EXAMINATION

Liver

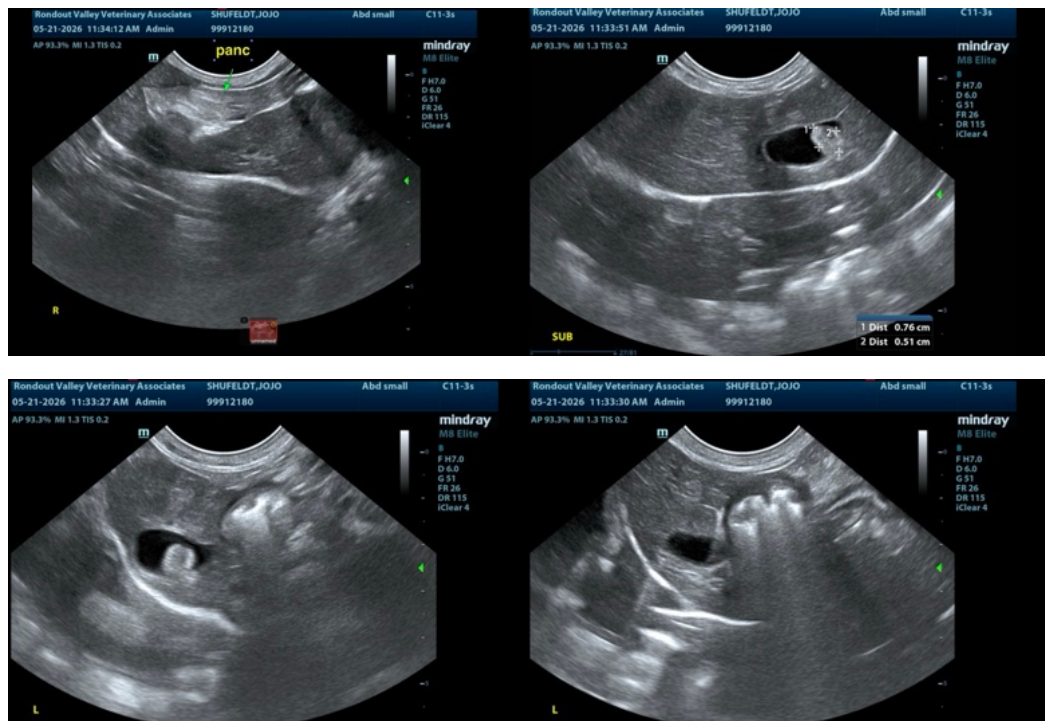
The **liver** images submitted revealed subjectively normal liver size, contour, and structure. Parenchymal echogenicity was naturally coarse and hypoechoic to the spleen. Vascular and biliary tracts were of normal volume with no evidence of congestion. A gallbladder polyp was persistent present and was echogenic and sessile. The polyp measured 0.76 x 0.51 cm. There was no progression from prior sonogram.

ULTRASONOGRAPHIC FINDINGS

Persistent gallbladder polyp, stable.

INTERPRETATION OF THE FINDINGS & FURTHER RECOMMENDATIONS

There was no evidence of biliary pathology. This is not a clinical issue at this time.



The information and recommendations provided are based on the images presented by the



PATIENT

Jojo Shufeldt

SPECIES

Canine

BREED

Chihuahua

SEX

Spayed female

AGE

7 years

WEIGHT

4.6 lbs

INTERPRETED BY

Eric Lindquist, DMV
DABVP, Cert. IVUSS

IMAGING PERFORMED BY

Kathleen Laux

HOSPITAL NAME

Rondout ValleyVA

REFERRING VET

Dr. Laux

INVOICE

77849

DATE

5/21/26

referring veterinarian/sonographer. No evaluation can be communicated regarding pathology that was not visible in the image/video clips provided.

Thank you for this referral. If the clinical or image interpretation does not parallel your findings or if I can be of any further assistance please contact me.

Eric Lindquist, DMV, DABVP (CFM), Cert. IVUSS, CEO of SonoPath.com

info@SonoPath.com