



## PATIENT

Canicas Balderrama

## SPECIES

Canine

## BREED

Chihuahua

## SEX

Neutered male

## AGE

10 years

## WEIGHT

15.8 lbs

## INTERPRETED BY

Eric Lindquist, DMV  
DABVP, Cert. IVUSS

## IMAGING PERFORMED BY

Matt

## HOSPITAL NAME

TLC AH

## REFERRING VET

Dr. Bailey

## INVOICE

77859

## DATE

5/21/26

## PRESENTING CLINICAL SIGNS

History: Hypercalcemia of malignancy - need to evaluate for primary neoplastic source abdominal u/s: eval for lymphoma parathyroid scans : possible nodule

previous treatment/test/procedure

x-rays (met check) bloodwork, calcium disorders, parathyroid hormone and ionized calcium indicate hypercalcemia of malignancy (pth-rh not available due to national supply issues)

Abnormal PE/Chem/CBC/UA Results: Phosphorus 2.4 calcium 15.2 urine specific gravity 1.010 Blood/ Hemoglobin 3+ red blood cells >100 Epithelial Cells 4+ (>10)/HPF 4dx Ehrlichia spp. Positive Anaplasma spp. Positive

## ULTRASONOGRAPHIC EXAMINATION OF THE ABDOMEN

### Urinary System

The **urinary bladder**, trigone, and pelvic urethra presented normal thicknesses and normal tone. The ureters were not visible which is normal. No uroliths or sediment were visualized and anechoic urine was present. No evidence of inflammatory or neoplastic changes was noted. Ureteral papillae were normal.

The **kidneys** revealed normal size and structure, corticomedullary definition and ratio for this age. The cortices presented largely uniform texture with normal echogenic relationship to liver and spleen. Medullary structure differed distinctly from the cortex and no evidence of pelvic dilation was present. The capsules were acceptably uniform without significant irregularities. The left kidney measured 3.84 cm. The right kidney measured 4.14 cm.

The iliac lymph nodes were enlarged, hypoechoic and irregular measuring up to 4.5 x 2.3 cm. Multiple lymph nodes were involved.

### Adrenal Glands

Both **adrenal glands** were visualized and recognized as having normal shape, size, position and echogenicity for this breed. The phrenic vasculature, glandular echogenicity and detail were unremarkable. Capsule, cortex, and medullary definition were normal for this age patient. The left adrenal gland measured 0.51 cm at the cranial pole and 0.57 cm at the caudal pole. The right adrenal gland measured 0.45 cm at the cranial pole and 0.42 cm at the caudal pole.

### Spleen

The **spleen** presented a smooth homogeneous parenchyma hyperechoic to liver and renal cortical parenchyma. The capsule was smooth without noticeable expansion or deviation from within the spleen or adjacent pathology. The splenic vasculature demonstrated normal volume without signs of congestion or thrombosis. No sonographic evidence of acute or chronic inflammatory, neoplastic, or infarctual changes was noted.



## PATIENT

Canicas Balderrama

## SPECIES

Canine

## BREED

Chihuahua

## SEX

Neutered male

## AGE

10 years

## WEIGHT

15.8 lbs

## INTERPRETED BY

Eric Lindquist, DMV  
DABVP, Cert. IVUSS

## IMAGING PERFORMED BY

Matt

## HOSPITAL NAME

TLC AH

## REFERRING VET

Dr. Bailey

## INVOICE

77859

## DATE

5/21/26

## Liver

The **liver** images submitted revealed subjectively normal liver size, contour, and structure. Parenchymal echogenicity was naturally coarse and hypoechoic to the spleen. Vascular and biliary tracts were of normal volume with no evidence of congestion. The gallbladder presented acceptably thin walls with primarily anechoic content. The cystic and common bile ducts were normal. No pathological hepatic lymphadenopathy was evident. No overt structural evidence of inflammatory, infiltrative or regenerative pathology was evident.

## Gastrointestinal

Examination of the **gastrointestinal tract** revealed a stomach and intestine free of stasis, of normal wall thickness, acceptable curvilinear mural detail, and peristaltic activity. Small and large intestine demonstrated normal luminal chyme and stool consistency respectively. No obstructive or overt infiltrative disease was noted. No associated abnormal lymphatic activity was noted.

## Pancreas

The base and limbs of the **pancreas** were observed to be largely isoechoic to surrounding omental fat. Pancreatic duct and capsular contour were acceptably normal and parenchyma respected normal curvilinear patterns. No overt evidence of active inflammatory or neoplastic disease was noted.

## Thyroid

The thyroid lobes were imaged in this patient. The left thyroid lobe was unremarkable and uniform. The right thyroid lobe revealed a hypoechoic nodule which may or may not be related to the hypercalcemia.

## ULTRASONOGRAPHIC FINDINGS

Nodular right thyroid lobe. Hyperplasia versus primary adenoma. Uniform left thyroid lobe.

Enlarged, hypoechoic and irregular anal gland.

## INTERPRETATION OF THE FINDINGS & FURTHER RECOMMENDATIONS

Anal gland palpation is recommended to assess for primary disease that may be playing a role and metastatic to the lymph nodes. FNA of the lymph nodes are indicated to confirm malignancy. Primary neoplasia such as lymphoma or metastatic disease from anal gland carcinoma are primary concerns.

Based on hypercalcemia panel, if hypercalcemia and malignancy is a primary concern, then I recommend focusing on the iliac lymph nodes and potential imaging of the anal glands. Chest radiographs are warranted to assess for metastatic disease are indicated.



## PATIENT

Canicas Balderrama

## SPECIES

Canine

## BREED

Chihuahua

## SEX

Neutered male

## AGE

10 years

## WEIGHT

15.8 lbs

## INTERPRETED BY

Eric Lindquist, DMV  
DABVP, Cert. IVUSS

## IMAGING PERFORMED BY

Matt

## HOSPITAL NAME

TLC AH

## REFERRING VET

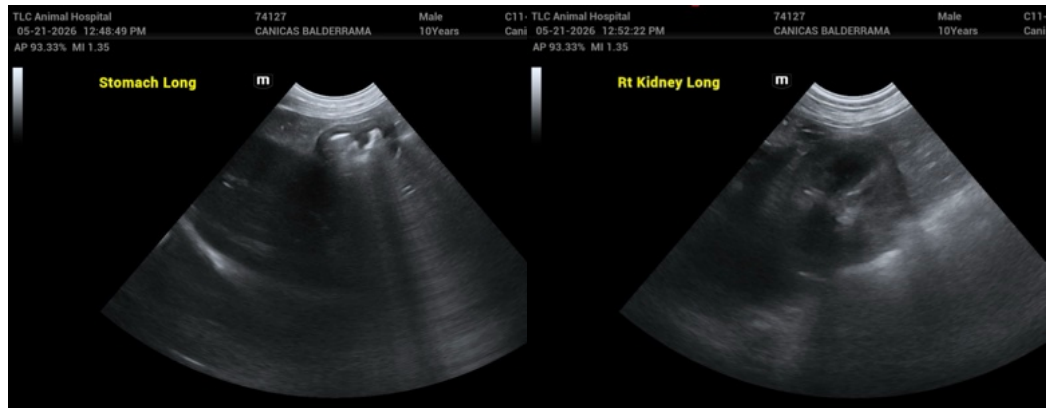
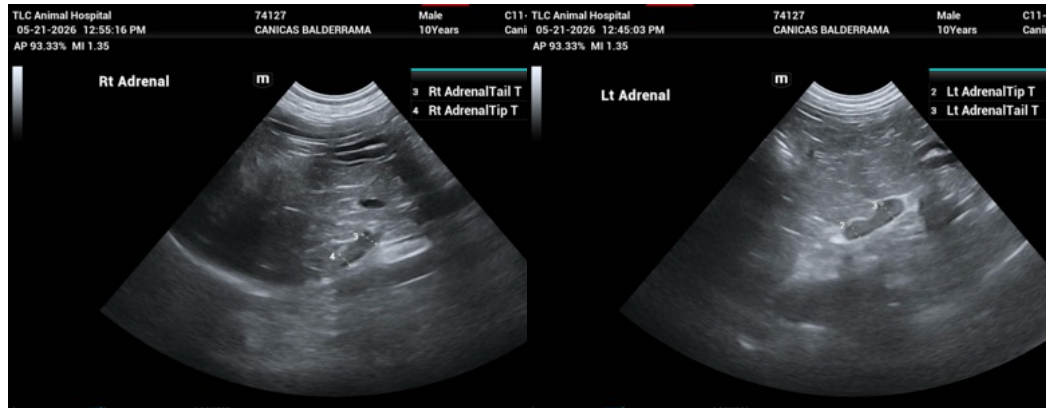
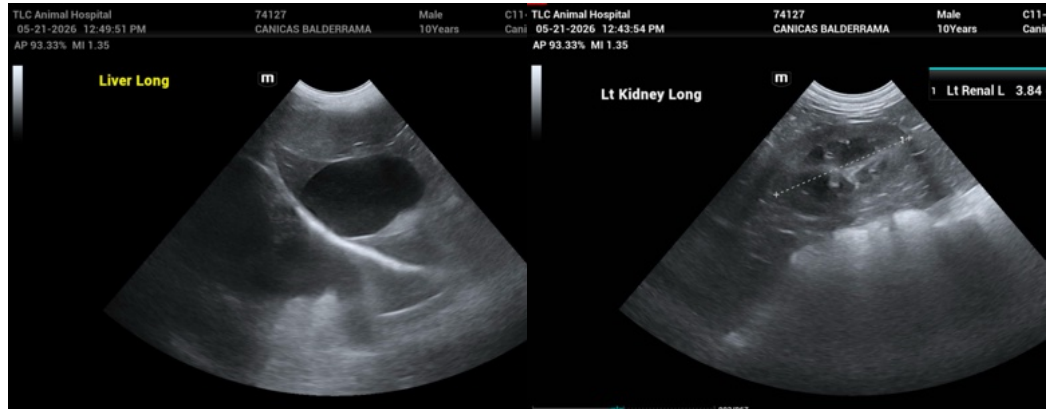
Dr. Bailey

## INVOICE

77859

## DATE

5/21/26





**PATIENT**

Canicas Balderrama

**SPECIES**

Canine

**BREED**

Chihuahua

**SEX**

Neutered male

**AGE**

10 years

**WEIGHT**

15.8 lbs

**INTERPRETED BY**

Eric Lindquist, DMV  
DABVP, Cert. IVUSS

**IMAGING PERFORMED BY**

Matt

**HOSPITAL NAME**

TLC AH

**REFERRING VET**

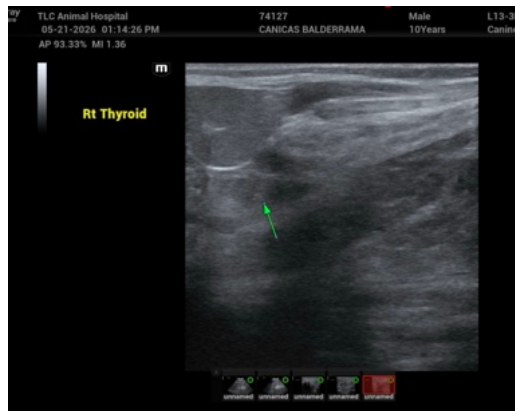
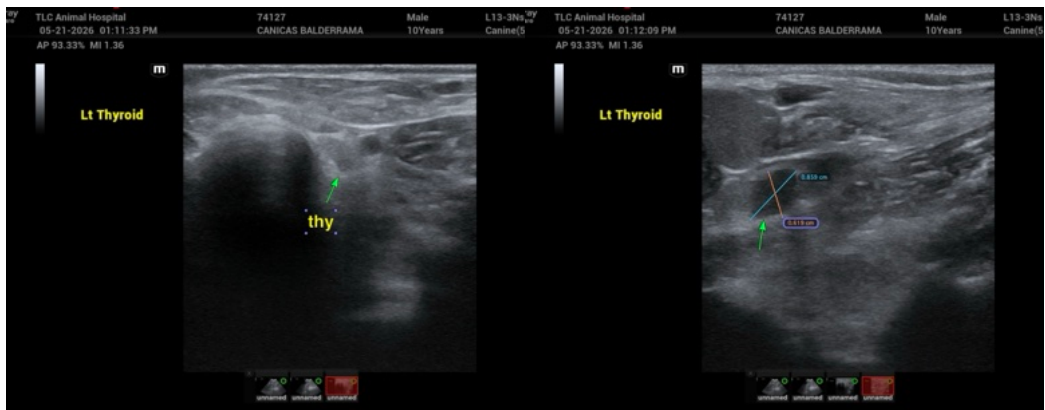
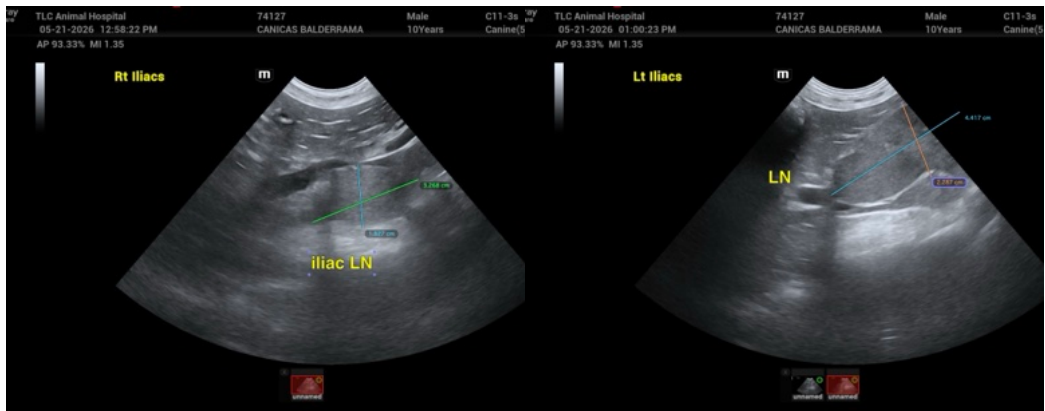
Dr. Bailey

**INVOICE**

77859

**DATE**

5/21/26



The information and recommendations provided are based on the images presented by the referring veterinarian/sonographer. No evaluation can be communicated regarding pathology that was not visible in the image/video clips provided.

Thank you for this referral. If the clinical or image interpretation does not parallel your findings or if I can be of any further assistance please contact me.

Eric Lindquist, DMV, DABVP (CFM), Cert. IVUSS, CEO of SonoPath.com

[info@SonoPath.com](mailto:info@SonoPath.com)



## CANINE HYPERCALCEMIA

<http://www.sonopath.com/CanineHypercalcemia>

### PATIENT

Canicas Balderrama

### SPECIES

Canine

### BREED

Chihuahua

### SEX

Neutered male

### AGE

10 years

### WEIGHT

15.8 lbs

### INTERPRETED BY

Eric Lindquist, DMV  
DABVP, Cert. IVUSS

### IMAGING PERFORMED BY

Matt

### HOSPITAL NAME

TLC AH

### REFERRING VET

Dr. Bailey

### INVOICE

77859

### DATE

5/21/26

**Description:** Hypercalcemia is defined as either a persistently elevated total calcium serum (> 12 mg/dl) or ionized calcium (> 1.45 mmol/l) concentration. Clinical signs are often absent with mild hypercalcemia (< 13 mg/dl). In fact, hypercalcemia is often only discovered when serum biochemistry is done for unrelated reasons. Clinical signs are usually mild when the serum calcium concentration is less than 14 mg/dl; however, signs become more readily apparent when the concentration exceeds 15 mg/dl. Life-threatening cardiac arrhythmias can develop when the serum calcium exceeds 18 mg/dl.

Common etiologies of hypercalcemia include humoral hypercalcemia of malignancy (HHM), hypoadrenocorticism, chronic kidney disease (CKD), hypervitaminosis D, and primary hyperparathyroidism. Less common etiologies include bone neoplasia, osteomyelitis, hypertrophic osteodystrophy, granulomatous disease, calcium supplementation, and oral phosphate binders.

**Clinical Signs:** Common clinical signs include polyuria, polydipsia, lethargy, inappetence, and weakness. With chronic hypercalcemia, calcium oxalate and calcium phosphate uroliths can form, resulting in clinical signs suggestive of lower urinary tract disease. Systemic signs of illness are suggestive of HHM.

**Diagnostics:** One important etiology of hypercalcemia is laboratory error; therefore, hypercalcemia should always be confirmed before embarking on any further diagnostic evaluation. Results of a CBC, serum biochemistry panel, and urinalysis, in conjunction with a patient history and findings from a physical examination, can often provide enough information to arrive at a diagnosis. The appendicular skeleton, peripheral lymph nodes, abdominal cavity, and rectum should all be carefully palpated for masses, lymphadenopathy, hepatomegaly, splenomegaly, and/or pain in the long bones. The following diagnostic tests are helpful for identifying an underlying malignancy: thoracic and abdominal radiographs; abdominal ultrasound; cytological evaluation of aspirates of the liver, spleen, lymph nodes, and bone marrow; determination of serum ionized calcium, parathyroid hormone (PTH), and parathyroid hormone-related protein concentration (PTHrP); and ultrasound of the neck. Ascertaining the concentrations of serum ionized calcium, PTH, and PTHrP helps differentiate primary hyperparathyroidism from HHM. The finding of one or more enlarged parathyroid glands upon conducting an ultrasound of the neck supports a diagnosis of primary hyperparathyroidism.

Hypoadrenocorticism-induced hypercalcemia usually occurs in conjunction with hyponatremia, hyperkalemia, and prerenal azotemia. With HHM and primary hyperparathyroidism, serum phosphorus concentration is often in the low to low-normal reference range. If the serum phosphorus concentration is high but kidney function is normal, hypervitaminosis D or osteolysis should be suspected.

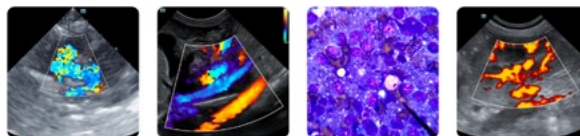
It can be difficult to determine whether kidney failure is primary or secondary to hypercalcemia when hyperphosphatemia and hypercalcemia coexist with azotemia. Serum ionized calcium concentrations are typically normal or decreased in cases of renal failure and increased in cases of hypercalcemia caused by other disorders.



<b>PATIENT</b>	
Canicas Balderrama	
<b>SPECIES</b>	
Canine	
<b>BREED</b>	
Chihuahua	
<b>SEX</b>	
Neutered male	
<b>AGE</b>	
10 years	
<b>WEIGHT</b>	
15.8 lbs	
<b>INTERPRETED BY</b>	
Eric Lindquist, DMV DABVP, Cert. IVUSS	
<b>IMAGING PERFORMED BY</b>	
Matt	
<b>HOSPITAL NAME</b>	
TLC AH	
<b>REFERRING VET</b>	
Dr. Bailey	
<b>INVOICE</b>	
77859	
<b>DATE</b>	
5/21/26	

<p>Sternal and hilar lymphadenopathy is common with lymphoma-induced hypercalcemia and can be readily identified on thoracic radiographs. In cases of multiple myeloma, discrete lytic lesions in the vertebrae or long bones, hyperproteinemia, proteinuria, and plasma cell infiltration in the bone marrow may be present. Cytological evaluation of the peripheral lymph nodes, bone marrow, and spleen can be helpful in identifying lymphoma.</p> <p>Increased serum ionized calcium concentrations, detectable serum PTHrP concentrations, and non-detectable serum PTH concentrations are all diagnostic for HHM. Lymphoma is the most common etiology of HHM, but other tumors, such as apocrine gland adenocarcinoma and various carcinomas (e.g. mammary gland, squamous cell, bronchogenic), can all give rise to hypercalcemia. Increased serum ionized calcium, normal to increased serum PTH, and non-detectable PTHrP concentrations are diagnostic of primary hyperparathyroidism.</p> <p><b><u>Differentials for Hypercalcemia: "HARD IONS"</u></b></p> <ul style="list-style-type: none"> <li>Hyperparathyroid</li> <li>Addison's</li> <li>Renal</li> <li>D-toxicity</li> <li>Idiopathic</li> <li>Osteolytic</li> <li>Neoplastic</li> <li>Spurious</li> </ul> <p><b>PTH tumor:</b> Elevated total and ionized Ca, low PTHrP, and normal/high PTH. Keeshonds, German Shepherds, and Golden Retrievers are all predisposed.</p> <p><b>Addison's disease:</b> Elevated total and normal ionized Ca, elevated BUN, hypoalbuminemia and hyperkalemia.</p> <p><b>Renal failure:</b> Elevated to normal total Ca, low ionized Ca, low PTHrP, elevated PTH, azotemia, and low urine specific gravity.</p> <p><b>Vitamin D toxicity:</b> Elevated total and ionized Ca, low PTHrP, and normal/low PTH.</p> <p><b>Hypercalcemia of malignancy (HHM):</b> Elevated total and ionized Ca, high PTHrP, and low PTH.</p> <p><b>Granulomatous disease:</b> Elevated total and ionized Ca, low PTHrP, and low PTH.</p> <p><b>Renal failure:</b> Elevated to normal total Ca, low ionized Ca, low PTHrP, elevated PTH, azotemia, and low urine specific gravity.</p> <p><b>Treatment:</b> Therapies for hypercalcemia are aimed at correcting the underlying etiology; however, because prolonged hypercalcemia can result in kidney damage, the use of fluid therapy, furosemide, and possibly</p>	
-------------------------------------------------------------------------------------------------------------------------------------------------------------------------------------------------------------------------------------------------------------------------------------------------------------------------------------------------------------------------------------------------------------------------------------------------------------------------------------------------------------------------------------------------------------------------------------------------------------------------------------------------------------------------------------------------------------------------------------------------------------------------------------------------------------------------------------------------------------------------------------------------------------------------------------------------------------------------------------------------------------------------------------------------------------------------------------------------------------------------------------------------------------------------------------------------------------------------------------------------------------------------------------------------------------------------------------------------------------------------------------------------------------------------------------------------------------------------------------------------------------------------------------------------------------------------------------------------------------------------------------------------------------------------------------------------------------------------------------------------------------------------------------------------------------------------------------------------------------------------------------------------------------------------------------------------------------------------------------------------------------------------------------------------------------------------------------------------------------------------------------------------------------------------------------------------------------------------------------------------------------------------------------------------------------------------------------------------------------------------------------------------------	--



## PATIENT

Canicas Balderrama

## SPECIES

Canine

## BREED

Chihuahua

## SEX

Neutered male

## AGE

10 years

## WEIGHT

15.8 lbs

## INTERPRETED BY

Eric Lindquist, DMV  
DABVP, Cert. IVUSS

## IMAGING PERFORMED BY

Matt

## HOSPITAL NAME

TLC AH

## REFERRING VET

Dr. Bailey

## INVOICE

77859

## DATE

5/21/26

prednisone is indicated in all cases to reduce serum calcium levels. Suggested dosages include saline (0.9% 120-180 ml/kg day IV), furosemide (1-4 mg/kg PO TID), and prednisone (0.25 mg/kg PO Q24hr).

## References:

Chew DJ, Schenck PA, Jaege JQ. Clinical disorders of hypercalcemia and hypocalcemia in dogs and cats. Proceedings from the American College of Veterinary Internal Medicine, Charlotte, NC, June 4-7, 2003.

Feldman EC. Disorders of the parathyroid glands. In: Ettinger SJ, Feldman EC, ed. *Textbook of Veterinary Internal Medicine, 7th ed.* St. Louis, MO: Saunders Elsevier; 2010:1722-50.

Peterson ME. Hypercalcemia in dogs & cats: differential diagnosis & treatment. Proceedings from the Western Veterinary Conference, Las Vegas, NV, February 19-23, 2012.