



PATIENT

Brandy Scoggin

SPECIES

Canine

BREED

Boxer Mix

SEX

Spayed Female

AGE

4 Years 8 Months

WEIGHT

70.4 lbs

INTERPRETED BY

Eric Lindquist, DMV,
DABVP(CFM), Cert.
IVUSS

IMAGING PERFORMED BY

Leon Anderson, DVM

HOSPITAL NAME

Elizabeth Animal
Hospital

REFERRING VET

Dr. Jen Redus, DVM

INVOICE

16403

DATE

05/21/26

PRESENTING CLINICAL SIGNS

Looking for cause of symptoms and fever. 2 day history of lethargy, reluctance to get up, decreased appetite and drinking, on long term Apoquel. X-rays of chest pending

PE: T- 104.6F, Typical signs of managed atopy Labs: Today CBC- RDW 23.3%, Lym 500 /uL, Eos 0 Chem- Chlor 107 mmol/L, Globulin 4.7 g/dL, ALP 223 U/L UA- usg 1.042, pH 8, clear sediment Cortisol- 2.77 ug/dL

ULTRASONOGRAPHIC EXAMINATION OF THE ABDOMEN

Urinary System

The **urinary bladder**, trigone, and pelvic urethra to a depth of 2.0 cm presented normal thicknesses and normal tone. The ureters were not visible which is normal. No uroliths or sediment were visualized, and anechoic urine was present. No evidence of inflammatory or neoplastic changes were noted. Ureteral papillae were normal.

The **kidneys** revealed normal size and structure, corticomedullary definition and ratio for this age. The cortices presented largely uniform texture with normal echogenic relationship to liver and spleen. Medullary structure differed distinctly from the cortex and no evidence of pelvic dilation was present. The capsules were acceptably uniform without significant irregularities. The left kidney measured 7.0 cm in length. The right kidney measured 6.3 cm in length.

Adrenal Glands

Both **adrenal glands** were visualized and recognized as having normal shape, size, position and echogenicity for this breed. The phrenic vasculature, glandular echogenicity and detail were unremarkable. Capsule, cortex, and medullary definition were normal for this age patient. The left adrenal gland measured 2.77 cm x 0.43 cm width at the caudal pole and 0.53 cm width at the cranial pole. The right adrenal gland measured 3.08 cm x 0.7 cm width at the cranial pole and 0.5 cm width at the caudal pole.

Spleen

The **spleen** presented a smooth homogeneous parenchyma hyperechoic to liver and renal cortical parenchyma. The capsule was smooth without noticeable expansion or deviation from within the spleen or adjacent pathology. The splenic vasculature demonstrated normal volume without signs of congestion or thrombosis. No sonographic evidence of acute or chronic inflammatory, neoplastic, or infarctual changes were noted.

Liver

The **liver** images submitted revealed subjectively normal liver size, contour, and structure. Parenchymal echogenicity was naturally coarse and hypoechoic to the spleen. Vascular and biliary tracts were of normal volume with no evidence of congestion. The gallbladder presented acceptably thin walls with primarily anechoic content. The cystic and common bile ducts were normal. No pathological hepatic lymphadenopathy was evident. No overt structural evidence of inflammatory, infiltrative or regenerative pathology was evident.

Gastrointestinal



PATIENT

Brandy Scoggin

SPECIES

Canine

BREED

Boxer Mix

SEX

Spayed Female

AGE

4 Years 8 Months

WEIGHT

70.4 lbs

INTERPRETED BY

Eric Lindquist, DMV,
DABVP(CFM), Cert.
IVUSS

IMAGING PERFORMED BY

Leon Anderson, DVM

HOSPITAL NAME

Elizabeth Animal
Hospital

REFERRING VET

Dr. Jen Redus, DVM

INVOICE

16403

DATE

05/21/26

Examination of the **gastrointestinal tract** revealed a stomach and intestine free of stasis, of normal wall thickness, acceptable curvilinear mural detail, and peristaltic activity. Small and large intestine demonstrated normal luminal chyme and stool consistency respectively. No obstructive or overt infiltrative disease was noted. No associated abnormal lymphatic activity was noted.

Pancreas

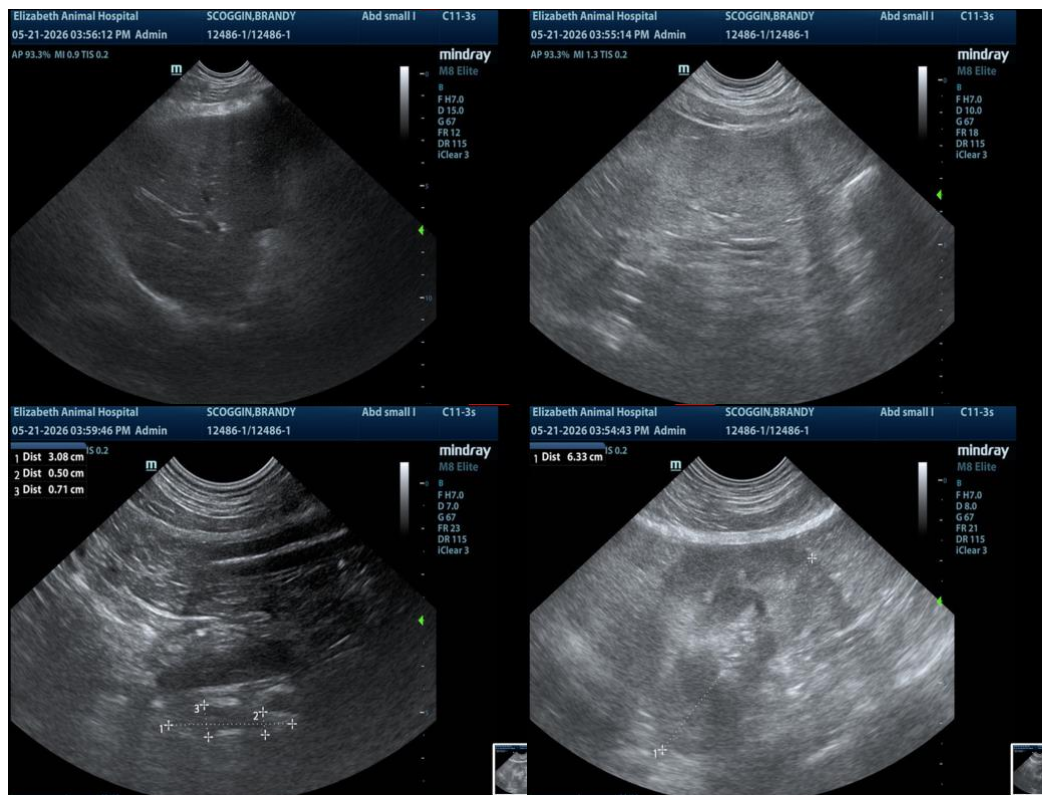
The base and limbs of the **pancreas** were observed to be largely isoechoic to surrounding omental fat. Pancreatic duct and capsular contour were acceptably normal and parenchyma respected normal curvilinear patterns. No overt evidence of active inflammatory or neoplastic disease was noted.

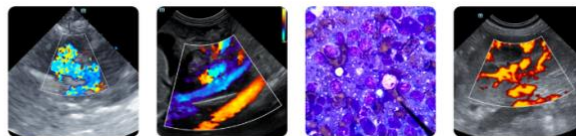
ULTRASONOGRAPHIC FINDINGS

- Structurally unremarkable abdomen.

INTERPRETATION OF THE FINDINGS & FURTHER RECOMMENDATIONS

Infectious agents such as Bartonella and tick-borne disease should be considered. No evidence of visceral disease directly related to the clinical history.





PATIENT

Brandy Scoggin

SPECIES

Canine

BREED

Boxer Mix

SEX

Spayed Female

AGE

4 Years 8 Months

WEIGHT

70.4 lbs

INTERPRETED BY

Eric Lindquist, DMV,
DABVP(CFM), Cert.
IVUSS

IMAGING PERFORMED BY

Leon Anderson, DVM

HOSPITAL NAME

Elizabeth Animal
Hospital

REFERRING VET

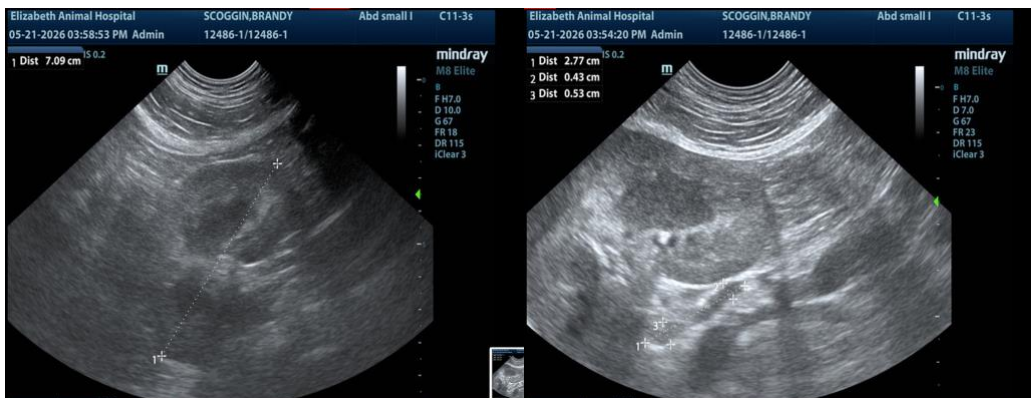
Dr. Jen Redus, DVM

INVOICE

16403

DATE

05/21/26



The information and recommendations provided are based on the images presented by the referring veterinarian/sonographer. No evaluation can be communicated regarding pathology that was not visible in the image/video clips provided.

Thank you for this referral. If the clinical or image interpretation does not parallel your findings or if I can be of any further assistance, please contact me.

Eric Lindquist, DMV, DABVP(CFM), Cert. IVUSS,

CEO, Owner, Founder -- SonoPath.com

info@SonoPath.com

FEVER OF UNKNOWN ORIGIN

DESCRIPTON Fever of unknown origin (FUO) is any fever greater than a few days duration in which the cause is not obvious on initial history and physical examination. Important etiologies are infectious disease, immune-mediated diseases, and neoplasia. The common causes of FUO were summarized concisely in a presentation at the American College of Veterinary Internal Medicine 2004 Forum as follows:

Final Diagnosis	Bennett (Dogs & Cats)	Dunn and Dunn (Dogs Only)	Lunn (Dogs & 1 cat)	Total	Percent
Infection	21	16	10	47	28
Immune	18	22	6	46	27
Bone Marrow Disease	4	22	2	28	16
Neoplasia (outside marrow)	0	10	2	12	7
Miscellaneous	2	12	2	16	9
No Diagnosis	0	19	2	21	12
TOTALS	45	101	24	170	99

The types of infection diagnosed in this case series were varied, ranging from discospondylitis (8 cases), blastomycosis (6 cases), and bacterial endocarditis (4 cases), to leishmaniasis (1 case), prostatitis (1 case),



PATIENT

Brandy Scoggin

SPECIES

Canine

BREED

Boxer Mix

SEX

Spayed Female

AGE

4 Years 8 Months

WEIGHT

70.4 lbs

INTERPRETED BY

Eric Lindquist, DMV,
DABVP(CFM), Cert.
IVUSS

IMAGING PERFORMED BY

Leon Anderson, DVM

HOSPITAL NAME

Elizabeth Animal
Hospital

REFERRING VET

Dr. Jen Redus, DVM

INVOICE

16403

DATE

05/21/26

and Ehrlichia canis infection (1 case); a multitude of other infectious causes also fell within the spectrum. Of the cases where immune-mediated disease was found, 44% had immune-mediated polyarthritis. Bone marrow diseases included myeloproliferative disease, myelodysplasia (8 cases), lymphocytic leukemia (8 cases), myeloma (3 cases), chronic granulocytic leukemia (3 cases), lymphoblastic leukemia, and malignant histiocytosis. The types of neoplasia located outside the bone marrow included lymphoma (6 cases), metastatic disease (2 cases), and neoplasms of the lung, spleen, and stomach. Finally, miscellaneous diseases included hypertrophic osteodystrophy (6 cases), meningitis (3 cases), portosystemic shunt (3 cases), lymphadenitis (2 cases), panosteitis, and intervertebral disc disease. Overall, the most common causes across all cases were polyarthritis (44 cases), lymphoid neoplasia (15 cases), discospondylitis (8 cases), myelodysplasia (8 cases), hypertrophic osteodystrophy (6 cases), and blastomycosis (6 cases).

CLINICAL SIGNS Animals usually present with either persistent or waxing and waning fevers ranging from 103–106 °F (39.5–41 °C). Other clinical signs depend on the underlying cause of the fever. Careful and thorough physical examination is required to assess potential causes. History and physical examination represent the first, best, and least expensive opportunity to localize the disease process causing the fever.

DIAGNOSTICS FUO etiologies are partly related to geography and thus, locale or travel history should factor into a practitioner's diagnostic approach. A patient's lifestyle may also provide clues regarding exposure to certain etiologic agents. Therefore, obtaining a thorough history can unveil important pieces of the diagnostic puzzle. Physical examination is especially important and should include an inspection of all accessible lymph nodes, palpation and movement of the joints, a fundic examination, a neurological evaluation, spinal and limb palpation and range of motion tests, and a rectal examination.

A minimum database should include a CBC reviewed by a clinical pathologist, as well as a biochemical profile and urinalysis and retroviral testing in cats. In areas where tick-borne disease is prevalent, in-house testing should be performed early. Advanced laboratory work can include urine culture, blood culture, and infectious disease panels (PCR and/or serology). In dogs, one may screen for the following infectious agents: Ehrlichia spp., Borrelia burgdorferi, Rocky Mountain Spotted Fever, Bartonella spp. (culture and PCR), and Leptospira spp. in cases of hepatic or renal involvement. In cats, one should evaluate for FeLV, FIV, feline infectious peritonitis (FIP) virus, toxoplasmosis, Hemoplasma spp. (Mycoplasma), and Bartonella spp. (culture and PCR). Testing for Ehrlichia spp., Rickettsia spp., and Anaplasma phagocytophilum can also be considered. A fungal assay is indicated if the patient lives in or has had exposure to a region with a higher incidence of fungal disease. Other infectious disease tests may be performed depending on the geographical location of the pet. Screening for Brucella should be done in breeding dogs. Immune-mediated disease screening can include a Coombs test, a slide agglutination test (if the patient is anemic), and an antinuclear antibody (ANA) test. Immune disease is often a diagnosis of exclusion.

Imaging should include thoracic radiographs, abdominal ultrasound, and/or abdominal radiographs. Ultrasound can be very useful for assessing evidence of cholangiohepatitis, pyelonephritis, chronic urinary tract infection, abscess formation, peritonitis, and neoplasia. It also permits an examination of the intra-abdominal lymph nodes. An echocardiogram can offer assessment for vegetative endocarditis, whereas spinal radiographs offer assessment for discospondylitis. In cases where all other testing has proven negative and the patient has not responded to broad-spectrum antibiotics and supportive care, arthrocentesis should be considered to evaluate for septic joint disease, immune-mediated polyarthritis, and infectious disease. Finally, one can consider assessing the cerebrospinal fluid for meningoencephalitis, GME, and meningitis/arteritis. A bone marrow exam should be performed if blood dyscrasias are noted on the CBC.

TREATMENT Treatment of the fever depends entirely on the underlying cause. Ideally, a thorough diagnostic plan will yield a diagnosis that will guide the appropriate therapeutic course. However, if an exhaustive approach has not produced a definitive diagnosis and there is no response to broad-spectrum antibiotics, trial therapy with immunosuppressive agents such as prednisolone can be considered to treat presumed immune-mediated diseases. Given the potential for negative sequelae should an underlying



PATIENT

Brandy Scoggin

SPECIES

Canine

BREED

Boxer Mix

SEX

Spayed Female

AGE

4 Years 8 Months

WEIGHT

70.4 lbs

INTERPRETED BY

Eric Lindquist, DMV,
DABVP(CFM), Cert.
IVUSS

IMAGING PERFORMED BY

Leon Anderson, DVM

HOSPITAL NAME

Elizabeth Animal
Hospital

REFERRING VET

Dr. Jen Redus, DVM

INVOICE

16403

DATE

05/21/26

infection be present, one must be certain that the investigation is thorough and monitor the patient's response carefully.

CONCLUSION If a documented fever has not responded to antibiotics, antipyretics, or general nursing care, it is important to obtain a diagnosis to guide more specific treatment. A systematic physical examination and thorough history-taking will help inform further diagnostics in addition to what is revealed by the minimum database.

REFERENCES

1. Battersby IA, Murphy KF, et al. Retrospective study of fever in dogs: laboratory testing, diagnoses and influence of prior treatment. *J Small Anim Pract.* 2006; 47: 370-376.
2. Flood J. The diagnostic approach to fever of unknown origin in cats. *Compend Contin Educ Vet* 2009; 31 (1): 26-31.
3. Flood J. The diagnostic approach to fever of unknown origin in dogs. *Compend Contin Educ Vet* 2009; 31 (1): 14-21.
4. Lappin MR. The role of blood borne pathogens in feline fever of unknown origin. *Proceed-ings from the American College of Veterinary Internal Medicine, Denver, CO, June 15-18, 2011.*
5. Lunn KF. Fever of unknown origin: a systematic approach to diagnosis. *Compend Contin Educ Vet* 2001; 23 (11): 976-92.
6. Lunn KF. Fever of unknown origin: appropriate choice of diagnostic tests. *Proceedings from the American College of Veterinary Internal Medicine, Minneapolis, MN, June 9-12, 2004.*