

PATIENT

Valentine Goldstein

SPECIES

Feline

BREED

Domestic Shorthair

SEX

Spayed female

AGE

15 years

WEIGHT

12.2 lbs

INTERPRETED BY

Eric Lindquist, DMV
DABVP, Cert. IVUSS

IMAGING PERFORMED BY

Dr. Klein

HOSPITAL NAME

Alison AH

REFERRING VET

Dr. Klein

INVOICE

77770

DATE

5/20/26

PRESENTING CLINICAL SIGNS

History: Pt is presented for a cardiac scan due to an elevated BNP (669 pmol/L {WNL<100 pmol/L}). Pt has a normal decrease in energy for species and age. No coughing, no wheezing or open mouth breathing. Main concern of O is weight loss of 5 lbs in 1 year and decreased appetite.

PRE-ANESTHETIC ECHOCARDIOGRAM

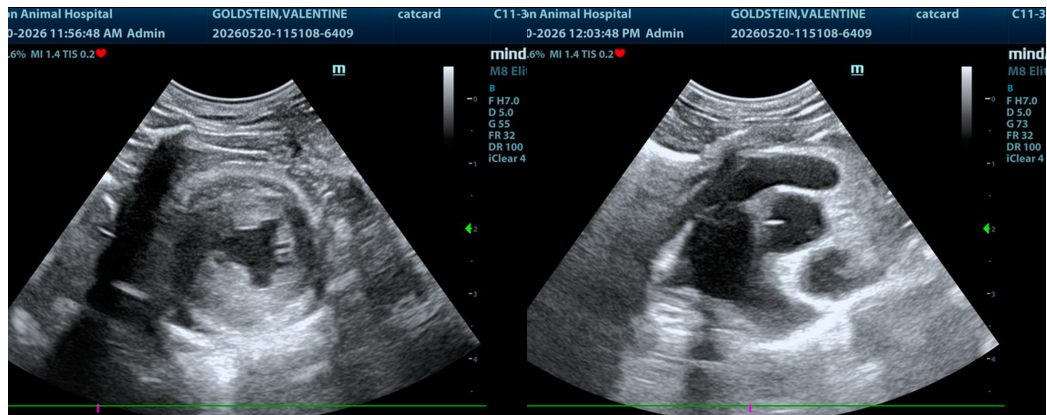
8 efficiency video clips from SDEP protocol provided.

All four chambers revealed normal volumes and contractility. Some myocardial remodeling and volume contraction noted. No pericardial or pleural effusion noted. No gross abnormalities that would preclude anesthesia.

INTERPRETATION OF THE FINDINGS & FURTHER RECOMMENDATIONS

Anesthetic risk is considered normal to mild. No gross abnormalities noted on SDEP Screening Echo to contraindicate anesthesia. Minimal to no left atrial enlargement noted on images presented.

- However, judicious fluid administration is advised with careful RR/RE monitoring to screen for fluid overload.
- Monitoring of blood pressure, SpO₂, CO₂, and auscultation of heart and lungs during anesthesia should be done during every procedure.



The information and recommendations provided are based on the images presented by the referring veterinarian/sonographer. No evaluation can be communicated regarding pathology that was not visible in the image/video clips provided.

Thank you for this referral. If the clinical or image interpretation does not parallel your findings or if I can be of any further assistance please contact me.

Eric Lindquist, DMV, DABVP (CFM), Cert. IVUSS, CEO of SonoPath.com

info@SonoPath.com