



PATIENT

Spiro Inselberg

SPECIES

Canine

BREED

American Pitbull
Terrier Mix

SEX

Neutered Male

AGE

11 Years

WEIGHT

54 lbs

INTERPRETED BY

Eric Lindquist, DMV,
DABVP(CFM), Cert.
IVUSS

IMAGING PERFORMED BY

Dr. Jeremiah Gabriel

HOSPITAL NAME

Central Jersey Animal
Hospital

REFERRING VET

Dr. Jeremiah Gabriel

INVOICE

16382

DATE

05/20/26

PRESENTING CLINICAL SIGNS

Anorexia, chronic diarrhea, pale MM

ULTRASONOGRAPHIC EXAMINATION OF THE ABDOMEN

Urinary System

The **urinary bladder** was over distended at the time of the sonogram. The trigone, and pelvic urethra presented normal thicknesses and normal tone. The ureters were not visible which is normal. No uroliths or sediment were visualized, and anechoic urine was present. No evidence of inflammatory or neoplastic changes were noted. Ureteral papillae were normal.

The **kidneys** revealed largely normal size and structure, corticomedullary definition and ratio (cortex 1/3 of medulla) were essentially maintained with some mild age-related loss of curvilinear patterns regarding the capsule and C/M junction. The cortices presented largely uniform texture with some increased echogenicity expected for his age patient. Medullary structure differed distinctly from that of the cortex and no evidence of pelvic dilation was present. The left kidney measured 6.0 cm in length. The right kidney measured 6.0 cm in length.

Adrenal Glands

Both **adrenal glands** were visualized and recognized as having normal shape, size, position and echogenicity for this breed. The phrenic vasculature, glandular echogenicity and detail were unremarkable. Capsule, cortex, and medullary definition were normal for this age patient. The left adrenal gland measured 0.5 cm width. The right adrenal gland measured 0.5 cm width.

Spleen

The **spleen** presented enlarged, irregular and folded upon itself with micronodular changes with enhanced surrounding mesentery and free fluid.

Liver

The **liver** presented swollen and irregular. Gallbladder edema was present. Increased portal markings and enlargement of the hepatic lymph nodes was noted. Subtle hypoechoic nodular changes were visualized.

Gastrointestinal

Variable **gastrointestinal** thickening was noted with areas of hypoechoic undifferentiated tissue.

Pancreas

The **pancreas** was enveloped in regional pathology.

Free Abdomen

A mild/moderate amount of **free fluid** was present within the abdomen with enhanced surrounding mesentery. The mesenteric **lymph nodes** appeared enlarged. Pleural effusion was visualized through the diaphragm. A mesenteric lymph node mass was present encompassing the mesenteric artery with enhanced surrounding mesentery. The largest lymph node measured approximately 7.0 cm x 5.0 cm.

ULTRASONOGRAPHIC FINDINGS



PATIENT

Spiro Inselberg

SPECIES

Canine

BREED

American Pitbull
Terrier Mix

SEX

Neutered Male

AGE

11 Years

WEIGHT

54 lbs

INTERPRETED BY

Eric Lindquist, DMV,
DABVP(CFM), Cert.
IVUSS

IMAGING PERFORMED BY

Dr. Jeremiah Gabriel

HOSPITAL NAME

Central Jersey Animal
Hospital

REFERRING VET

Dr. Jeremiah Gabriel

INVOICE

16382

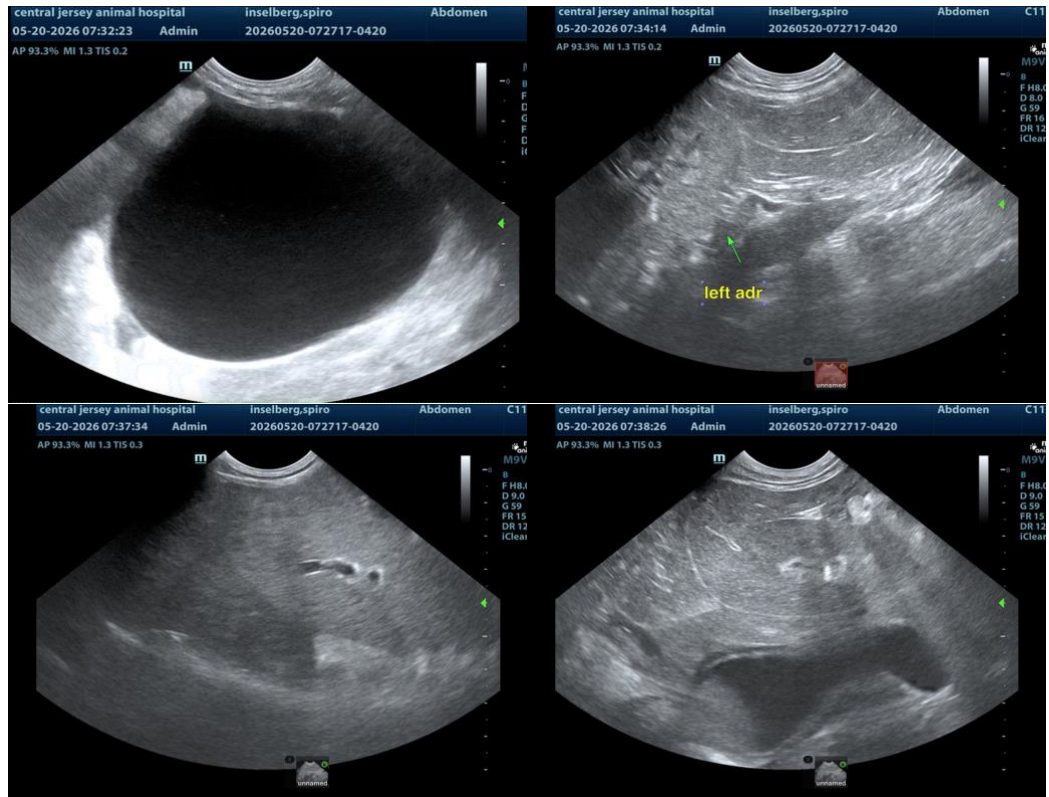
DATE

05/20/26

- Multicentric aggressive round cell neoplastic pattern- lymphomatosis type presentation.
- Age-related renal changes.

INTERPRETATION OF THE FINDINGS & FURTHER RECOMMENDATIONS

FNA of the lymph nodes, spleen and liver are all indicated for further definition, yet prognosis is poor.





PATIENT

Spiro Inselberg

SPECIES

Canine

BREED

American Pitbull
Terrier Mix

SEX

Neutered Male

AGE

11 Years

WEIGHT

54 lbs

INTERPRETED BY

Eric Lindquist, DMV,
DABVP(CFM), Cert.
IVUSS

IMAGING PERFORMED BY

Dr. Jeremiah Gabriel

HOSPITAL NAME

Central Jersey Animal
Hospital

REFERRING VET

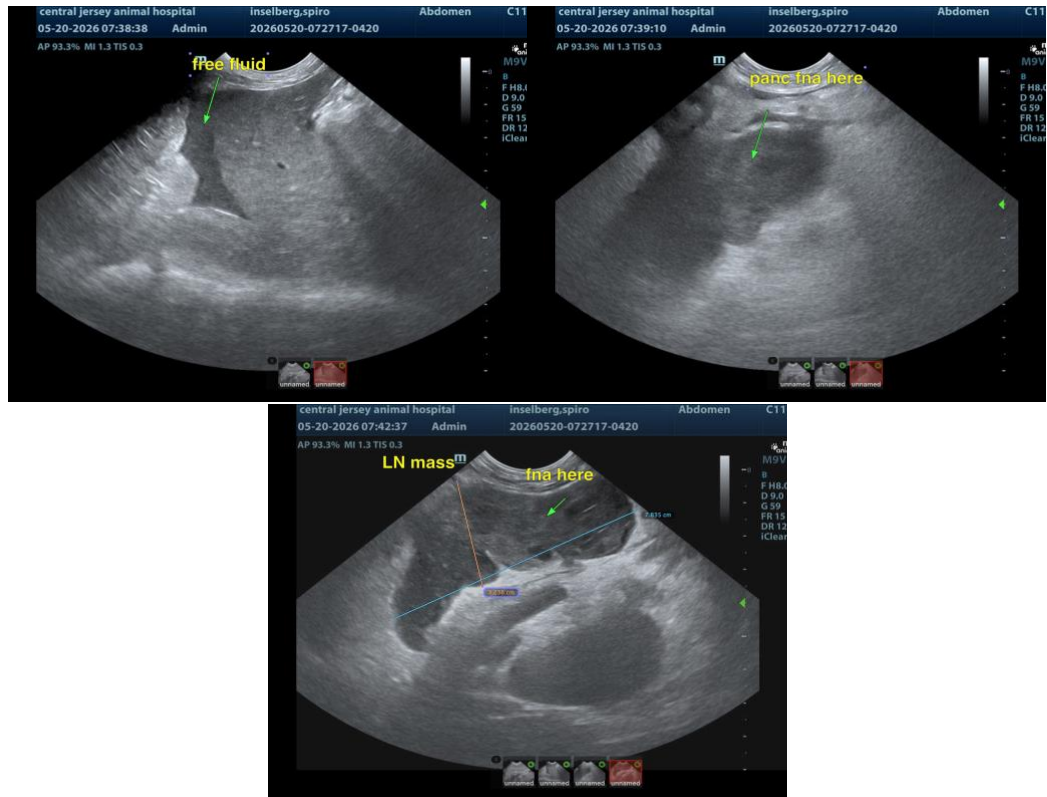
Dr. Jeremiah Gabriel

INVOICE

16382

DATE

05/20/26



The information and recommendations provided are based on the images presented by the referring veterinarian/sonographer. No evaluation can be communicated regarding pathology that was not visible in the image/video clips provided.

Thank you for this referral. If the clinical or image interpretation does not parallel your findings or if I can be of any further assistance, please contact me.

Eric Lindquist, DMV, DABVP(CFM), Cert. IVUSS,

CEO, Owner, Founder -- SonoPath.com

info@SonoPath.com