



PATIENT

Parker Barnes

SPECIES

Canine

BREED

Chihuahua x

SEX

Neutered Male

AGE

13 Years 6 Months

WEIGHT

21.7 lbs

INTERPRETED BY

Eric Lindquist, DMV,
DABVP (CFM), Cert.
IVUSS

IMAGING PERFORMED BY

Vincent Ravancho, CVT

HOSPITAL NAME

Whippany Veterinary
Hospital

REFERRING VET

Dr. Enoch

INVOICE

75296

DATE

5/20/26

PRESENTING CLINICAL SIGNS

Pre-Dental Workup. Clinical Findings - Grade 2/6 heart murmur, PU/PD and polyphagia since March. Current medications - Preventatives (Credelio and Interceptor),

Abnormal PE/Chem/CBC/UA Results: 3/6/26 - BUN 38, Creat 1.4, Phos 2.1. Rechecking labwork today.

ULTRASONOGRAPHIC EXAMINATION OF THE HEART & ABDOMEN

CANINE CARDIAC PARAMETERS	MR VMAX (m/s)	TR VMAX (m/s)	LA/AO (M-Mode)	LA/AO (Heart Base; Swe)	FS (%)	EF (%)	EPSS (cm)
NORMAL PARAMETER	4.5-5.5	<2.7	1.3	Up to 1.6	28-40	40-100	<0.6
PATIENT	5.6	3.14	NM	1.4	49	82	0.1
CANINE CARDIAC PARAMETERS	HR (BPM)	AV VMAX (m/s)	PV MAX (m/s)	BODY WEIGHT (lbs)	LAD LA MAX 4 Chamber	LVIDd Avg; 2D and m-mode short axis (cm)	LVIDs Avg; 2D and m-mode short axis (cm)
NORMAL PARAMETER	50-100	0.7-1.7	0.7-1.6				
PATIENT	130	1.42	0.8	21.7	2.7	2.55	--

Cardiac Presentation

The echocardiogram in this patient demonstrated normal **left atrial** size based on 3 different LA measurement methods. Chamber volumes and echogenicity were normal. The cranial and caudal **mitral** valve leaflets presented vegetative thickening consistent with endocardiosis. Doppler indicated measurable insufficiency. The **left ventricle** presented thicknesses with linear contour and was not dilated nor restricted. The **myocardium** presented normal echogenicity without subjective evidence of significant fibrotic or ischemic disease. **Contractility** of the ventricular walls was adequate and in normal range for this patient evidenced by the fractional shortening measurement and subjective evaluation of the different regions of the myocardium. The **left ventricular outflow** tract demonstrated normal laminar flow and subjective structural integrity. The **right atrium** and auricle revealed normal size, structure and content. No evidence of masses was noted or chamber overload. **Tricuspid** valvular assessment demonstrated adequate linear morphology. The **right ventricle** was of normal size (1/3 diameter of LV), chordae structure, myocardial echogenicity and thickness. **Pulmonic** tract assessment revealed normal valve structure, laminar flow, and diameter (approx. 1:1 pa/ao ratio). No visible **pericardial** or free pleura fluid was noted. No echographically detectable evidence of infiltrative disease was visible. The cranial **mediastinum** and **pericardial** regions were free of masses in the visible window.



PATIENT

Parker Barnes

SPECIES

Canine

BREED

Chihuahua x

SEX

Neutered Male

AGE

13 Years 6 Months

WEIGHT

21.7 lbs

INTERPRETED BY

Eric Lindquist, DMV,
DABVP (CFM), Cert.
IVUSS

IMAGING PERFORMED BY

Vincent Ravancho, CVT

HOSPITAL NAME

Whippany Veterinary
Hospital

REFERRING VET

Dr. Enoch

INVOICE

75296

DATE

5/20/26

Urinary System

The **urinary bladder**, trigone, and pelvic urethra presented normal thicknesses and normal tone. The ureters were not visible which is normal. No uroliths or sediment were visualized and anechoic urine was present. No evidence of inflammatory or neoplastic changes were noted. Ureteral papillae were normal. The pelvic urethra was imaged 2.0 cm beyond the cystourethral junction.

The residual prostate measured 1.0 cm.

The **kidneys** revealed largely normal size and structure, corticomedullary definition and ratio (cortex 1/3 of medulla) were essentially maintained with some age-related loss of curvilinear patterns regarding the capsule and C/M junction. The cortices presented largely uniform texture with some increased echogenicity expected for his age patient. Medullary structure differed distinctly from that of the cortex and no evidence of pelvic dilation was present. Right kidney measured 4.55 cm. Left kidney measured 4.13 cm.

Adrenal Glands

Both **adrenal glands** were visualized and recognized as having normal shape, size, position and echogenicity for this breed. The phrenic vasculature, glandular echogenicity and detail were unremarkable. Capsule, cortex, and medullary definition were normal for this age patient. Right measured 2.0 cm x 0.73 cm at the cranial pole and 0.68 cm at the caudal pole. Left measured 2.17 cm x 0.57 cm at the cranial pole and 0.54 cm at the caudal pole.

Spleen

The **spleen** revealed a focal hypoechoic nodule at the cranial pole with disrupted architecture. The nodule measured approximately 1.0 cm.

Liver

The **liver** images submitted revealed subjectively normal liver size, contour, and structure. Parenchymal echogenicity was naturally coarse and hypoechoic to the spleen. Vascular and biliary tracts were of normal volume with no evidence of congestion. The gallbladder presented acceptably thin walls with primarily anechoic content. The cystic and common bile ducts were normal. No pathological hepatic lymphadenopathy was evident. No overt structural evidence of inflammatory, infiltrative or regenerative pathology was evident.

Gastrointestinal

Examination of the **gastrointestinal tract** revealed a stomach and intestine free of stasis, of normal wall thickness, acceptable curvilinear mural detail, and peristaltic activity. Small and large intestine demonstrated normal luminal chyme and stool consistency respectively. No obstructive or overt infiltrative disease was noted. No associated abnormal lymphatic activity was noted.

Pancreas

The base and limbs of the **pancreas** were observed to be largely isoechoic to surrounding omental fat. Pancreatic duct and capsular contour were acceptably normal and parenchyma respected normal curvilinear patterns. No overt evidence of active inflammatory or neoplastic disease was noted.



PATIENT

Parker Barnes

SPECIES

Canine

BREED

Chihuahua x

SEX

Neutered Male

AGE

13 Years 6 Months

WEIGHT

21.7 lbs

INTERPRETED BY

Eric Lindquist, DMV,
DABVP (CFM), Cert.
IVUSS

IMAGING PERFORMED BY

Vincent Ravancho, CVT

HOSPITAL NAME

Whippany Veterinary
Hospital

REFERRING VET

Dr. Enoch

INVOICE

75296

DATE

5/20/26

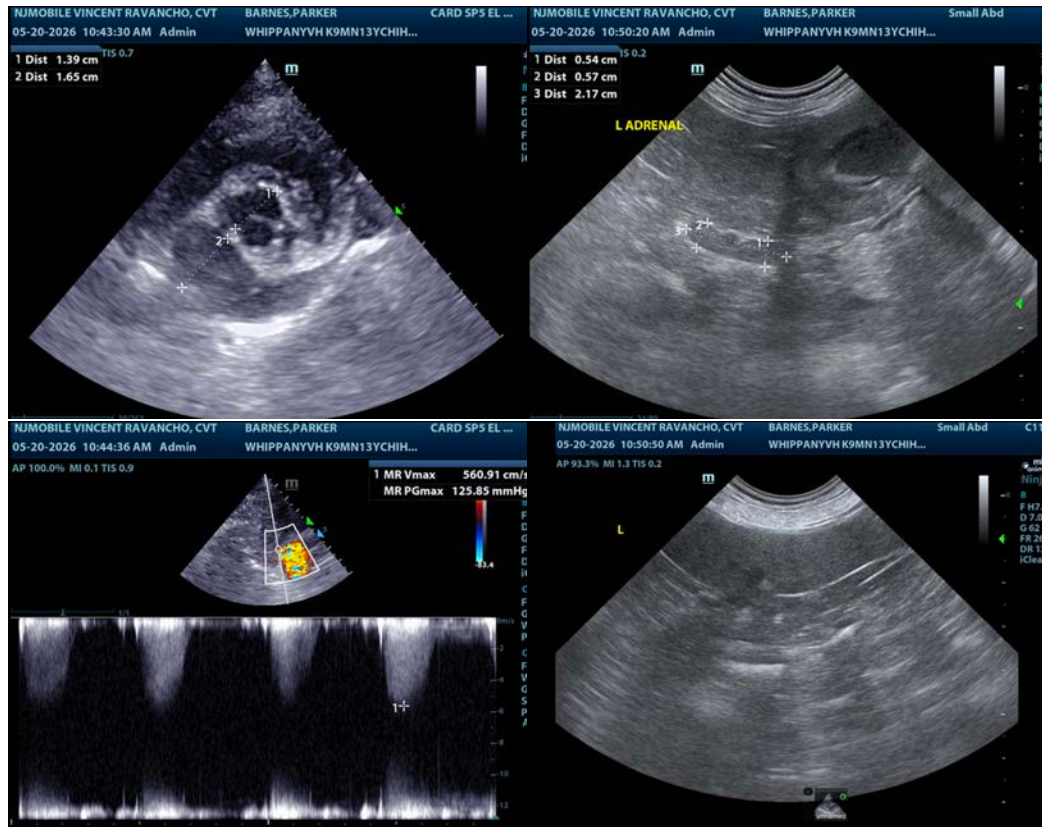
ULTRASONOGRAPHIC FINDINGS

- Stage B1 valvular disease.
- Splenic nodule – Differentials include hyperplasia, abscessation, necrosis, round cell neoplasia, emerging hemangiosarcoma.
- Age related renal changes.

INTERPRETATION OF THE FINDINGS & FURTHER RECOMMENDATIONS

The heart is stable without clinical disease. No overt contraindication for anesthesia of brief to moderate duration. I suggest Torbutrol premed, Propofol induction, Isoflo maintenance or similar protocol if anesthesia is desired. Blood pressure, EKG and chest radiographs are recommended if not already performed. Target white coat negative systolic pressure of < 160 mmHg. If higher than this ACE-inhibitor is suggested to reach this level. Recheck echocardiogram is recommended in 6 months, earlier if murmur grade increases or clinical signs initiate.

No evidence of significant abdominal disease. Recheck splenic nodule in one month. If it is growing, removal or ultrasound guided FNA indicated. The cause of azotemia is unclear in this patient, as structurally the kidneys appear to have only minor change. Subacute renal insult should be considered. I cannot rule out emerging PDH, given the PU/PD in this patient. However, structurally the adrenals appear normal, which can happen in approximately 15% of PDH cases.





PATIENT

Parker Barnes

SPECIES

Canine

BREED

Chihuahua x

SEX

Neutered Male

AGE

13 Years 6 Months

WEIGHT

21.7 lbs

INTERPRETED BY

Eric Lindquist, DMV,
 DABVP (CFM), Cert.
 IVUSS

IMAGING PERFORMED BY

Vincent Ravancho, CVT

HOSPITAL NAME

Whippany Veterinary
 Hospital

REFERRING VET

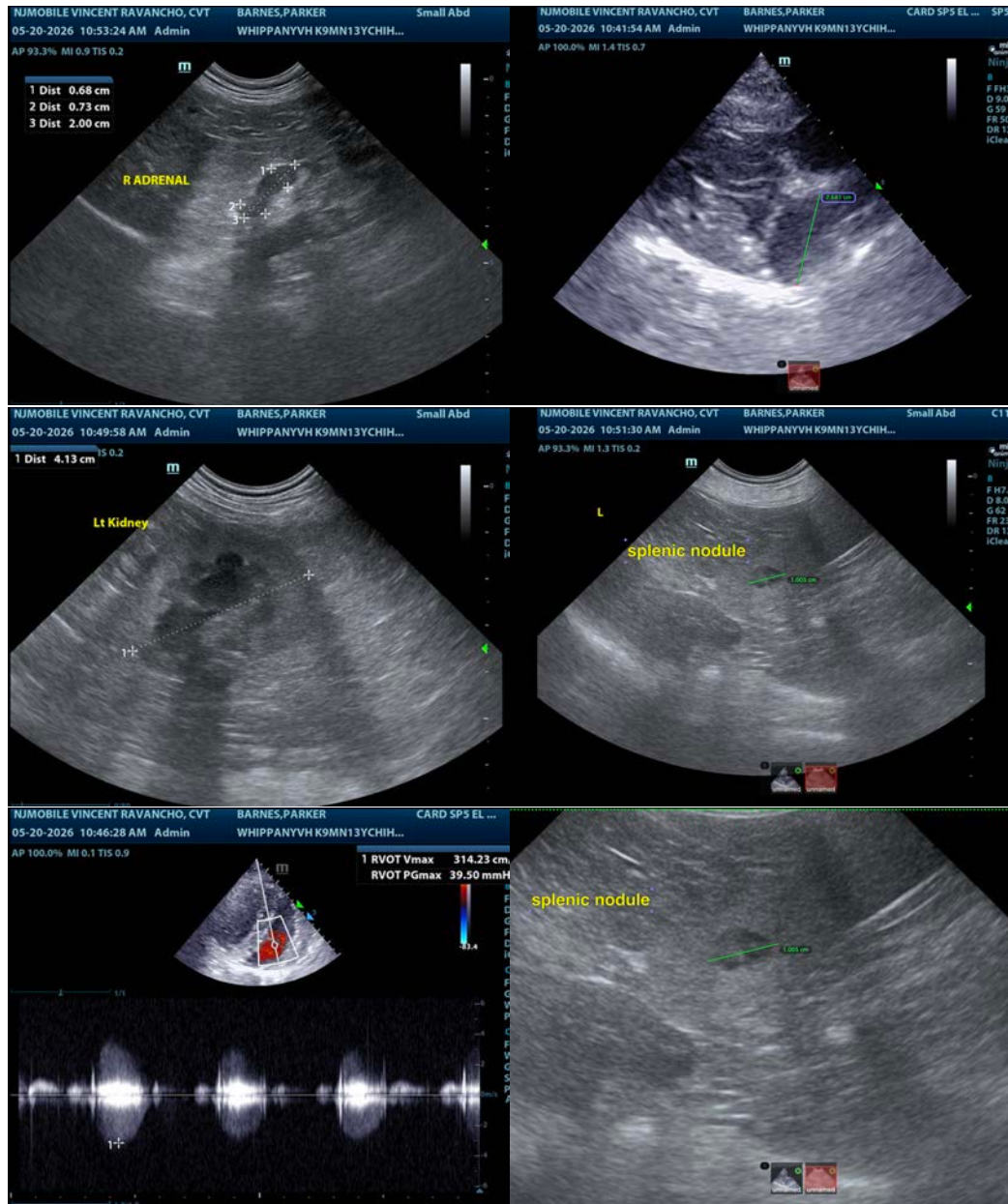
Dr. Enoch

INVOICE

75296

DATE

5/20/26





PATIENT

Parker Barnes

SPECIES

Canine

BREED

Chihuahua x

SEX

Neutered Male

AGE

13 Years 6 Months

WEIGHT

21.7 lbs

INTERPRETED BY

Eric Lindquist, DMV,
DABVP (CFM), Cert.
IVUSS

IMAGING PERFORMED BY

Vincent Ravancho, CVT

HOSPITAL NAME

Whippany Veterinary
Hospital

REFERRING VET

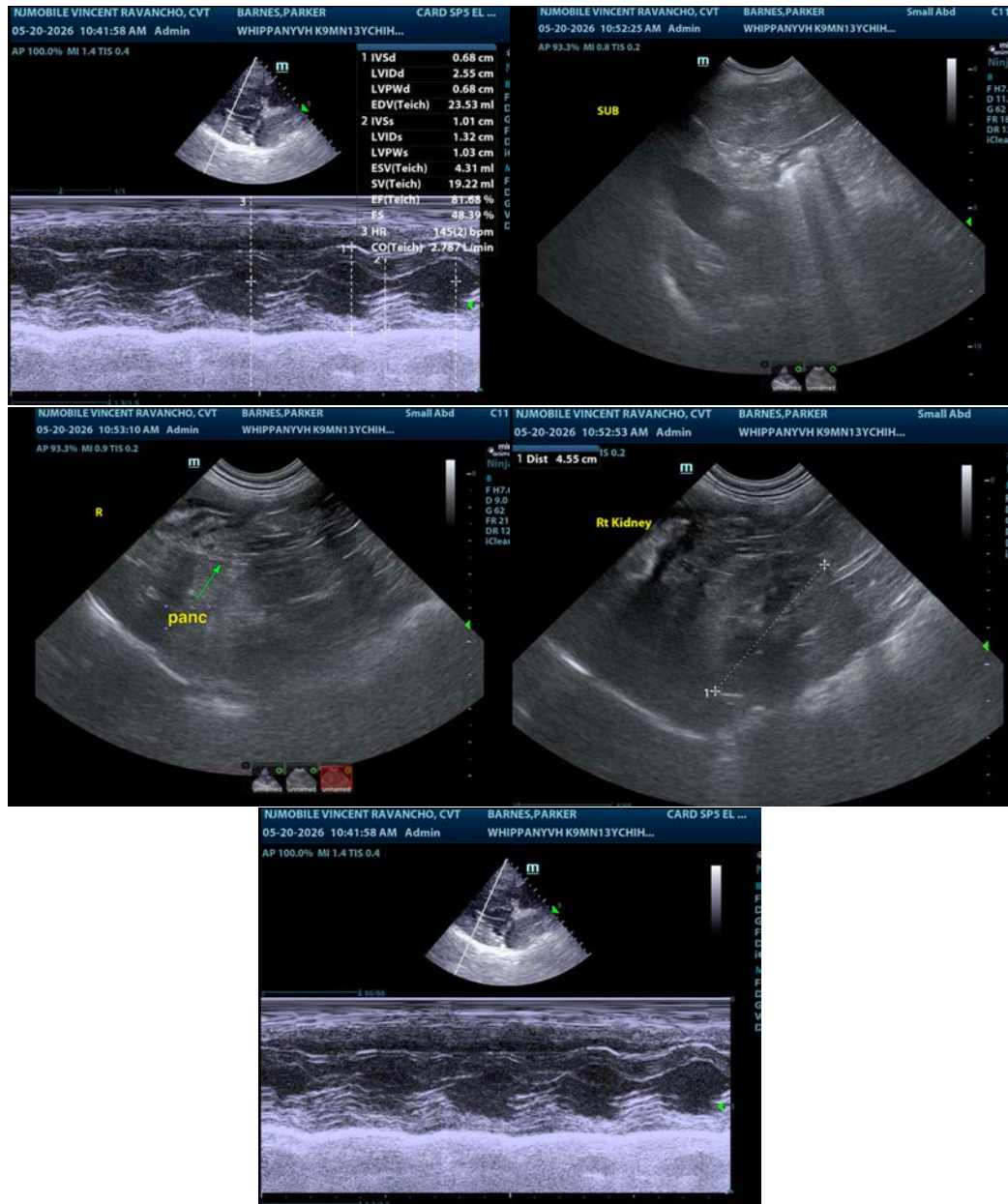
Dr. Enoch

INVOICE

75296

DATE

5/20/26



The information and recommendations provided are based on the images presented by the referring veterinarian/sonographer. No evaluation can be communicated regarding pathology that was not visible in the image/video clips provided.

Thank you for this referral. If the clinical or image interpretation does not parallel your findings or if I can be of any further assistance please contact me.

Eric Lindquist, DMV, DABVP(CFM), Cert. IVUSS,
CEO, Owner, Founder -- SonoPath.com
info@SonoPath.com