



PATIENT

Nicky Linares

SPECIES

Feline

BREED

DSH

SEX

Spayed Female

AGE

14 Years

WEIGHT

6.38 kg

INTERPRETED BY

Eric Lindquist, DMV,
DABVP (CFM), Cert.
IVUSS

IMAGING PERFORMED BY

Vincent Ravancho, CVT

HOSPITAL NAME

Bond Vet Montclair

REFERRING VET

Dr. Mancuso

INVOICE

75298

DATE

5/20/26

PRESENTING CLINICAL SIGNS

U/S for echo. Clinical findings - Dyspnea, on Sunday, increased BV sounds bilaterally, B-Lines, Abnormal BNP. Current medications - Furosemide 12.5 mg 1/2 tab q8hr.

Abnormal PE/Chem/CBC/UA Results: Abnormal proBNP, Hyperglycemia, Elevated BUN, Hypokalemia

ULTRASONOGRAPHIC EXAMINATION OF THE HEART

FELINE CARDIAC PARAMETERS	BODY WEIGHT (kg)	HR (BPM)	IVSd (cm)	LVIDd (cm)	LVWd (cm)	FS (%)	EF (%)
NORMAL PARAMETER	-----	150-240	0.3-0.6	1.0-2.1	0.25-0.6	35-67	80-100
PATIENT	6.38	NM	0.5	1.5	1.4	50	80
FELINE CARDIAC PARAMETERS	LA/AO (M-mode)	LA/AO HEART BASE (Sisson)	LAD LA MAX 4 Chamber		LVOT VEL. (m/s)	RVOT VEL. (m/s)	IVRT (m/)
NORMAL PARAMETER	<1.5	1.6	0.7-1.7		<1.6	<1.3	40-60
PATIENT	1.6	1.3	1.7		1.0	1.0	NM
Adapted from June Boon, Veterinary Echocardiography, 1998 Sisson D et al. JVIM 1991; 5: 232, Jacobs et al. Am J Vet Res 1985; 46:1705							

E-wave velocity = 0.9

Cardiac Presentation

The echocardiogram in this patient demonstrated normal **left atrial** size based on 3 separate LA measurements. The cranial and caudal **mitral** valve leaflets presented normal linear structure and kinetics.. The **left ventricle** presented normal thicknesses with linear contour and was not dilated nor restricted. The **myocardium** presented normal echogenicity without subjective evidence of significant fibrotic or ischemic disease. **Contractility** of the ventricular walls was adequate and in normal range for this patient evidenced by the fractional shortening measurement and subjective evaluation of the different regions and angles of the myocardium. The **left ventricular outflow** tract demonstrated normal laminar flow and subjective structural integrity. The **right atrium** and auricle revealed normal size, structure and content. No evidence of masses was noted or chamber overload. **Tricuspid** valvular assessment demonstrated adequate linear morphology and kinetics. The **right ventricle** was of normal size (1/3 diameter of LV), chordae structure, myocardial echogenicity and thickness. **Pulmonic** tract assessment revealed normal valve structure, laminar flow, and diameter (approx.1:1 pa/ao ratio). No visible **pericardial** or free pleura fluid was noted or extra cardiac pathology in the visible planes. The cranial **mediastinum** and **pericardial regions** were free of masses in the visible window.

Hepatic veins were not dilated.



PATIENT

Nicky Linares

SPECIES

Feline

BREED

DSH

SEX

Spayed Female

AGE

14 Years

WEIGHT

6.38 kg

INTERPRETED BY

Eric Lindquist, DMV,
 DABVP (CFM), Cert.
 IVUSS

IMAGING PERFORMED BY

Vincent Ravancho, CVT

HOSPITAL NAME

Bond Vet Montclair

REFERRING VET

Dr. Mancuso

INVOICE

75298

DATE

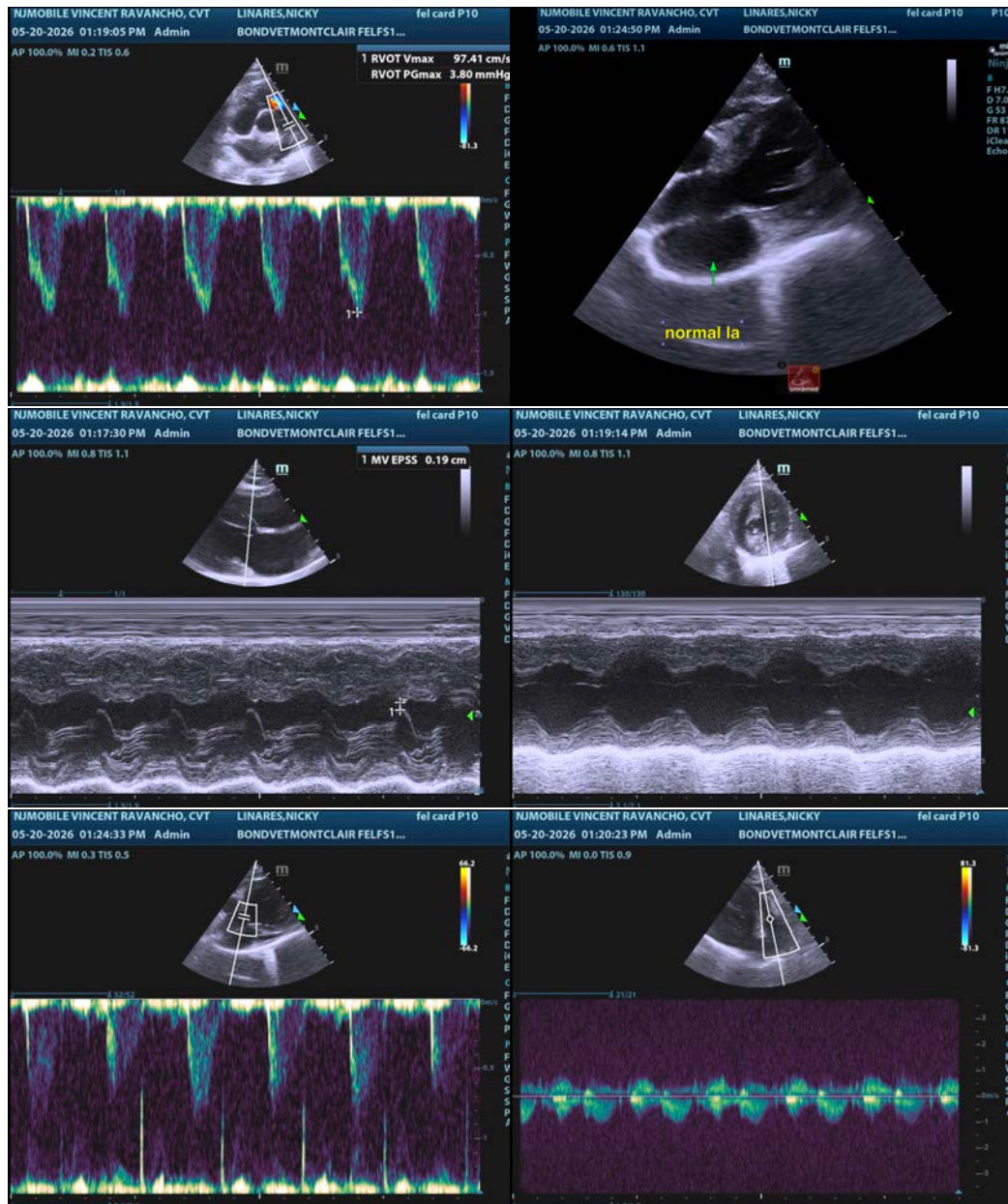
5/20/26

ULTRASONOGRAPHIC FINDINGS

- Essentially normal echocardiogram.

INTERPRETATION OF THE FINDINGS & FURTHER RECOMMENDATIONS

The heart does not appear to be a primary player in this patient. Primary respiratory disease should be considered given the history. Abdominal sonogram warranted to assess for primary disease. The BNP is likely an effector organ issue owing to systemic disease, as there is no significant evidence of cardiac disease noted at this time.





PATIENT

Nicky Linares

SPECIES

Feline

BREED

DSH

SEX

Spayed Female

AGE

14 Years

WEIGHT

6.38 kg

INTERPRETED BY

Eric Lindquist, DMV,
DABVP (CFM), Cert.
IVUSS

IMAGING PERFORMED BY

Vincent Ravancho, CVT

HOSPITAL NAME

Bond Vet Montclair

REFERRING VET

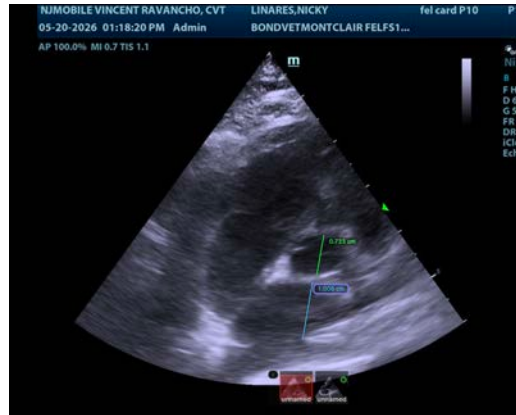Dr. Mancuso

INVOICE

75298

DATE

5/20/26



The information and recommendations provided are based on the images presented by the referring veterinarian/sonographer. No evaluation can be communicated regarding pathology that was not visible in the image/video clips provided.

Thank you for this referral. If the clinical or image interpretation does not parallel your findings or if I can be of any further assistance please contact me.

Eric Lindquist, DMV, DABVP(CFM), Cert. IVUSS,
CEO, Owner, Founder -- SonoPath.com
info@SonoPath.com