

**DATE**

5/20/22

**PRESENTING CLINICAL SIGNS**

P is a referral for pancreatitis. On Tuesday P was picked up from the border and started vomiting and having a decrease in appetite. P has been very lethargic. Today P did not want to eat at all. P went to rDVM bloodwork showed: HCT: 66%, WBC increased, Creatine 2.4, BUN 46, ALT 146, Amylase/Lipase increased.

**PATIENT**

Addy Carter

Xrays: gas pattern

Current Medications: ondanestron, protonix, buprenorphine, ampicillin/sulbactam.

Date of Previous IntraPet Ultrasound: No previous.

Sedation: Not required to complete full diagnostic ultrasound.

Stat Report: Not requested.

Imaging Performed By: Rachel Brilhart, RDMS.

**SPECIES**

Canine

**BREED**

Basset Hound Mix

**ULTRASONOGRAPHIC EXAMINATION OF THE ABDOMEN****Urinary System**

The **urinary bladder**, trigone, and pelvic urethra presented normal thicknesses and normal tone. The ureters were not visible which is normal. No uroliths or sediment were visualized and anechoic urine was present. No evidence of inflammatory or neoplastic changes was noted. Ureteral papillae were normal.

**SEX**

Spayed Female

The **kidneys** revealed normal size and structure, corticomedullary definition and ratio for this age. The cortices presented largely uniform texture with normal echogenic relationship to liver and spleen. Medullary structure differed distinctly from the cortex and no evidence of pelvic dilation was present. The capsules were acceptably uniform without significant irregularities. The left kidney measured 7.01 cm. The right kidney measured 6.65 cm.

**AGE**

5/19/15

**WEIGHT**

85 lbs

**Adrenal Glands**

Both **adrenal glands** were visualized and recognized as having normal shape, size, position and echogenicity for this breed. The phrenic vasculature, glandular echogenicity and detail were unremarkable. Capsule, cortex, and medullary definition were normal for this age patient. The left adrenal gland measured 2.94 x 0.72 cm at the caudal pole and 0.72 cm at the cranial pole. The right adrenal gland measured 3.3 x 0.79 cm at the caudal pole and 0.54 cm at the cranial pole.

**INTERPRETED BY**Eric Lindquist, DMV  
DABVP, Cert. IVUSS**Spleen**

The **spleen** presented a smooth homogeneous parenchyma hyperechoic to liver and renal cortical parenchyma. The capsule was smooth without noticeable expansion or deviation from within the spleen or adjacent pathology. The splenic vasculature demonstrated normal volume without signs of congestion or thrombosis. No sonographic evidence of acute or chronic inflammatory, neoplastic, or infarctual changes was noted.

**HOSPITAL NAME**Animal Emergency  
Hospital**REFERRING VET**

Dr. Roper

**Liver**

The **liver** images submitted revealed subjectively normal liver size, contour, and structure. Parenchymal echogenicity was naturally coarse and hypoechoic to the spleen. Vascular and biliary tracts were of normal volume with no evidence of congestion. The gallbladder presented acceptably thin walls with primarily anechoic content. The cystic and common bile ducts were normal. No pathological hepatic lymphadenopathy was evident. No overt structural evidence of inflammatory, infiltrative or regenerative pathology was evident.

**INVOICE**

30554

### **Gastrointestinal**

The **gastrointestinal tract** revealed 3.0 cm soft shadowing pyloric structure. This is consistent with thread or similar. This is attached to linear foreign body entering into the small intestine with regional inflammation around the pyloric outflow extending to the right pancreatic limb. The linear foreign body continued into the jejunum with accordion pleating and regional intestinal thickening.

### **Pancreas**

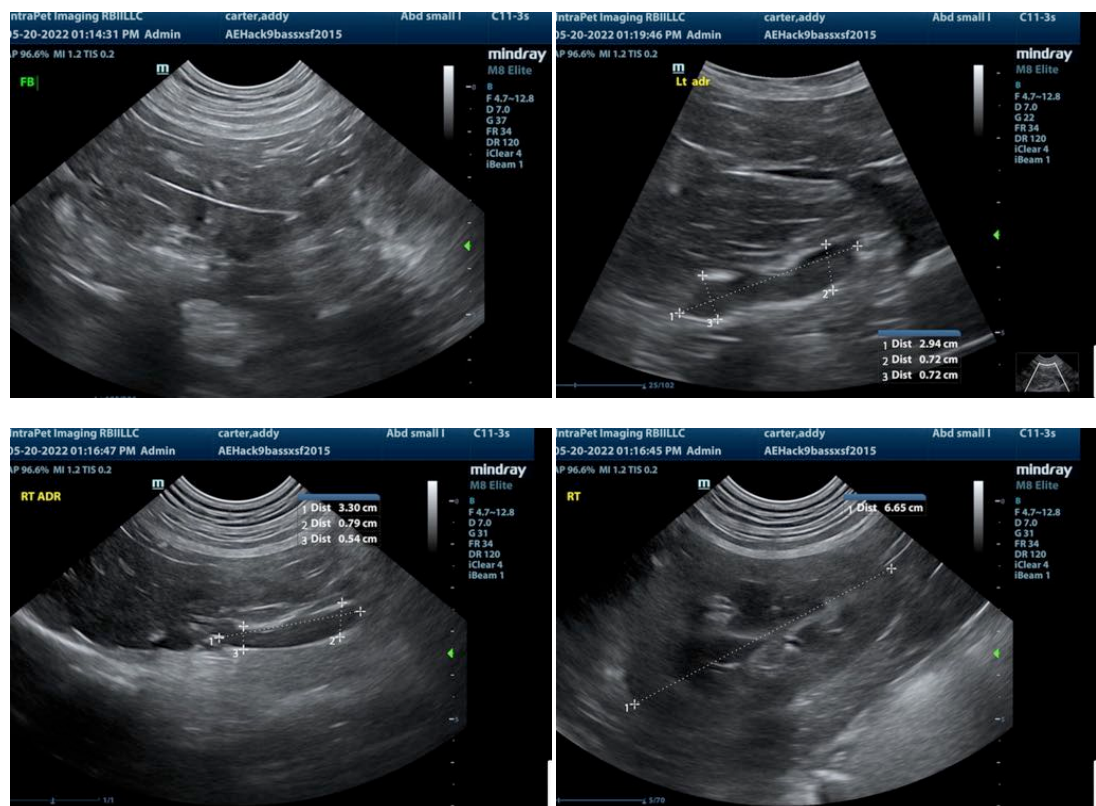
Regional inflammation from the pyloric outflow extended to the right **pancreatic limb**. The remainder of the pancreas was unremarkable.

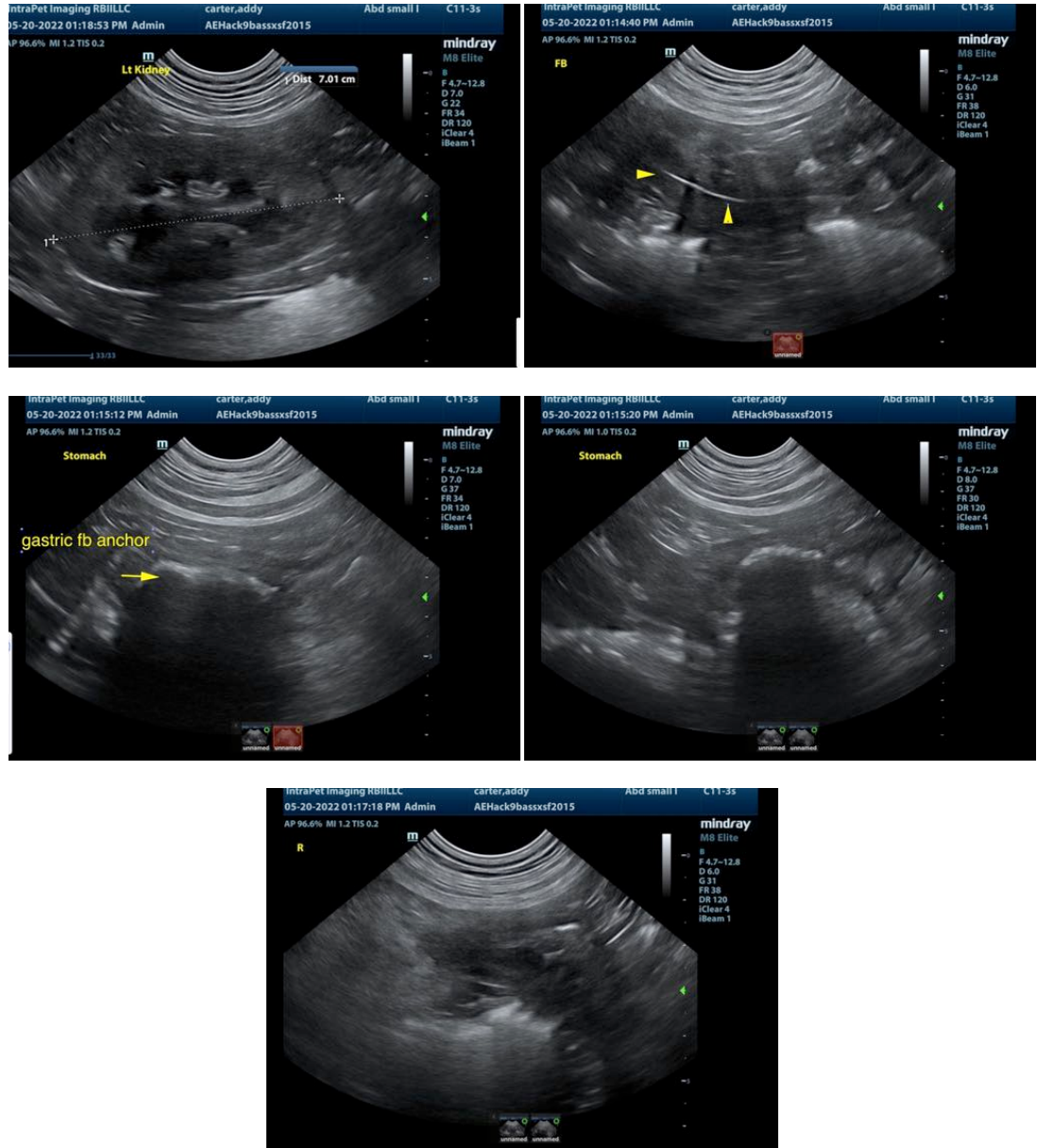
### **ULTRASONOGRAPHIC FINDINGS**

Gastrointestinal linear foreign body.  
Regional early peritonitis.  
Otherwise, unremarkable abdomen.

### **INTERPRETATION OF THE FINDINGS & FURTHER RECOMMENDATIONS**

Gastrotomy, enterotomy and GI biopsies are indicated. According to Sonopath research presented at ECVIM 2016 (Stockholm, Sweden), Advances in Small Animal Medicine and Surgery (May 2017), and EVDI 2017 (Verona, Italy), concurrent underlying chronic inflammatory neoplastic intestinal disease can often reside in PICA patients. Therefore, surgical biopsies are essential in this case regardless of the exploratory findings.





The information and recommendations provided are based on the images presented by the referring veterinarian. No evaluation can be communicated regarding pathology that was not visible in the image/video clips provided.

Thank you for this referral. If the clinical or image interpretation does not parallel your findings or if I can be of any further assistance please contact me.

**Eric Lindquist, DMV, DABVP, Cert. IVUSS, CEO of SonoPath.com**  
 Eric.Lindquist@SonoPath.com