



PATIENT

Roxie Mcquire

SPECIES

Canine

BREED

Golden Retriever

SEX

Spayed Female

AGE

12

WEIGHT

97.2

INTERPRETED BY

Eric Lindquist, DMV

DABVP, Cert. IVUSS

IMAGING PERFORMED BY

Adrienne Waffle

HOSPITAL NAME

Torch Lake VC

REFERRING VET

Bellaire AH

INVOICE

47034

DATE

5/2/23

PRESENTING CLINICAL SIGNS

P presented at RDVM -Hematuria and anorexia that began this morning. RDVM would like to R/O neoplasia, cystitis and other

ULTRASONOGRAPHIC EXAMINATION OF THE ABDOMEN

Urinary System

The **urinary bladder**, trigone, and pelvic urethra presented normal thicknesses and normal tone. The ureters were not visible which is normal. No uroliths or sediment were visualized and anechoic urine was present. No evidence of inflammatory or neoplastic changes were noted. Ureteral papillae were normal.

The **kidneys** revealed largely normal size and structure, corticomedullary definition and ratio (cortex 1/3 of medulla) were essentially maintained with some age-related loss of curvilinear patterns regarding the capsule and C/M junction. The cortices presented largely uniform texture with some increased echogenicity expected for his age patient. Medullary structure differed distinctly from that of the cortex and no evidence of pelvic dilation was present. The right kidney measured 7.18 cm. The left kidney measured 8.0 cm.

Adrenal Glands

The **left adrenal gland** was visualized and recognized as having normal shape, size, position and echogenicity for this breed. The phrenic vasculature, glandular echogenicity and detail were unremarkable. Capsule, cortex, and medullary definition were normal for this age patient. The left adrenal gland measured 0.60 cm.

The **right adrenal gland** was not visualized.

Spleen

The **spleen** presented relatively normal size and contour with multifocal hyperechoic nodular changes, most consistent with fatty deposits or lipogranulomas. These are not typically pathological. No suspicion of significant. Capsular and parenchymal integrity was normal otherwise.

Liver

The **liver** images from right and left intercostal as well as subcostal views revealed subjectively normal liver size, contour, and structure. Some age-related parenchymal remodeling was noted but likely not clinically significant at this time. Vascular and biliary tracts were of normal volume and no evidence of congestion was noted. The gallbladder presented some dependent debris with essentially normal contour. The cystic and common bile ducts were normal. No overt evidence of active inflammatory, infiltrative or regenerative pathology was noted but should be paired with current or past LE elevations regarding any clinical significance to this presentation. The hepatic lymph nodes were unremarkable.

Gastrointestinal

Examination of the **gastrointestinal tract** revealed a stomach and intestine free of stasis, of normal wall thickness, acceptable curvilinear mural detail, and peristaltic activity. Small and large intestine demonstrated normal luminal chyme and stool consistency respectively. No obstructive or overt infiltrative disease was noted. No associated abnormal lymphatic activity was noted.



PATIENT

Roxie Mcquire

SPECIES

Canine

BREED

Golden Retriever

SEX

Spayed Female

AGE

12

WEIGHT

97.2

INTERPRETED BY

Eric Lindquist, DMV
DABVP, Cert. IVUSS

IMAGING PERFORMED BY

Adrienne Waffle

HOSPITAL NAME

Torch Lake VC

REFERRING VET

Bellaire AH

INVOICE

47034

DATE

5/2/23

Pancreas

The base and limbs of the **pancreas** were observed to be largely isoechoic to surrounding omental fat. Pancreatic duct and capsular contour were acceptably normal and parenchyma respected normal curvilinear patterns. No overt evidence of active inflammatory or neoplastic disease was noted.

Free Abdomen

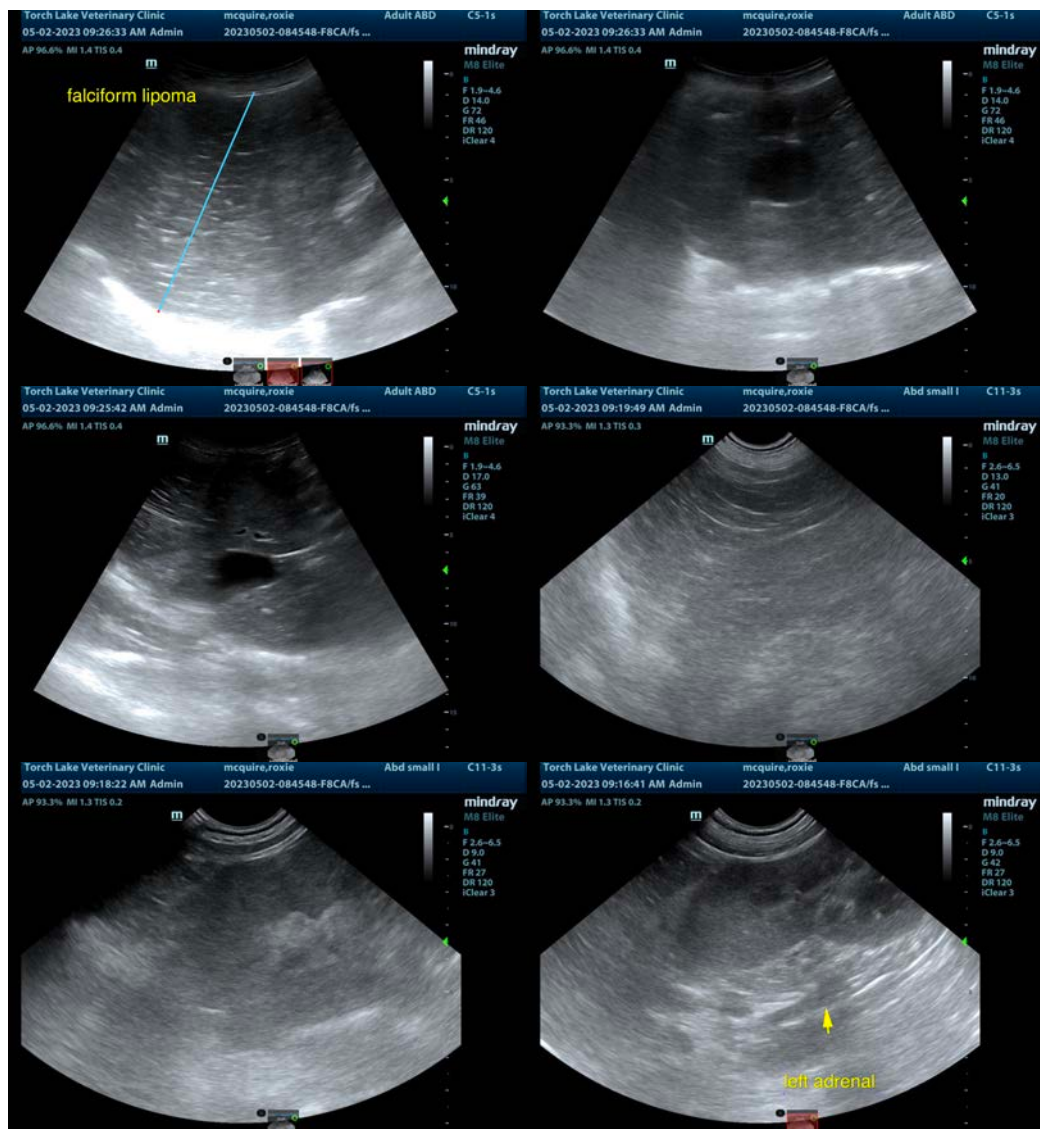
Falciform fat was excessive with lipomatous type presentation, impinging upon the diaphragm and the liver. It does not appear pathological.

ULTRASONOGRAPHIC FINDINGS

- Unremarkable geriatric abdomen with falciform lipoma

INTERPRETATION OF THE FINDINGS & FURTHER RECOMMENDATIONS

Underlying UTI suspected. Deep pelvic urethral pathology cannot be completely ruled out.





PATIENT

Roxie Mcquire

SPECIES

Canine

BREED

Golden Retriever

SEX

Spayed Female

AGE

12

WEIGHT

97.2

INTERPRETED BY

Eric Lindquist, DMV
DABVP, Cert. IVUSS

IMAGING PERFORMED BY

Adrienne Waffle

HOSPITAL NAME

Torch Lake VC

REFERRING VET

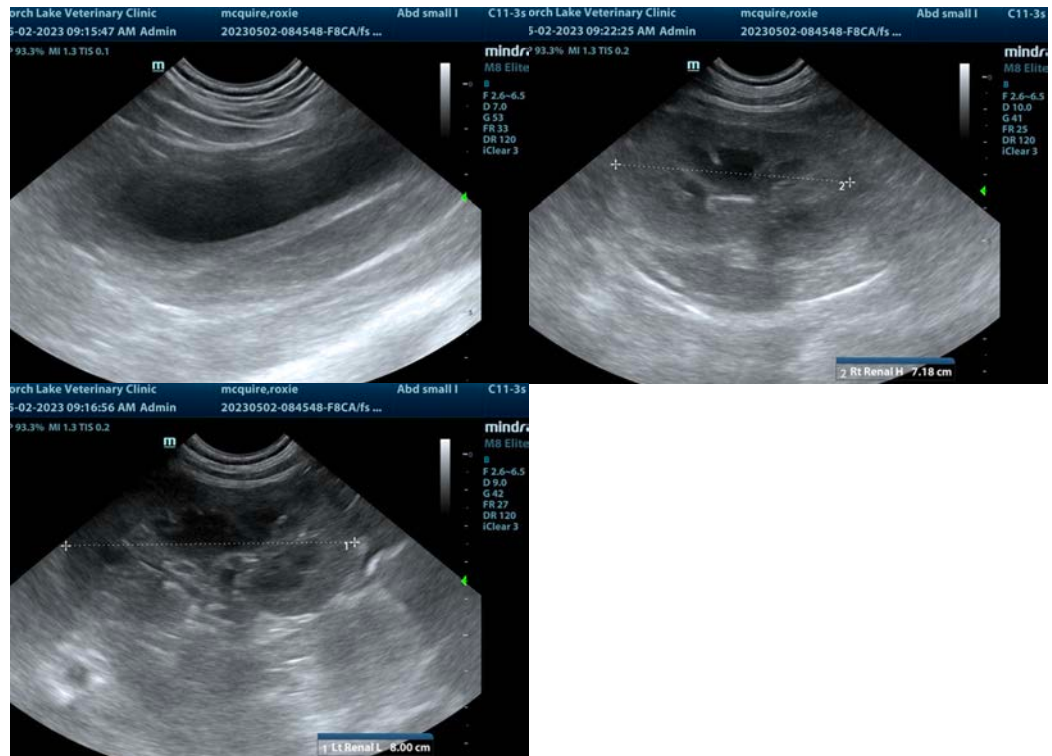
Bellaire AH

INVOICE

47034

DATE

5/2/23



The information and recommendations provided are based on the images presented by the referring veterinarian/sonographer. No evaluation can be communicated regarding pathology that was not visible in the image/video clips provided.

Thank you for this referral. If the clinical or image interpretation does not parallel your findings or if I can be of any further assistance please contact me.

Eric Lindquist, DMV, DABVP, Cert. IVUSS, CEO of SonoPath.com

info@SonoPath.com