

**DATE**

5/2/23

PATIENT

Harriet Estep

SPECIES

Feline

BREED

DSH

SEX

Spayed Female

AGE

5/1/08

WEIGHT

7.2 Pounds

INTERPRETED BYEric Lindquist, DMV
DABVP, Cert. IVUSS**HOSPITAL NAME**Animal Emergency
Hospital**REFERRING VET**

Dr. Martinoli

INVOICE

47036

PRESENTING CLINICAL SIGNS

Hx of renal changes, Hx of getting anxious with fecal balls. PC-- collapse
Problems found-- possible cranial mediastinal mass, Anemia- non regenerative
Dx: renal values wnl, BNP 211. Progress: Increase in RR and effort overnight

Current Medications: Cerenia, Gabapentin, Buprenorphine.

Lab Results: See attached.

Date of Previous IntraPet Ultrasound: No previous.

Sedation: IV: propofol.

Stat Report: Not requested.

Imaging Performed By: Rachel Brillhart, RDMS.

ULTRASONOGRAPHIC EXAMINATION OF THE ABDOMEN**Urinary System**

The **urinary bladder**, trigone, and pelvic urethra presented normal thicknesses and normal tone. The ureters were not visible which is normal. No uroliths or sediment were visualized and anechoic urine was present. No evidence of inflammatory or neoplastic changes were noted. Ureteral papillae were normal.

The **kidneys** revealed largely normal structure, corticomedullary definition and ratio (cortex 1/3 of medulla) were essentially maintained with some age-related loss of curvilinear patterns regarding the capsule and C/M junction. The cortices presented largely uniform texture with some increased echogenicity expected for his age patient. Medullary structure differed distinctly from that of the cortex. The right kidney was subnormal in size at 2.1 cm. The left kidney was normal in size at 3.07 cm with slight pyelectasia. Moderate degenerative changes and cortical infarcts noted in both kidneys, primarily on the right.

Adrenal Glands

The regions of the **adrenal glands** were unremarkable.

Spleen

The **spleen** presented a smooth homogeneous parenchyma hyperechoic to liver and renal cortical parenchyma. The capsule was smooth without noticeable expansion or deviation from within the spleen or adjacent pathology. The splenic vasculature demonstrated normal volume without signs of congestion or thrombosis. No sonographic evidence of acute or chronic inflammatory, neoplastic, or infarctual changes were noted.

Liver

The **liver** presented mild coarse architecture. Lobar biliary calculi noted. Passive congestion pattern. The gallbladder was unremarkable.

Gastrointestinal

The **gastrointestinal tract** revealed minor variable thickening and echogenic submucosal changes most consistent with low grade end result of chronic GI disease such as IBD and may be related to malassimilation of nutrients if any weight loss is present. No obvious neoplastic patterns were noted and luminal content as unremarkable.

Pancreas

The base and limbs of the **pancreas** were observed to be largely isoechoic to surrounding omental fat. Pancreatic duct and capsular contour were acceptably normal and parenchyma respected normal curvilinear patterns. No overt evidence of active inflammatory or neoplastic disease was noted.

Other

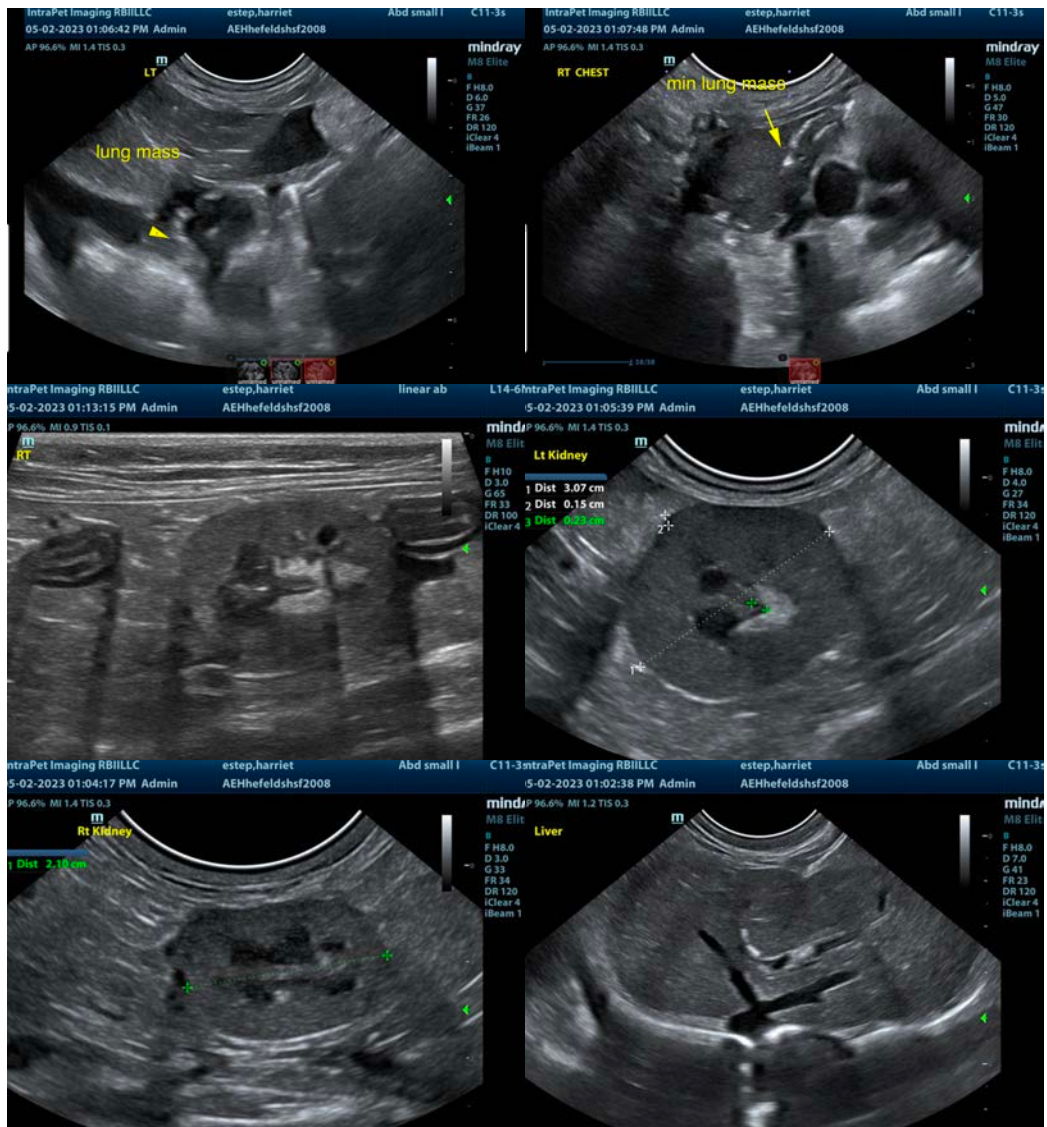
The right thorax revealed a mineralizing mass adjacent to the heart measuring approximately 2.5 cm. The caudal thorax revealed extensive lung pathology consistent with neoplasia, and secondary pleural effusion.

ULTRASONOGRAPHIC FINDINGS

- Thoracic neoplasia with passive congestion liver pattern – lung carcinoma suspected, given the mineralization
- Secondary ascites in the abdomen owing to obstructive caval disease in the thorax
- Age related renal and GI changes

INTERPRETATION OF THE FINDINGS & FURTHER RECOMMENDATIONS

Prognosis is poor.



The information and recommendations provided are based on the images presented by the referring veterinarian/sonographer. No evaluation can be communicated regarding pathology that was not visible in the image/video clips provided.

Thank you for this referral. If the clinical or image interpretation does not parallel your findings or if I can be of any further assistance please contact me.

Eric Lindquist, DMV, DABVP, Cert. IVUSS, CEO of SonoPath.com
info@SonoPath.com