



PATIENT

Dixie Mae Miller

SPECIES

Canine

BREED

Yorkie

SEX

Spayed female

AGE

2 ½ years

WEIGHT

2.22 kg

INTERPRETED BY

Eric Lindquist, DMV
DABVP, Cert. IVUSS

IMAGING PERFORMED BY

Dr. Isermann

HOSPITAL NAME

Animal Emergency
Hospital Volusia

REFERRING VET

Dr. Isermann

INVOICE

44100

DATE

5/1/23

PRESENTING CLINICAL SIGNS

History: P came in for having diarrhea on and off for the past few weeks. Has been on GI diet. On direct fecal- yeast 1-5 hpf, cocci, non-motile rods

ULTRASONOGRAPHIC EXAMINATION OF THE ABDOMEN

Urinary System

The **urinary bladder**, trigone, and pelvic urethra presented normal thicknesses and normal tone. The ureters were not visible which is normal. No uroliths or sediment were visualized and anechoic urine was present. No evidence of inflammatory or neoplastic changes was noted. Ureteral papillae were normal.

The **kidneys** revealed normal size and structure, corticomedullary definition and ratio for this age. The cortices presented largely uniform texture with normal echogenic relationship to liver and spleen. Medullary structure differed distinctly from the cortex and no evidence of pelvic dilation was present. The capsules were acceptably uniform without significant irregularities. The left kidney measured

Adrenal Glands

The left **adrenal gland** was visualized and recognized as having normal shape, size, position and echogenicity for this breed. The phrenic vasculature, glandular echogenicity and detail were unremarkable. Capsule, cortex, and medullary definition were normal for this age patient. The left adrenal gland measured 0.5 cm. The right adrenal gland was slightly subnormal in size and measured 0.32 cm at the cranial pole and 0.5 cm at the caudal pole.

Spleen

The **spleen** presented a smooth homogeneous parenchyma hyperechoic to liver and renal cortical parenchyma. The capsule was smooth without noticeable expansion or deviation from within the spleen or adjacent pathology. The splenic vasculature demonstrated normal volume without signs of congestion or thrombosis. No sonographic evidence of acute or chronic inflammatory, neoplastic, or infarctual changes was noted.

Liver

The **liver** was mildly subnormal in size. There was no obvious portosystemic shunts and intrahepatic vascularity appeared to be of normal volume. The gallbladder presented acceptably thin walls with primarily anechoic content. The cystic and common bile ducts were normal. No pathological hepatic lymphadenopathy was evident.

Gastrointestinal

Examination of the **gastrointestinal tract** revealed a stomach and intestine free of stasis, of normal wall thickness, acceptable curvilinear mural detail, and peristaltic activity. Small and large intestine



PATIENT

demonstrated normal luminal chyme and stool consistency respectively. No obstructive or overt infiltrative disease was noted. No associated abnormal lymphatic activity was noted.

Dixie Mae Miller

SPECIES

Pancreas

Canine

The base and limbs of the **pancreas** were observed to be largely isoechoic to surrounding omental fat. Pancreatic duct and capsular contour were acceptably normal and parenchyma respected normal curvilinear patterns. No overt evidence of active inflammatory or neoplastic disease was noted.

BREED

Yorkie

ULTRASONOGRAPHIC FINDINGS

SEX

Mildly subnormal liver.

Spayed female

Small right adrenal gland.

Normal left adrenal gland.

AGE

Non-specific gastroenteritis.

2 ½ years

INTERPRETATION OF THE FINDINGS & FURTHER RECOMMENDATIONS

WEIGHT

Bile acid profile is indicated. There is no evidence of obstruction.

2.22 kg

Differentials for diarrhea include occult parasitism. Dietary indiscretion, dietary intolerance, antibiotic responsive colitis, intestinal dysbiosis and occult Addison's should all be considered as causes of diarrhea in this patient. A hydrolyzed diet trial may be in this patient's best interest +/- probiotics. 24-hour NPO and reintroduction of bland diet indicated. I recommend a baseline cortisol or ACTH stimulation test, a fresh fecal smear and fecal floatation analysis if not already performed.

INTERPRETED BY

Eric Lindquist, DMV
DABVP, Cert. IVUS

IMAGING PERFORMED BY

Dr. Isermann

HOSPITAL NAME

Animal Emergency
Hospital Volusia

REFERRING VET

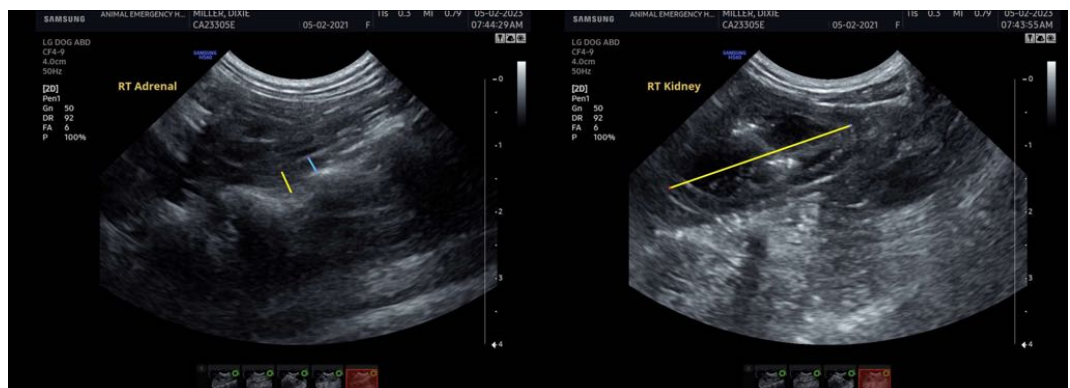Dr. Isermann

INVOICE

44100

DATE

5/1/23





PATIENT

Dixie Mae Miller

SPECIES

Canine

BREED

Yorkie

SEX

Spayed female

AGE

2 ½ years

WEIGHT

2.22 kg

INTERPRETED BY

Eric Lindquist, DMV
DABVP, Cert. IVUS

IMAGING PERFORMED BY

Dr. Isermann

HOSPITAL NAME

Animal Emergency Hospital Volusia

REFERRING VET

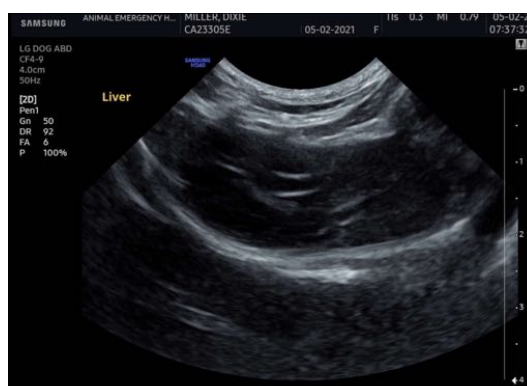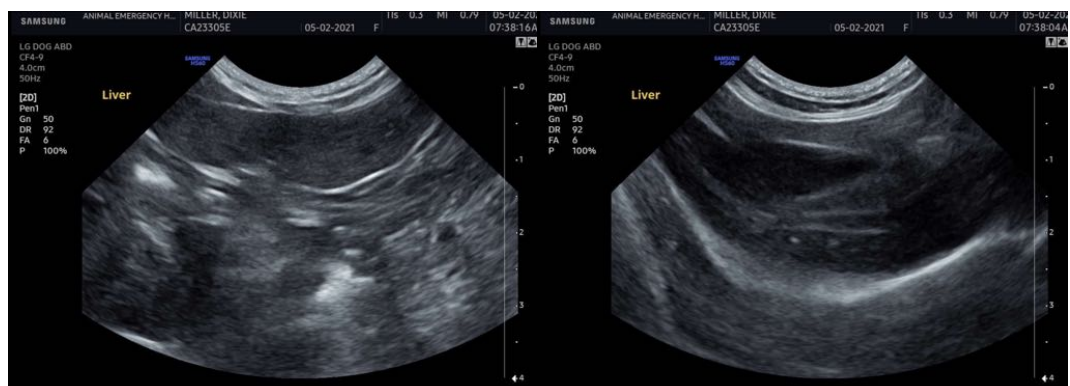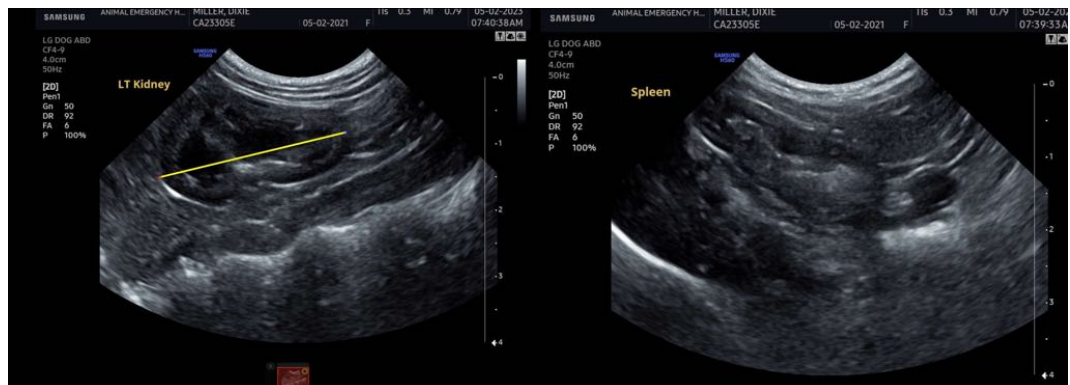
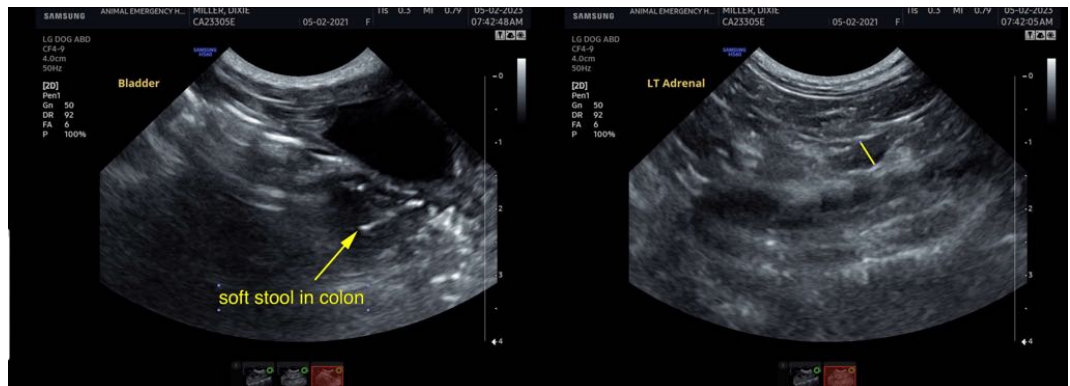
Dr. Isermann

INVOICE

44100

DATE

5/1/23





PATIENT

Dixie Mae Miller

The information and recommendations provided are based on the images presented by the referring veterinarian/sonographer. No evaluation can be communicated regarding pathology that was not visible in the image/video clips provided.

SPECIES

Canine

Thank you for this referral. If the clinical or image interpretation does not parallel your findings or if I can be of any further assistance please contact me.

BREED

Yorkie

Eric Lindquist, DMV, DABVP, Cert. IVUSS, CEO of SonoPath.com
info@SonoPath.com

SEX

Spayed female

AGE

2 ½ years

WEIGHT

2.22 kg

INTERPRETED BY

Eric Lindquist, DMV
DABVP, Cert. IVUSS

**IMAGING
PERFORMED BY**

Dr. Isermann

HOSPITAL NAME

Animal Emergency
Hospital Volusia

REFERRING VET

Dr. Isermann

INVOICE

44100

DATE

5/1/23