



PATIENT

Princess Ragusa

SPECIES

Canine

BREED

Chihuahua

SEX

Spayed Female

AGE

12 Years

WEIGHT

18.2 Pounds

PRESENTING CLINICAL SIGNS

History: Rt atrial enlargement globoid heart echo to see if pt can have anesthesia for dental

ULTRASONOGRAPHIC EXAMINATION OF THE HEART

CANINE CARDIAC PARAMETERS	MR VMAX (m/s)	TR VMAX (m/s)	LA/AO (Boon method)	LA/AO (Heart Base; Swe)	FS (%)	EF (%)	EPSS (cm)
NORMAL PARAMETER	4.5-5.5	<2.7	1.3	<1.3	28-40	40-100	<0.6
PATIENT	--	2.0	1.15	1.3	35	--	0.1
CANINE CARDIAC PARAMETERS	HR (BPM)	AV VMAX (m/s)	PV MAX (m/s)	BODY WEIGHT (kg)	LA 2D short axis Base view (cm)	LVIDd Avg; 2D and m-mode short axis (cm)	LVIDs Avg; 2D and m-mode short axis (cm)
NORMAL PARAMETER	50-100	0.7-1.7	0.7-1.6				
PATIENT	--	--	1.01	--	2.0	1.69	--

Cardiac Presentation

The **echocardiogram** presented a prominent **right heart** with mild **right ventricular** hypertrophy and normal **right atrial** size. Tricuspid insufficiency noted at 2.0 m/s. No evidence of neoplasia was noted in the right auricle, or elsewhere in the heart. The **pulmonary artery** was uniformly prominent with mildly depressed pulmonic velocity measured on PW Doppler. No overt heartworms were noted in the main or visible deep pulmonary arteries. Yet, theoretically heartworms could be present in the deep pulmonary vasculature out of visible sonographic range. More likely, however, this prominent right heart is due to excessive intra-thoracic pressures caused by chronic respiratory disease or potentially excessive intra-thoracic fat (Pickwickian syndrome). The **left heart** demonstrated a linear **ventricular septum**. Contractility was functionally adequate demonstrated by the FS% measurement. The **mitral valve** was not significantly insufficient and no significant **left atrial** dilation was noted. The **left ventricular outflow** demonstrated normal flow patterns and velocities through the aortic valve. No evidence of tumor, pericardial or pleural effusion was noted. The visible **extra-cardiac** tissues were uniformly linear without evidence of masses, infiltrative or inflammatory mediastinal tissue. No evident arrhythmic activity was noted during the exam.

ULTRASONOGRAPHIC FINDINGS

- Cor pulmonale
- Minor right sided cardiac enlargement
- tricuspid insufficiency

INTERPRETATION OF THE FINDINGS & FURTHER RECOMMENDATIONS

No contraindication to anesthetic procedure as long as no primary lung disease is an issue.

INTERPRETED BY

Eric Lindquist, DMV
DABVP, Cert. IVUSS

IMAGING PERFORMED BY

Jenn

HOSPITAL NAME

Rockaway AH

REFERRING VET

Dr. Bednar

INVOICE

15005

DATE

5/2/22



PATIENT

Princess Ragusa

SPECIES

Canine

BREED

Chihuahua

SEX

Spayed Female

AGE

12 Years

WEIGHT

18.2 Pounds

INTERPRETED BY

Eric Lindquist, DMV
DABVP, Cert. IVUSS

IMAGING PERFORMED BY

Jenn

HOSPITAL NAME

Rockaway AH

REFERRING VET

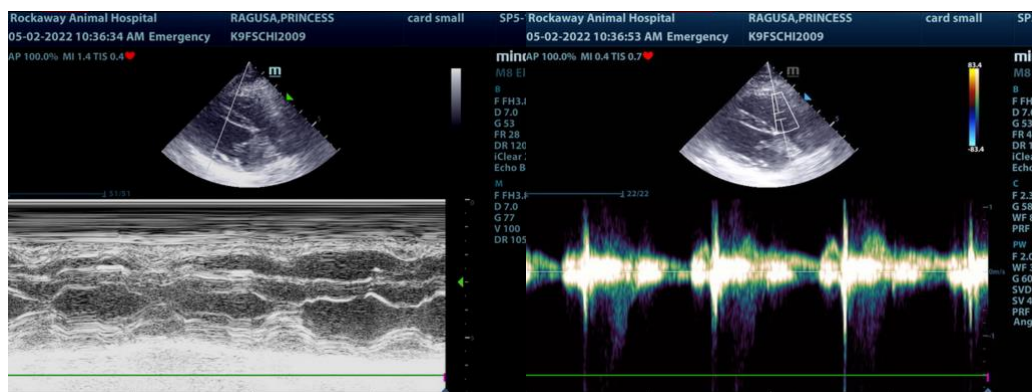
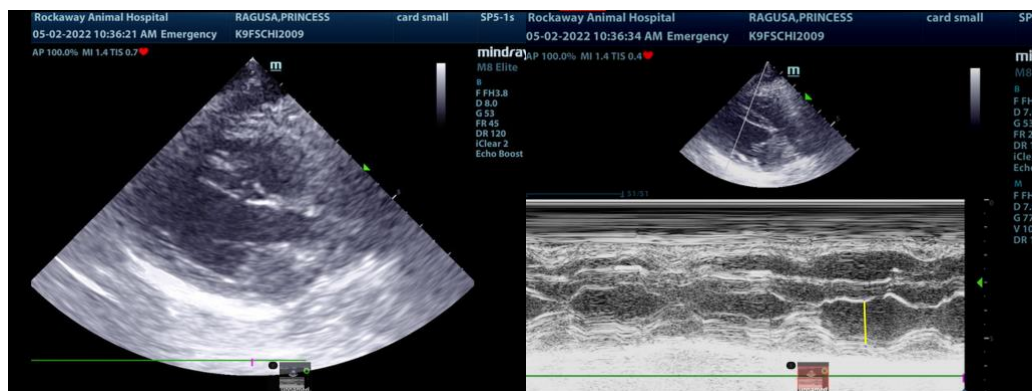
Dr. Bednar

INVOICE

15005

DATE

5/2/22



The information and recommendations provided are based on the images presented by the referring veterinarian. No evaluation can be communicated regarding pathology that was not visible in the image/video clips provided.

Thank you for this referral. If the clinical or image interpretation does not parallel your findings or if I can be of any further assistance please contact me.

Eric Lindquist, DMV, DABVP, Cert. IVUSS, CEO of SonoPath.com
info@SonoPath.com