



PATIENT

Fenway Dodyk

SPECIES

Canine

BREED

Poodle Mix

SEX

Male

AGE

3 Years

WEIGHT

28 Pounds

INTERPRETED BY

Eric Lindquist, DMV
DABVP, Cert. IVUSS

IMAGING PERFORMED BY

Jenn

HOSPITAL NAME

Rockaway AH

REFERRING VET

Dr. Maniar

INVOICE

15010

DATE

5/2/22

PRESENTING CLINICAL SIGNS

History: intermitt increased thyroid values

LIMITED ULTRASONOGRAPHIC EXAMINATION

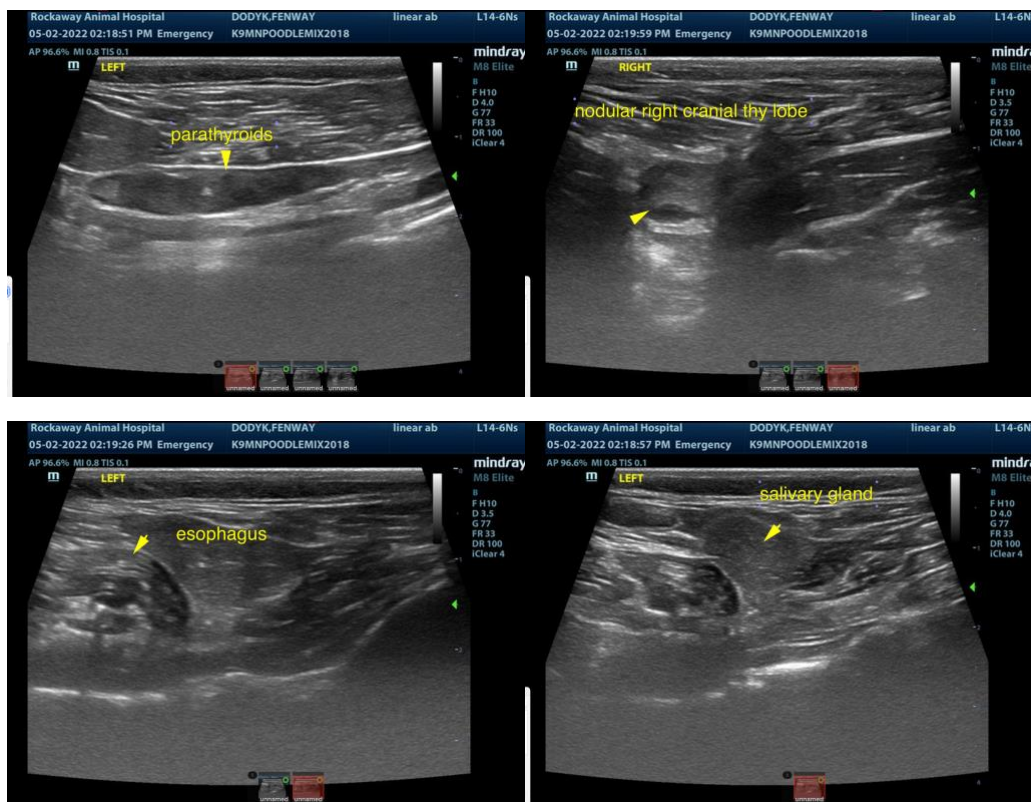
The thyroid region was imaged. The esophagus, salivary glands and regional vasculature were all normal. The right thyroid lobe revealed a heterogeneous nodular change at the cranial pole, measuring approximately 4.0 mm as a grouping of nodules. This should be monitored, especially given the patient history. The left thyroid lobe was largely unremarkable with slight heterogeneous parenchymal changes at the cranial pole. The left thyroid lobe measured 5.0 mm in width. The right thyroid lobe measured 5.0 mm in width. The parathyroids were unremarkable. Regional tissues were unremarkable.

ULTRASONOGRAPHIC FINDINGS

- Bilateral nodular nonspecific thyroid presentation

INTERPRETATION OF THE FINDINGS & FURTHER RECOMMENDATIONS

Given the intermittent increase in thyroid values, I recommend assessing the diet in this patient to ensure no neck meat is being utilized in the diet that may artificially elevate thyroid levels. Recheck sonogram of the thyroid in one month.





PATIENT

Fenway Dodyk

SPECIES

Canine

BREED

Poodle Mix

SEX

Male

AGE

3 Years

WEIGHT

28 Pounds

INTERPRETED BY

Eric Lindquist, DMV
DABVP, Cert. IVUSS

**IMAGING
PERFORMED BY**

Jenn

HOSPITAL NAME

Rockaway AH

REFERRING VET

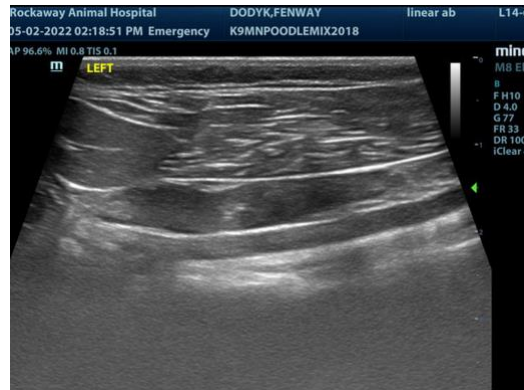Dr. Maniar

INVOICE

15010

DATE

5/2/22



The information and recommendations provided are based on the images presented by the referring veterinarian. No evaluation can be communicated regarding pathology that was not visible in the image/video clips provided.

Thank you for this referral. If the clinical or image interpretation does not parallel your findings or if I can be of any further assistance please contact me.

Eric Lindquist, DMV, DABVP, Cert. IVUSS, CEO of SonoPath.com
info@SonoPath.com