



PATIENT

Bullet Almeida

SPECIES

Canine

BREED

German Shepherd

SEX

Neutered Male

AGE

2 Years

WEIGHT

96 Pounds

INTERPRETED BY

Eric Lindquist, DMV
DABVP, Cert. IVUSS

IMAGING PERFORMED BY

Jenn

HOSPITAL NAME

Rockaway AH

REFERRING VET

Dr. Maniar

INVOICE

15004

DATE

5/2/22

PRESENTING CLINICAL SIGNS

History: continuous straining to defecate but having normal BM concern for primary GI dz vs prostaefecal neg Current meds Tylan powder

ULTRASONOGRAPHIC EXAMINATION OF THE ABDOMEN

Urinary System

The **urinary bladder**, trigone, and pelvic urethra presented normal thicknesses and normal tone. The ureters were not visible which is normal. No uroliths or sediment were visualized, and anechoic urine was present. No evidence of inflammatory or neoplastic changes were noted. Ureteral papillae were normal. Iliac trifurcation was unremarkable.

The **prostate** was uniform. The prostate was slightly enlarged for a neutered male, measuring 2.0 cm.

The **kidneys** revealed normal size and structure, corticomedullary definition and ratio for this age. The cortices presented largely uniform texture with normal echogenic relationship to liver and spleen. Medullary structure differed distinctly from the cortex and no evidence of pelvic dilation was present. The capsules were acceptably uniform without significant irregularities. The right kidney measured 6.4 cm. The left kidney measured 6.84 cm.

Adrenal Glands

The **right adrenal gland** was slightly enlarged, measuring 2.71 cm x 1.51 cm at the cranial pole and 1.16 cm at the caudal pole.

The **left adrenal gland** was normal in size and contour, measuring 2.54 cm x 0.65 cm at the caudal pole and 0.73 cm at the cranial pole.

Spleen

The **spleen** presented a smooth homogeneous parenchyma hyperechoic to liver and renal cortical parenchyma. The capsule was smooth without noticeable expansion or deviation from within the spleen or adjacent pathology. The splenic vasculature demonstrated normal volume without signs of congestion or thrombosis. No sonographic evidence of acute or chronic inflammatory, neoplastic, or infarctual changes were noted.

Liver

The **liver** images submitted revealed subjectively normal liver size, contour, and structure. Parenchymal echogenicity was naturally coarse and hypoechoic to the spleen. Vascular and biliary tracts were of normal volume with no evidence of congestion. The gallbladder presented acceptably thin walls with primarily anechoic content. The cystic and common bile ducts were normal. No pathological hepatic lymphadenopathy was evident. No overt structural evidence of inflammatory, infiltrative or regenerative pathology was evident.

Gastrointestinal

Examination of the **gastrointestinal tract** revealed a stomach and intestine free of stasis, of normal wall thickness, acceptable curvilinear mural detail, and peristaltic activity. Small and large intestine demonstrated normal luminal chyme and stool consistency respectively. No obstructive or overt infiltrative disease was noted. No associated abnormal lymphatic activity was noted. The descending colon was unremarkable.



PATIENT

Pancreas

Bullet Almeida

The base and limbs of the **pancreas** were observed to be largely isoechoic to surrounding omental fat. Pancreatic duct and capsular contour were acceptably normal and parenchyma respected normal curvilinear patterns. No overt evidence of active inflammatory or neoplastic disease was noted.

SPECIES

Canine

ULTRASONOGRAPHIC FINDINGS

- Enlarged right adrenal gland
- Prominent prostate

BREED

German Shepherd

INTERPRETATION OF THE FINDINGS & FURTHER RECOMMENDATIONS

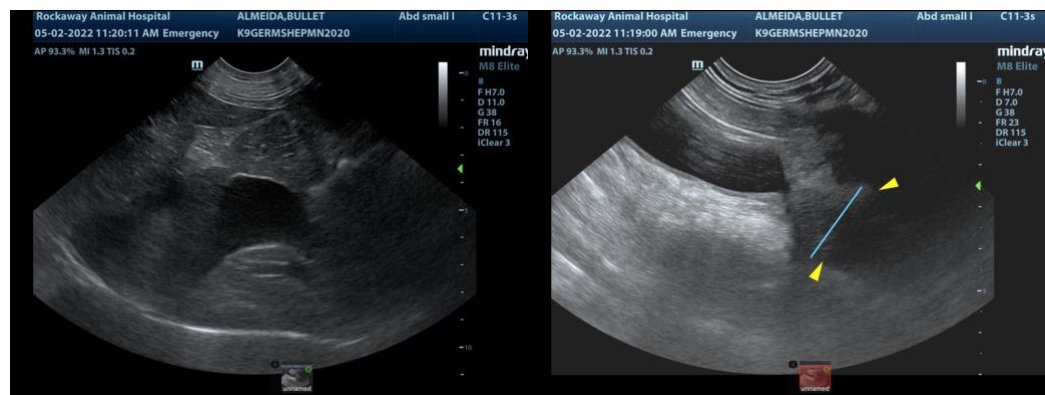
SEX

Regarding the prostate, if recently neutered, this would be a normal variant, however, if straining to urinate is an issue, then traumatic catheterization and ultrasound guided FNA indicated. However, it would be odd to have prostatic neoplasia at this age.

Neutered Male

AGE

2 Years



WEIGHT

96 Pounds

INTERPRETED BY

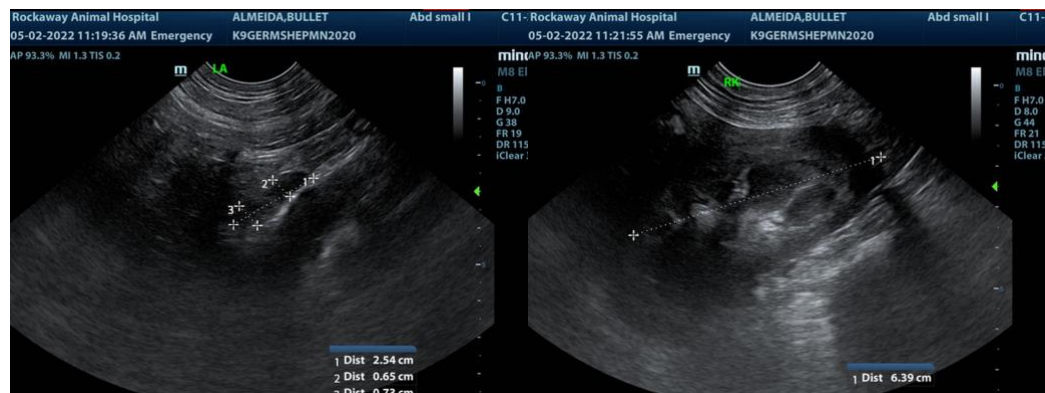
Eric Lindquist, DMV
DABVP, Cert. IVUSS

IMAGING PERFORMED BY

Jenn

HOSPITAL NAME

Rockway AH



REFERRING VET

Dr. Maniar

INVOICE

15004

DATE

5/2/22



PATIENT

Bullet Almeida

SPECIES

Canine

BREED

German Shepherd

SEX

Neutered Male

AGE

2 Years

WEIGHT

96 Pounds

INTERPRETED BY

Eric Lindquist, DMV
DABVP, Cert. IVUSS

IMAGING PERFORMED BY

Jenn

HOSPITAL NAME

Rockaway AH

REFERRING VET

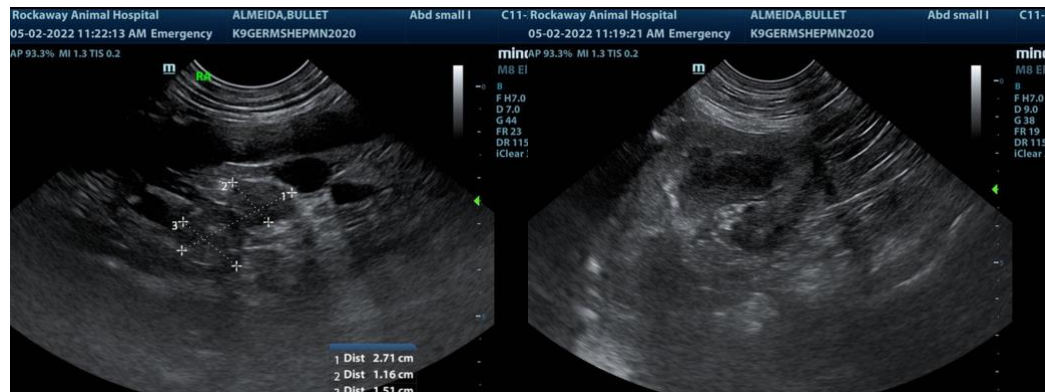
Dr. Maniar

INVOICE

15004

DATE

5/2/22



The information and recommendations provided are based on the images presented by the referring veterinarian. No evaluation can be communicated regarding pathology that was not visible in the image/video clips provided.

Thank you for this referral. If the clinical or image interpretation does not parallel your findings or if I can be of any further assistance please contact me.

Eric Lindquist, DMV, DABVP, Cert. IVUSS, CEO of SonoPath.com
info@SonoPath.com