



PATIENT

Binxie Lukasiak

SPECIES

Feline

BREED

DSH

SEX

FS

AGE

4 years

WEIGHT

4.8

INTERPRETED BY

Eric Lindquist, DMV
DABVP, Cert. IVUSS

IMAGING PERFORMED BY

Micahel Roppolo

HOSPITAL NAME

Pennsauken Animal
Hospital and Urgent
Care

REFERRING VET

Dr. Roppolo

INVOICE

10511ag

DATE

05/02/2022

PRESENTING CLINICAL SIGNS

History: Wellness exam with annual screening bloodwork - no concerns of clinical signs of disease reported at home.

Abnormal PE/Chem/CBC/UA Results: Chemistry revealed mildly elevated GGT(7). 2 week recheck GGT revealed moderate to marked increase at 33 U/L. No change or emergence of any clinical signs reported at home.

ULTRASONOGRAPHIC EXAMINATION OF THE ABDOMEN

Urinary System

The urinary bladder, trigone, and pelvic urethra presented normal thicknesses and normal tone to a depth of 2 cm. The ureters were not visible which is normal. A trace amount of suspended dependent debris was noted in a grouping that measured approximately 7 mm. No evidence of inflammatory or neoplastic changes were noted. Ureteral papillae were normal.

The kidneys revealed normal size and structure, corticomedullary definition and ratio for this age. The cortices presented largely uniform texture with normal echogenic relationship to liver and spleen. Medullary structure differed distinctly from the cortex and no evidence of pelvic dilation was present. The capsules were acceptably uniform without significant irregularities. The left kidney measured 3.5 cm in length. The right kidney measured 3.5 cm in length.

Adrenal Glands

Both adrenal glands were visualized and recognized as having normal shape, size, position and echogenicity for this breed. The phrenic vasculature, glandular echogenicity and detail were unremarkable. Capsule, cortex, and medullary definition were normal for this age patient. The left adrenal gland measured 0.4 cm. The right adrenal gland measured 0.5 cm.

Spleen

The spleen presented a smooth homogeneous parenchyma hyperechoic to liver and renal cortical parenchyma. The capsule was smooth without noticeable expansion or deviation from within the spleen or adjacent pathology. The splenic vasculature demonstrated normal volume without signs of congestion or thrombosis. No sonographic evidence of acute or chronic inflammatory, neoplastic, or infarctual changes were noted.

Liver

The liver images submitted revealed subjectively normal liver size, contour, and structure. Parenchymal echogenicity was naturally coarse and hypoechoic to the spleen. Vascular and biliary tracts were of normal volume with no evidence of congestion. The gallbladder presented acceptably thin walls with primarily anechoic content. The cystic and common bile ducts were normal. No pathological hepatic lymphadenopathy was evident. No overt structural evidence of inflammatory, infiltrative or regenerative pathology was evident.

Gastrointestinal

Examination of the gastrointestinal tract revealed a stomach and intestine free of stasis, of normal wall thickness, acceptable curvilinear mural detail, and peristaltic activity. Small and large intestine demonstrated normal luminal chyme and stool consistency respectively. No obstructive or overt infiltrative disease was noted. No associated abnormal lymphatic activity was noted.



PATIENT

Binxie Lukasiak

SPECIES

Feline

BREED

DSH

SEX

FS

AGE

4 years

WEIGHT

4.8

INTERPRETED BY

Eric Lindquist, DMV
DABVP, Cert. IVUSS

IMAGING PERFORMED BY

Micahel Roppolo

HOSPITAL NAME

Pennsauken Animal
Hospital and Urgent
Care

REFERRING VET

Dr. Roppolo

INVOICE

10511ag

DATE

05/02/2022

Pancreas

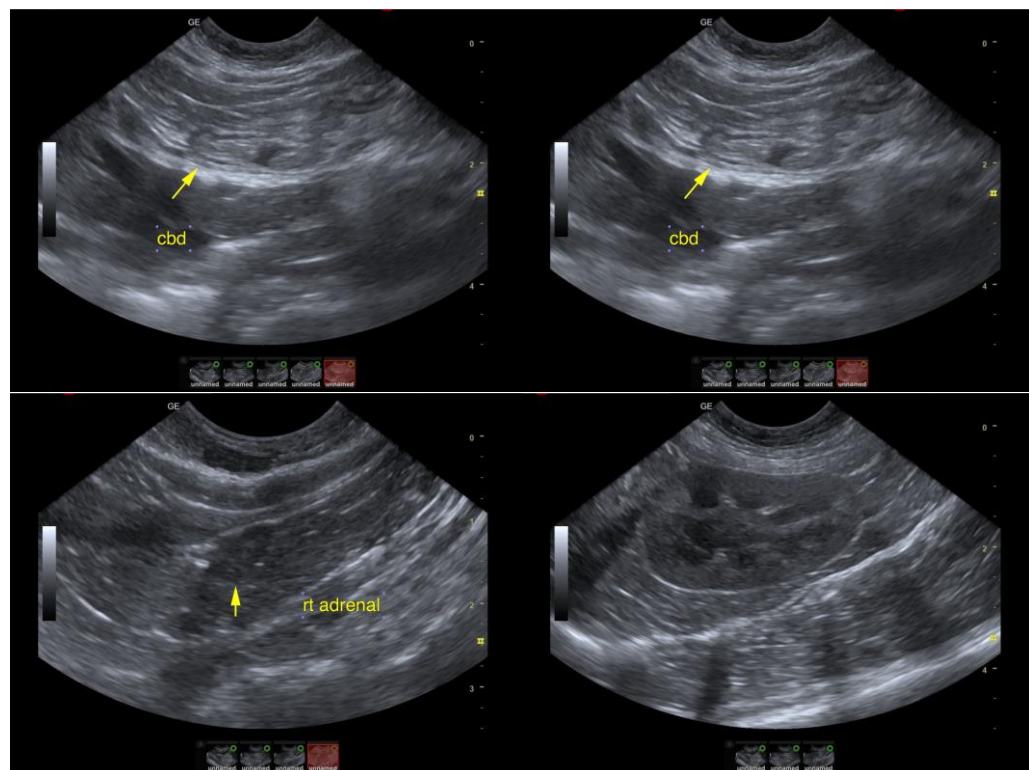
The base and limbs of the pancreas were observed to be largely isoechoic to surrounding omental fat. Pancreatic duct and capsular contour were acceptably normal, and parenchyma respected normal curvilinear patterns. No overt evidence of active inflammatory or neoplastic disease was noted.

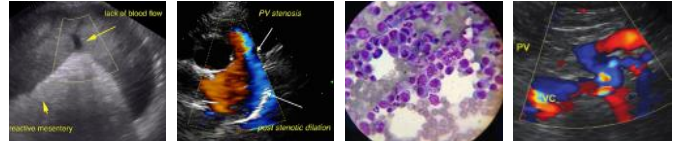
ULTRASONOGRAPHIC FINDINGS

- Minor bladder debris

INTERPRETATION OF THE FINDINGS & FURTHER RECOMMENDATIONS

Minor bladder debris was noted on this study. Otherwise, a sonographically unremarkable abdomen.





PATIENT

Binxie Lukasiak

SPECIES

Feline

BREED

DSH

SEX

FS

AGE

4 years

WEIGHT

4.8

INTERPRETED BY

Eric Lindquist, DMV
DABVP, Cert. IVUSS

**IMAGING
PERFORMED BY**

Micahel Roppolo

HOSPITAL NAME

Pennsauken Animal
Hospital and Urgent
Care

REFERRING VET

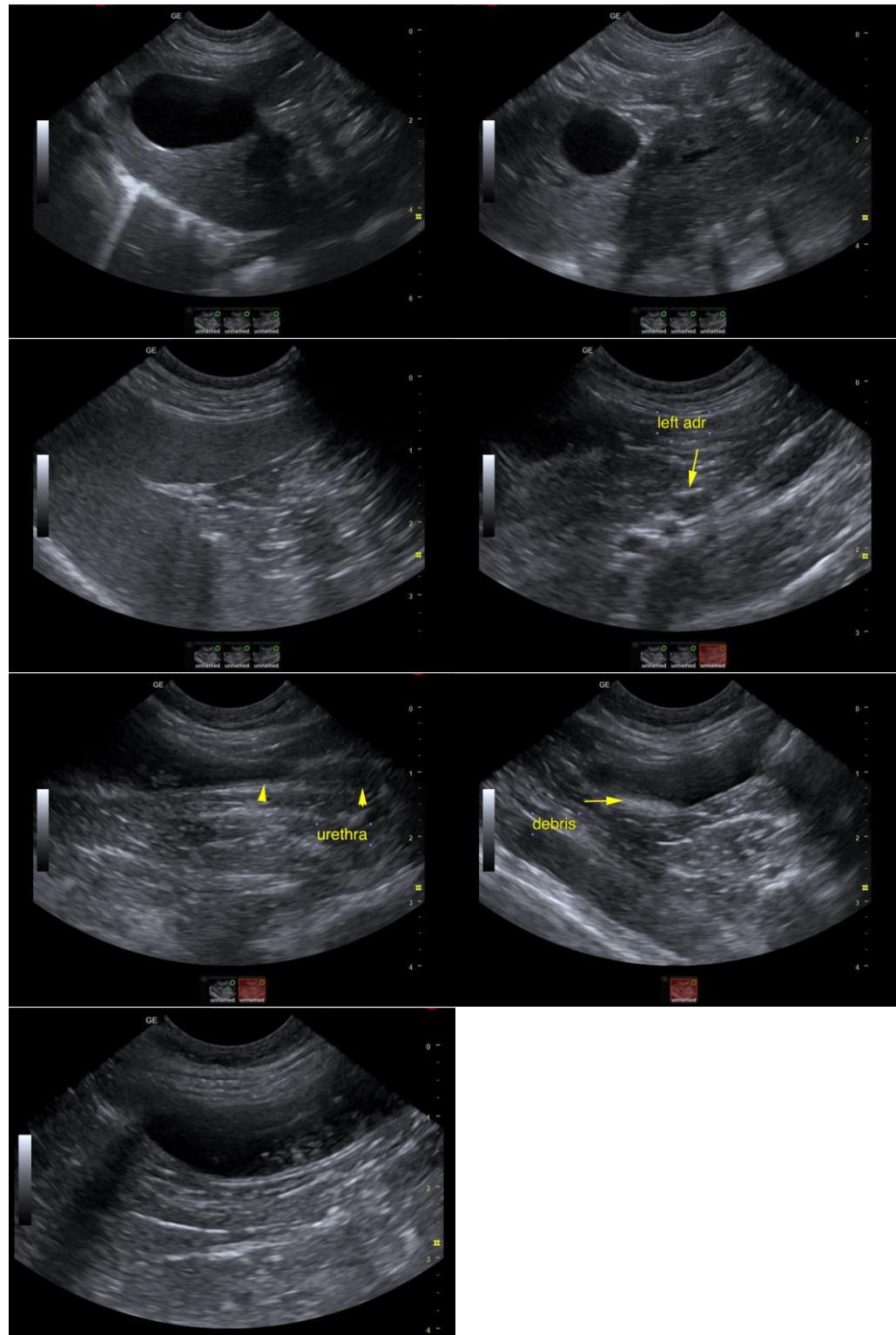
Dr. Roppolo

INVOICE

10511ag

DATE

05/02/2022



The information and recommendations provided are based on the images presented by the referring veterinarian. No evaluation can be communicated regarding pathology that was not visible in the image/video clips provided.



PATIENT

Binxie Lukasiak

Thank you for this referral. If the clinical or image interpretation does not parallel your findings or if I can be of any further assistance please contact me.

SPECIES

Feline

Eric Lindquist, DMV, DABVP, Cert. IVUSS, CEO of SonoPath.com
Eric.Lindquist@SonoPath.com

BREED

DSH

SEX

FS

AGE

4 years

WEIGHT

4.8

INTERPRETED BY

Eric Lindquist, DMV
DABVP, Cert. IVUSS

**IMAGING
PERFORMED BY**

Micahel Roppolo

HOSPITAL NAME

Pennsauken Animal
Hospital and Urgent
Care

REFERRING VET

Dr. Roppolo

INVOICE

10511ag

DATE

05/02/2022