



PATIENT

Bernice Scafani

SPECIES

Canine

BREED

Pekingese

SEX

Spayed Female

AGE

12 Years 2 Months

WEIGHT

15.3 Pounds

INTERPRETED BY

Eric Lindquist, DMV
DABVP, Cert. IVUSS

IMAGING PERFORMED BY

Sarah Green

HOSPITAL NAME

Healing Spirit Animal
Wellness

REFERRING VET

Sarah Green

INVOICE

14993

DATE

5/2/22

PRESENTING CLINICAL SIGNS

History: History of variable appetite, eating dirt. Heart murmur noted on recent exam. Occasional cough, no exercise intolerance

Abnormal PE/Chem/CBC/UA Results: grade iv/vi left apical systolic murmur, no significant abnormalities on CBC, chemistry, T4

ULTRASONOGRAPHIC EXAMINATION OF THE HEART & ABDOMEN

CANINE CARDIAC PARAMETERS	MR VMAX (m/s)	TR VMAX (m/s)	LA/AO (Boon method)	LA/AO (Heart Base; Swe)	FS (%)	EF (%)	EPSS (cm)
NORMAL PARAMETER	4.5-5.5	<2.7	1.3	<1.3	28-40	40-100	<0.6
PATIENT	--	--	1.0	1.6	55	--	0.1
CANINE CARDIAC PARAMETERS	HR (BPM)	AV VMAX (m/s)	PV MAX (m/s)	BODY WEIGHT (kg)	LA 2D short axis Base view (cm)	LVIDd Avg; 2D and m-mode short axis (cm)	LVIDs Avg; 2D and m-mode short axis (cm)
NORMAL PARAMETER	50-100	0.7-1.7	0.7-1.6				
PATIENT	--	--	.60	--	2.76	2.3	--

Cardiac Presentation

The echocardiogram in this patient demonstrated normal **left atrial** size based on 3 different LA measurement methods. Chamber volumes and echogenicity were normal. The cranial and caudal **mitral** valve leaflets presented vegetative thickening consistent with endocardiosis. Doppler indicated measurable insufficiency. The **left ventricle** presented thicknesses with linear contour and was not dilated nor restricted. The **myocardium** presented normal echogenicity without subjective evidence of significant fibrotic or ischemic disease. **Contractility** of the ventricular walls was adequate and in normal range for this patient evidenced by the fractional shortening measurement and subjective evaluation of the different regions of the myocardium. The **left ventricular outflow** tract demonstrated normal laminar flow and subjective structural integrity. The **right atrium** and auricle revealed normal size, structure and content. No evidence of masses was noted or chamber overload. **Tricuspid** valvular assessment demonstrated adequate linear morphology. The **right ventricle** was of normal size (1/3 diameter of LV), chordae structure, myocardial echogenicity and thickness. **Pulmonic** tract assessment revealed normal valve structure, laminar flow, and diameter (approx.1:1 pa/ao ratio). No visible **pericardial** or free pleura fluid was noted. No echographically detectable evidence of infiltrative disease was visible. The cranial **mediastinum and pericardial regions** were free of masses in the visible window.

Urinary System



PATIENT

Bernice Scafani

The **urinary bladder**, trigone, and pelvic urethra presented normal thicknesses and normal tone. The ureters were not visible which is normal. No uroliths or sediment were visualized, and anechoic urine was present. No evidence of inflammatory or neoplastic changes were noted. Ureteral papillae were normal.

SPECIES

Canine

Mild to moderate degenerative changes were noted in the **left kidney**. Cortical medullary mineralization was noted. An anechoic cyst (2.5 cm) was noted in the left kidney. Pyelectasia was noted in the left kidney. The left kidney measured 5.0 cm.

BREED

Pekingese

The **right kidney** revealed normal size and structure, corticomedullary definition and ratio for this age. The cortices presented largely uniform texture with normal echogenic relationship to liver and spleen. Medullary structure differed distinctly from the cortex and no evidence of pelvic dilation was present. The capsules were acceptably uniform without significant irregularities. The right kidney measured 5.0 cm.

SEX

Spayed Female

Adrenal Glands

Both **adrenal glands** were visualized and recognized as having normal shape, size, position and echogenicity for this breed. The phrenic vasculature, glandular echogenicity and detail were unremarkable. Capsule, cortex, and medullary definition were normal for this age patient. The left adrenal gland measured 0.4 cm. The right adrenal gland measured 0.6 cm.

AGE

12 Years 2 Months

WEIGHT

15.3 Pounds

Spleen

The **spleen** presented a smooth homogeneous parenchyma hyperechoic to liver and renal cortical parenchyma. The capsule was smooth without noticeable expansion or deviation from within the spleen or adjacent pathology. The splenic vasculature demonstrated normal volume without signs of congestion or thrombosis. No sonographic evidence of acute or chronic inflammatory, neoplastic, or infarctual changes were noted.

INTERPRETED BY

Eric Lindquist, DMV
DABVP, Cert. IVUSS

Liver

The **liver** images submitted revealed subjectively normal liver size, contour, and structure. Parenchymal echogenicity was naturally coarse and hypoechoic to the spleen. Vascular and biliary tracts were of normal volume with no evidence of congestion. The gallbladder presented acceptably thin walls with primarily anechoic content. The cystic and common bile ducts were normal. No pathological hepatic lymphadenopathy was evident. No overt structural evidence of inflammatory, infiltrative or regenerative pathology was evident.

IMAGING PERFORMED BY

Sarah Green

HOSPITAL NAME

Healing Spirit Animal
Wellness

Gastrointestinal

Some retention of ingesta was noted in the **stomach** and slight shadowing (5.0 mm) structures, consistent with medications. The small intestine and colon were unremarkable.

REFERRING VET

Sarah Green

Pancreas

Minor heterogeneous **pancreatic** changes were noted in the right limb yet no evidence of any significant inflammation.

INVOICE

14993

ULTRASONOGRAPHIC FINDINGS

- Stage B-1 valvular disease, compensated at this time
- Moderate degenerative left renal changes, benign cyst and pyelectasia
- Stomach ingesta

DATE

5/2/22



PATIENT

Bernice Scafani

- Heterogeneous right limb of the pancreas
- Unremarkable abdomen otherwise

INTERPRETATION OF THE FINDINGS & FURTHER RECOMMENDATIONS

The cough is noncardiogenic in this patient. Blood pressure measurements recommended.

SPECIES

Canine

BREED

Pekingese

SEX

Spayed Female

AGE

12 Years 2 Months

WEIGHT

15.3 Pounds

INTERPRETED BY

Eric Lindquist, DMV
DABVP, Cert. IVUSS

IMAGING PERFORMED BY

Sarah Green

HOSPITAL NAME

Healing Spirit Animal
Wellness

REFERRING VET

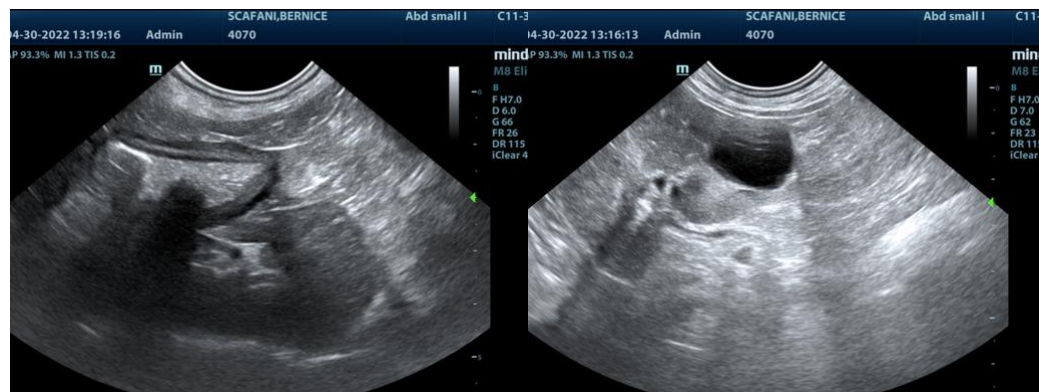
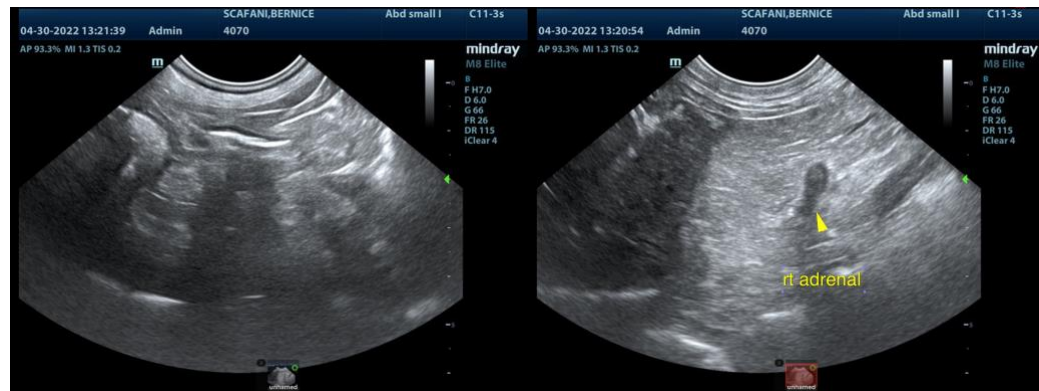
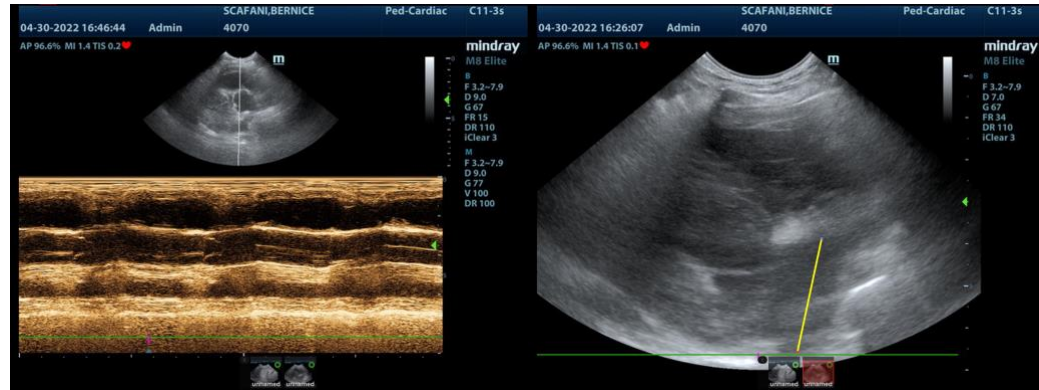
Sarah Green

INVOICE

14993

DATE

5/2/22





PATIENT

Bernice Scafani

SPECIES

Canine

BREED

Pekingese

SEX

Spayed Female

AGE

12 Years 2 Months

WEIGHT

15.3 Pounds

INTERPRETED BY

Eric Lindquist, DMV
DABVP, Cert. IVUSS

IMAGING PERFORMED BY

Sarah Green

HOSPITAL NAME

Healing Spirit Animal
Wellness

REFERRING VET

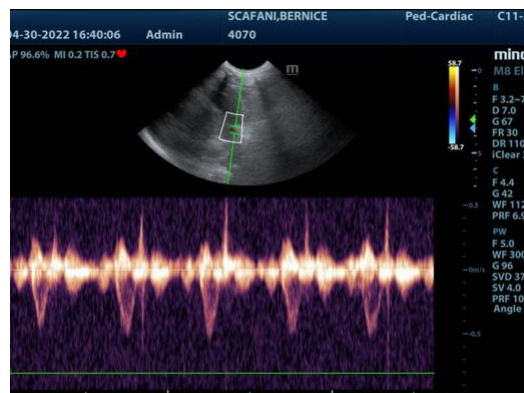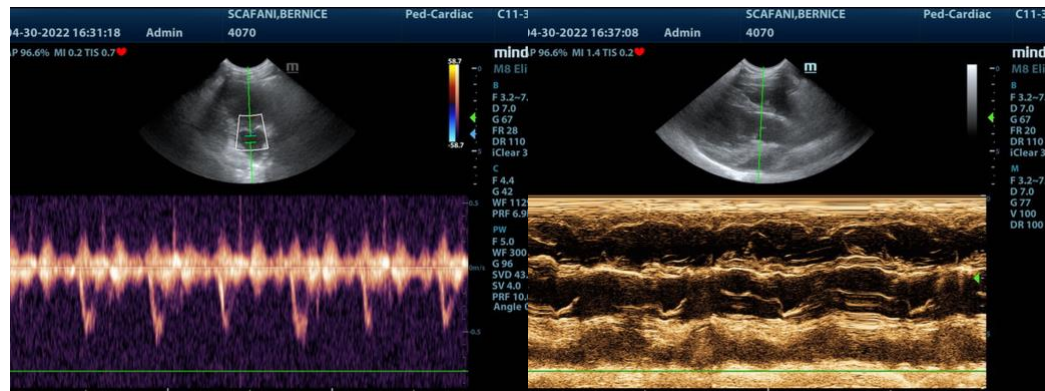
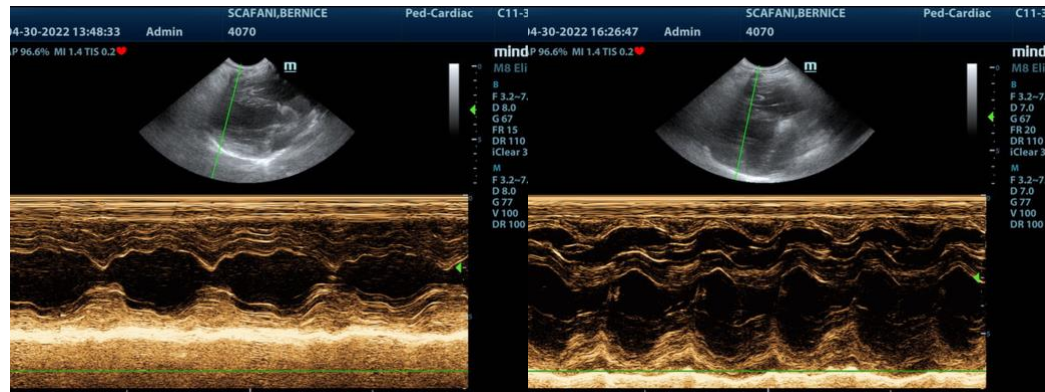
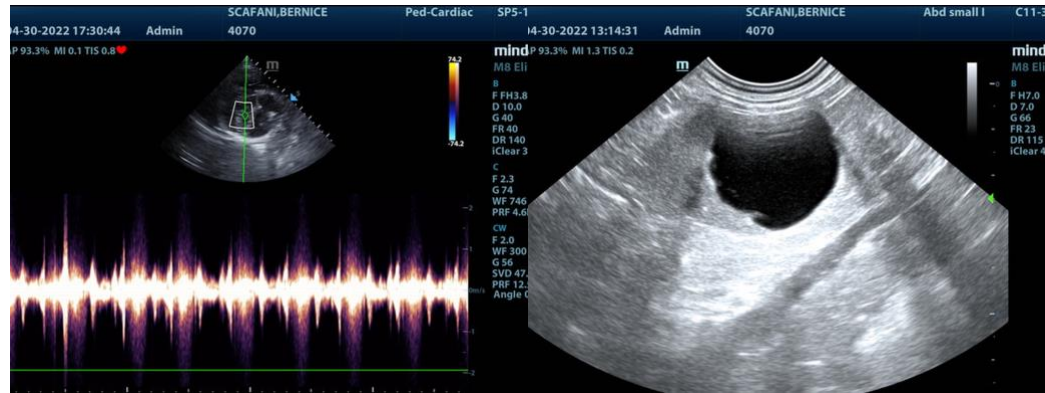Sarah Green

INVOICE

14993

DATE

5/2/22



The information and recommendations provided are based on the images presented by the



PATIENT

Bernice Scafani

referring veterinarian. No evaluation can be communicated regarding pathology that was not visible in the image/video clips provided.

SPECIES

Canine

Thank you for this referral. If the clinical or image interpretation does not parallel your findings or if I can be of any further assistance please contact me.

BREED

Pekingese

Eric Lindquist, DMV, DABVP, Cert. IVUSS, CEO of SonoPath.com

info@SonoPath.com

SEX

Spayed Female

AGE

12 Years 2 Months

WEIGHT

15.3 Pounds

INTERPRETED BY

Eric Lindquist, DMV
DABVP, Cert. IVUSS

**IMAGING
PERFORMED BY**

Sarah Green

HOSPITAL NAME

Healing Spirit Animal
Wellness

REFERRING VET

Sarah Green

INVOICE

14993

DATE

5/2/22