



PATIENT PRESENTING CLINICAL SIGNS

Annie Zak
 New client - currently on Enalapril 5mgs SID, Lasix 2.5 mgs SID for heart murmur, never worked up. Recommended echo to evaluate more thoroughly due to recent suspect episodes of syncope. Abnormal PE/Chem/CBC/UA Results: Blood work done in 12/21: K+ 6.1, Na:K 25, Na 152.

SPECIES

Canine

ULTRASONOGRAPHIC EXAMINATION OF THE HEART

BREED

Cavachon

SEX

Spayed Female

AGE

11 years

The echocardiogram in this patient demonstrated severe **left atrial** enlargement based on 3 different LA measurement methods. Ruptured chordae tendineae and **mitral** valve prolapse was noted. Doppler indicated measurable insufficiency. The **left ventricle** presented thicknesses with linear contour and was not dilated nor restricted. The **myocardium** presented normal echogenicity without subjective evidence of significant fibrotic or ischemic disease. **Contractility** of the ventricular walls was adequate and in normal range for this patient evidenced by the fractional shortening measurement and subjective evaluation of the different regions of the myocardium. The **left ventricular outflow** tract demonstrated normal laminar flow and subjective structural integrity. The **right atrium** and auricle revealed normal size, structure and content. No evidence of masses was noted or chamber overload. **Tricuspid** valvular assessment demonstrated adequate linear morphology. The **right ventricle** was of normal size (1/3 diameter of LV), chordae structure, myocardial echogenicity and thickness. **Pulmonic** insufficiency was noted. A slight amount of **pericardial** effusion was noted.

WEIGHT

17.6 lbs

CANINE CARDIAC PARAMETERS	MR VMAX (m/s)	TR VMAX (m/s)	LA/AO (Boon method)	LA/AO (Heart Base; Swe)	FS (%)	EF (%)	EPSS (cm)
NORMAL PARAMETER	4.5-5.5	<2.7	1.3	<1.3	28-40	40-100	<0.6
PATIENT	6.0	4.0	2.5	> 3.0	44	76	0.1
CANINE CARDIAC PARAMETERS	HR (BPM)	AV VMAX (m/s)	PV MAX (m/s)	BODY WEIGHT	LA 2D short axis Base view (cm)	LVIDd Avg; 2D and m- mode short axis (cm)	LVIDs Avg; 2D and m-mode short axis (cm)
NORMAL PARAMETER	50-100	0.7-1.7	0.7-1.6				
PATIENT	113	1.5		17.6 lbs	5.18	3.85	

INTERPRETED BY

Eric Lindquist, DMV,
 DABVP, Cert. IVUSS,
 CEO of SonoPath.com

**IMAGING
PERFORMED BY**

Kelly Vazquez, CVT

HOSPITAL NAME

Midland Park VH

REFERRING VET

Dr. Shokoff

ULTRASONOGRAPHIC FINDINGS

Advanced Stage C1-D1 valvular disease with ruptured chordae tendineae and severe mitral prolapse.

INVOICE

30061

Volume overload of left and right heart with emerging right-sided heart failure and pulmonary hypertension.

DATE

5/2/22



PATIENT

Annie Zak

SPECIES

Canine

BREED

Cavachon

SEX

Spayed Female

AGE

11 years

WEIGHT

17.6 lbs

INTERPRETED BY

Eric Lindquist, DMV,
DABVP, Cert. IVUSS,
CEO of SonoPath.com

IMAGING PERFORMED BY

Kelly Vazquez, CVT

HOSPITAL NAME

Midland Park VH

REFERRING VET

Dr. Shokoff

INVOICE

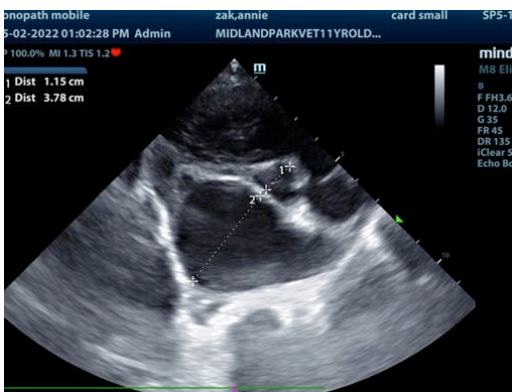
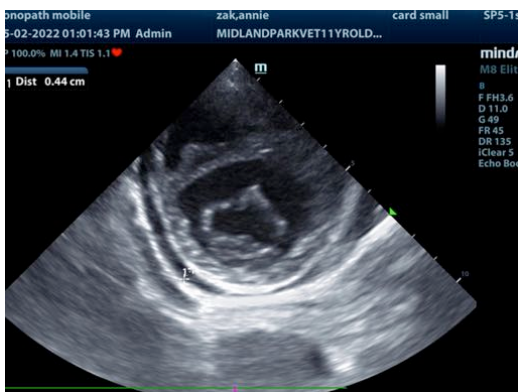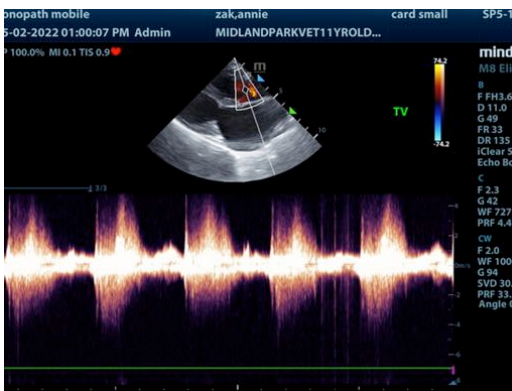
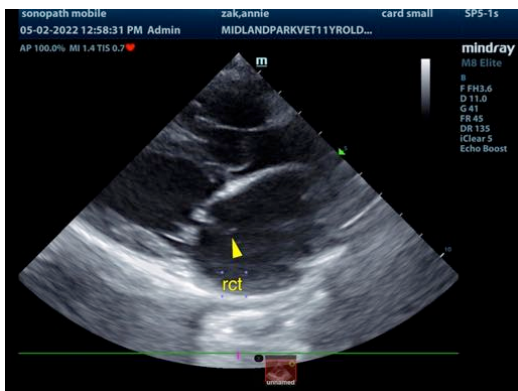
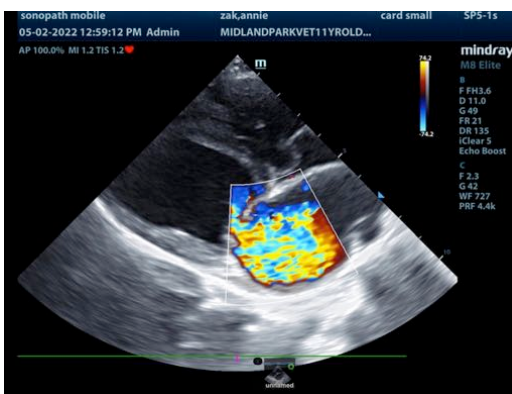
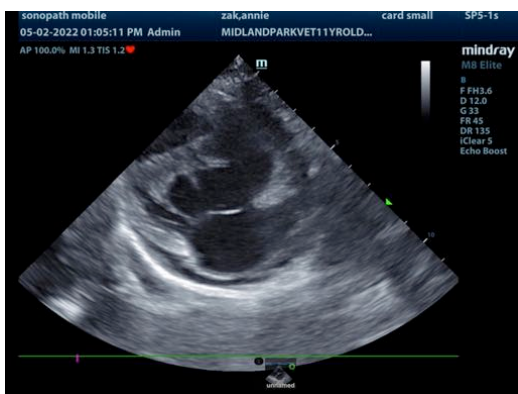
30061

DATE

5/2/22

INTERPRETATION OF THE FINDINGS & FURTHER RECOMMENDATIONS

The pericardial effusion is likely owing to chronic right-sided failure. This patient is in a very precarious position. I recommend adding Pimobendan at 0.3 mg/kg b.i.d. maximizing ace inhibitor at 0.5 mg/kg b.i.d., Lasix 2-4 mg/kg b.i.d., Spironolactone at 1-2 mg/kg b.i.d. with a recheck echocardiogram in a week. Eventual addition of Sildenafil can be considered. Recheck echocardiogram is recommended in a week. The patient is at high risk for sudden death.





PATIENT

Annie Zak

SPECIES

Canine

BREED

Cavachon

SEX

Spayed Female

AGE

11 years

WEIGHT

17.6 lbs

INTERPRETED BY

Eric Lindquist, DMV,
DABVP, Cert. IVUSS,
CEO of SonoPath.com

**IMAGING
PERFORMED BY**

Kelly Vazquez, CVT

HOSPITAL NAME

Midland Park VH

REFERRING VET

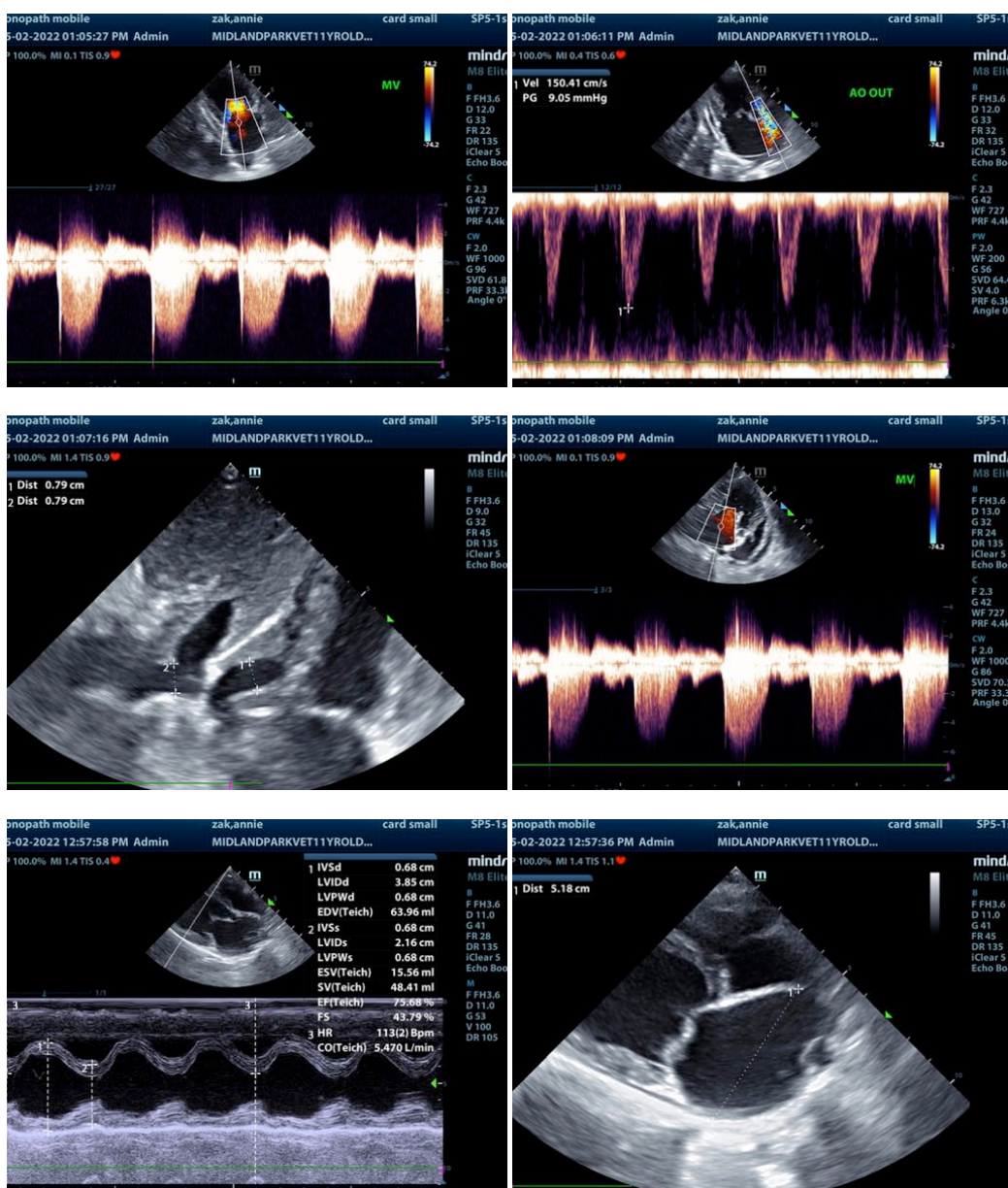
Dr. Shokoff

INVOICE

30061

DATE

5/2/22



The information and recommendations provided are based on the images presented by the referring veterinarian/sonographer. No evaluation can be communicated regarding pathology that was not visible in the image/video clips provided.

Thank you for this referral. If the clinical or image interpretation does not parallel your findings or if I can be of any further assistance please contact me.

Eric Lindquist, DMV, DABVP, Cert. IVUSS, CEO of SonoPath.com

Info@SonoPath.com



PATIENT

Annie Zak

SPECIES

Canine

BREED

Cavachon

SEX

Spayed Female

AGE

11 years

WEIGHT

17.6 lbs

INTERPRETED BY

Eric Lindquist, DMV,
DABVP, Cert. IVUSS,
CEO of SonoPath.com

**IMAGING
PERFORMED BY**

Kelly Vazquez, CVT

HOSPITAL NAME

Midland Park VH

REFERRING VET

Dr. Shokoff

INVOICE

30061

DATE

5/2/22