



PATIENT

Yogi Trueba

SPECIES

Canine

BREED

Morkie Poo

SEX

Spayed female

AGE

12 years

WEIGHT

4.6 kg

INTERPRETED BY

Eric Lindquist, DMV
DABVP, Cert. IVUSS

IMAGING PERFORMED BY

Drew Davis

HOSPITAL NAME

Viking VH

REFERRING VET

Dr. Davis

INVOICE

77722

DATE

5/19/26

PRESENTING CLINICAL SIGNS

History: Presenting Complaint: Yogi presents for ultrasound evaluation of enlarged liver and reassess pancreatitis

Patient History:

- Historical pancreatitis treated April 25th, initially outpatient then hospitalized
- Previously noted enlarged liver and mildly elevated liver enzymes
- Currently fed Royal Canin Gastro diet exclusively
- Previously given famotidine

Abnormal PE/Chem/CBC/UA Results: Diagnostics: - CBC: normal across the board - Chemistry panel: elevated lipase 2253 (improved from April value of 4395; pancreatic lipase 768 (improved from 1011)

ULTRASONOGRAPHIC EXAMINATION OF THE ABDOMEN

Urinary System

The **urinary bladder**, trigone, and pelvic urethra presented normal thicknesses and normal tone. The pelvic urethra was imaged 2.0 cm beyond the cystourethral junction and appeared normal. The ureters were not visible which is normal. No uroliths or sediment were visualized and anechoic urine was present. No evidence of inflammatory or neoplastic changes was noted. Ureteral papillae were normal.

The **kidneys** revealed largely normal size and structure, corticomedullary definition and ratio (cortex 1/3 of medulla) were essentially maintained with some age-related loss of curvilinear patterns regarding the capsule and C/M junction. The cortices presented largely uniform texture with some increased echogenicity expected for this age patient. Medullary structure differed distinctly from that of the cortex and no evidence of pelvic dilation was present. Minor mineralization was noted in the kidneys. The left kidney measured 3.8 cm. The right kidney measured 3.42 cm.

Adrenal Glands

Both **adrenal glands** were visualized and recognized as having normal shape, size, position and echogenicity for this breed. The phrenic vasculature, glandular echogenicity and detail were unremarkable. Capsule, cortex, and medullary definition were normal for this age patient. The left adrenal gland measured 0.5 cm. The right adrenal gland measured 0.6 cm.

Spleen

The **spleen** in this patient was mildly enlarged with uniform parenchyma and was folded upon itself cranially. This is a positional variant and is not pathological. There was no evidence of significant disease.

Liver

The **liver** was uniformly swollen with minor, excessive gallbladder debris and over distension with dependent and suspended bile without evidence of overt mucocele formation. However, excessive sludge was present. The liver presented coarse architecture with mildly increased portal markings and



PATIENT

Yogi Trueba

SPECIES

Canine

BREED

Morkie Poo

SEX

Spayed female

AGE

12 years

WEIGHT

4.6 kg

INTERPRETED BY

Eric Lindquist, DMV
DABVP, Cert. IVUSS

IMAGING PERFORMED BY

Drew Davis

HOSPITAL NAME

Viking VH

REFERRING VET

Dr. Davis

INVOICE

77722

DATE

5/19/26

subtle, mixed echogenic changes. This is consistent with vacuolar hepatopathy and some level of remodeling and history of inflammatory component. There was no overt suspicion of neoplasia.

Gastrointestinal

Examination of the **gastrointestinal tract** revealed a stomach and intestine free of stasis, of normal wall thickness, acceptable curvilinear mural detail, and peristaltic activity. Small and large intestine demonstrated normal luminal chyme and stool consistency respectively. No obstructive or overt infiltrative disease was noted. No associated abnormal lymphatic activity was noted.

Pancreas

The base and limbs of the **pancreas** were observed to be largely isoechoic to surrounding omental fat. Some parenchymal remodeling, however, with mild deviation from curvilinear normalcy was observed. Pancreatic duct and capsular irregularities were present consistent with age related changes. If pain upon imaging (+ Murphy sign) was present or if the patient is focally painful in subxiphoid palpation then low-grade smoldering chronic pancreatitis should be suspected.

ULTRASONOGRAPHIC FINDINGS

Benign hepatopathy, likely reactive hepatopathy.

Age related renal changes.

Pancreatic remodeling, no evidence of active inflammation. However, I cannot rule out minor inflammatory process.

INTERPRETATION OF THE FINDINGS & FURTHER RECOMMENDATIONS

The hepatic clinical sonographic presentation is most consistent with Reactive Hepatopathy which is the most common cause of liver enzyme elevation in dogs and cats. The presumption is that gut and other organ antigen stimuli may be causing a low-grade immune response through portal system with which the liver is reacting to causing low-grade enzyme elevations. US-guided FNA could be performed to assess if low grade lymphoplasmacytic inflammation is present that would support this theory. If FNA is performed, please ask the cytologist to emphasize the primary inflammatory cell type. Empirical treatment measures to address this issue can include diet change to hydrolyzed diet, probiotics, deworming, nutraceuticals (SAME, Actigall...), dental exam and cleaning, and potentially antibiotics such as Clavamox. Metronidazole and Tylosin have traditionally been utilized for this purpose but new studies show that both these antibiotics can disrupt the normal intestinal bacterial flora (intestinal dysbiosis) for weeks and up to 4-6 months. Therefore, Metronidazole and Tylosin should be utilized as a last resort if other efforts have not been effective and sonographic organ appearance remains benign.



PATIENT

Yogi Trueba

SPECIES

Canine

BREED

Morkie Poo

SEX

Spayed female

AGE

12 years

WEIGHT

4.6 kg

INTERPRETED BY

Eric Lindquist, DMV
DABVP, Cert. IVUSS

IMAGING PERFORMED BY

Drew Davis

HOSPITAL NAME

Viking VH

REFERRING VET

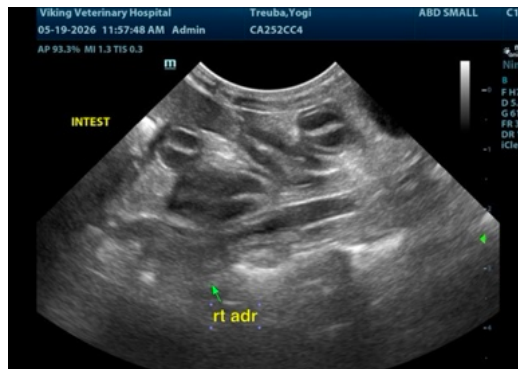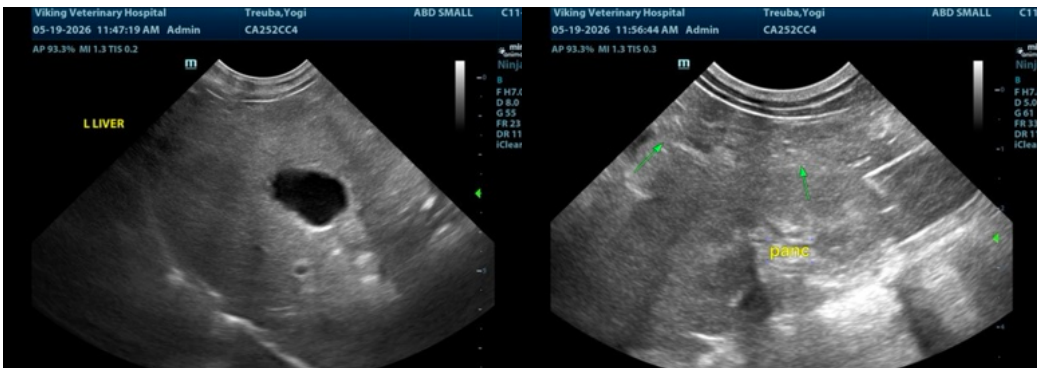
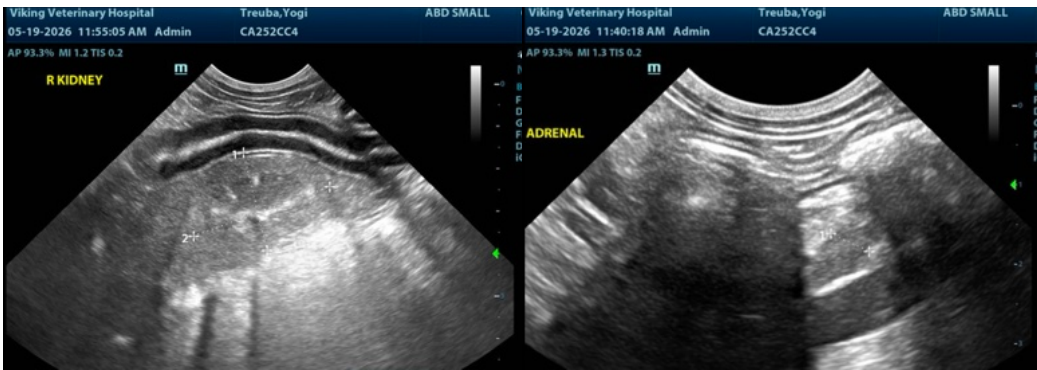
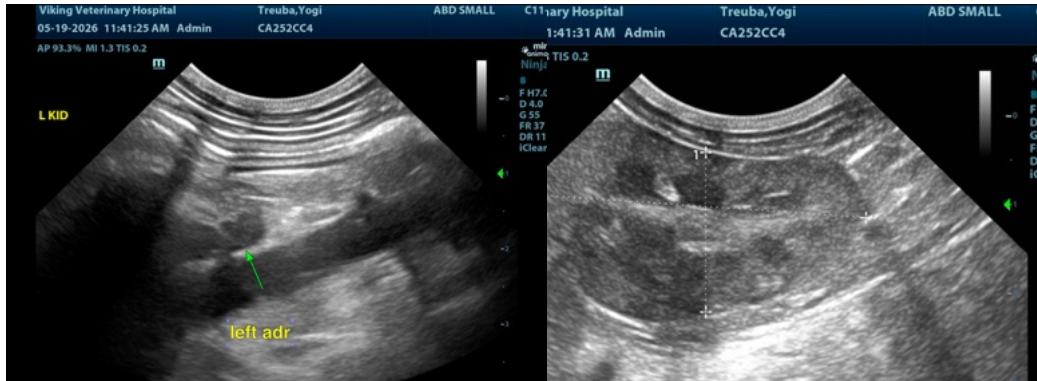
Dr. Davis

INVOICE

77722

DATE

5/19/26





PATIENT

Yogi Trueba

SPECIES

Canine

BREED

Morkie Poo

SEX

Spayed female

AGE

12 years

WEIGHT

4.6 kg

INTERPRETED BY

Eric Lindquist, DMV
DABVP, Cert. IVUSS

IMAGING PERFORMED BY

Drew Davis

HOSPITAL NAME

Viking VH

REFERRING VET

Dr. Davis

INVOICE

77722

DATE

5/19/26

The information and recommendations provided are based on the images presented by the referring veterinarian/sonographer. No evaluation can be communicated regarding pathology that was not visible in the image/video clips provided.

Thank you for this referral. If the clinical or image interpretation does not parallel your findings or if I can be of any further assistance please contact me.

Eric Lindquist, DMV, DABVP (CFM), Cert. IVUSS, CEO of SonoPath.com

info@SonoPath.com