



## PATIENT

Remington Mayer

## SPECIES

Canine

## BREED

Labrador Retriever

## SEX

Male

## AGE

7 Years 8 Months

## WEIGHT

92 Pounds

## INTERPRETED BY

Eric Lindquist, DMV,  
DABVP (CFM), Cert.  
IVUS

## IMAGING PERFORMED BY

Dr. Raul Casas

## HOSPITAL NAME

State Avenue VC

## REFERRING VET

Dr. Raul Casas

## INVOICE

37142

## DATE

5/19/26

## PRESENTING CLINICAL SIGNS

History: Recheck of right thoracic limb lameness; progressive worsening. Right thoracic limb lameness: Progressive worsening, now extending proximally toward shoulder; non-weight bearing at times; more severe today, requires rest after short ambulation. Decreased activity; less responsive to stimuli (e.g., front door). Appetite decreased, especially when pain is increased; drinking normal. Previous ear infection treated; ongoing ear flush.

Current medications: Carprofen, Seizure meds, OTC bone/joint supplement, Ear flush

Abnormal PE/Chem/CBC/UA Results: Decreased activity, Right thoracic limb: marked swelling and firm tissue palpated, consistent with edema; thickening noted; limping, worsened today. Ambulation: prefers recumbency after short periods standing.

## LIMITED ULTRASONOGRAPHIC EXAMINATION

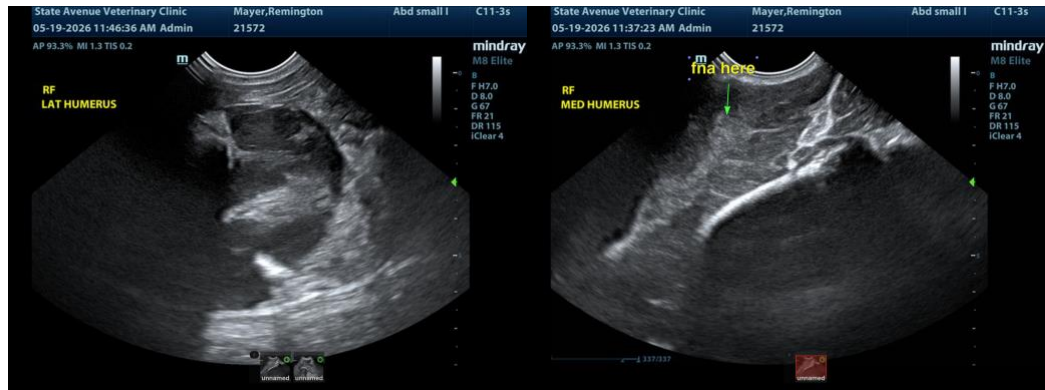
The humerus in this patient revealed a soft tissue mass involving muscle, extending proximally and distally from subcutaneous space to periosteum over the humerus, strongly suggestive for muscle-based sarcoma.

## ULTRASONOGRAPHIC FINDINGS

- Muscle-based mass- sarcoma is suspected

## INTERPRETATION OF THE FINDINGS & FURTHER RECOMMENDATIONS

FNA of the mass is warranted to confirm sarcoma. Chest radiographs and abdominal sonogram are warranted to assess for metastatic disease.





**PATIENT**

Remington Mayer

**SPECIES**

Canine

**BREED**

Labrador Retriever

**SEX**

Male

**AGE**

7 Years 8 Months

**WEIGHT**

92 Pounds

**INTERPRETED BY**

Eric Lindquist, DMV,  
DABVP (CFM), Cert. IVUSS

**IMAGING PERFORMED BY**

Dr. Raul Casas

**HOSPITAL NAME**

State Avenue VC

**REFERRING VET**

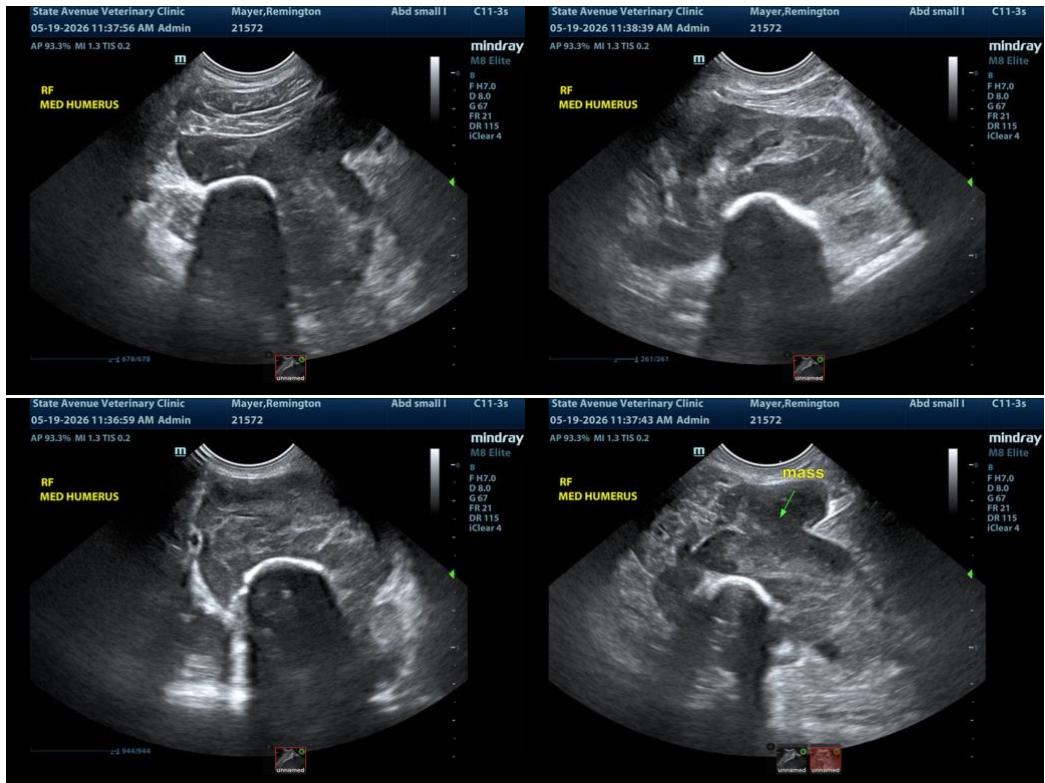
Dr. Raul Casas

**INVOICE**

37142

**DATE**

5/19/26



The information and recommendations provided are based on the images presented by the referring veterinarian/sonographer. No evaluation can be communicated regarding pathology that was not visible in the image/video clips provided.

Thank you for this referral. If the clinical or image interpretation does not parallel your findings or if I can be of any further assistance please contact me.

Eric Lindquist, DMV, DABVP(CFM), Cert. IVUSS,  
CEO, Owner, Founder -- SonoPath.com  
[info@SonoPath.com](mailto:info@SonoPath.com)