



**PATIENT**

Mustache Raper

**SPECIES**

Feline

**BREED**

DSH

**SEX**

Neutered Male

**AGE**

9 Years 1 Month

**WEIGHT**

13.1 lbs

**INTERPRETED BY**

Eric Lindquist, DMV,  
DABVP (CFM), Cert.  
IVUSS

**IMAGING PERFORMED BY**

Vincent Ravancho, CVT

**HOSPITAL NAME**

Denville Animal  
Hospital

**REFERRING VET**

Dr. Reddy

**INVOICE**

75276

**DATE**

5/19/26

**PRESENTING CLINICAL SIGNS**

Pet to be put under anesthesia for dental. Current medications - Lasix 20mg tabs, Enalapril 5 mg tabs, Clopidogrel 75mg tab

Abnormal PE/Chem/CBC/UA Results: Chloride low, Cholesterol high

**ULTRASONOGRAPHIC EXAMINATION OF THE HEART**

FELINE CARDIAC PARAMETERS	BODY WEIGHT (lbs)	HR (BPM)	IVSd (cm)	LVIDd (cm)	LVWd (cm)	FS (%)	EF (%)
NORMAL PARAMETER	-----	150-240	0.3-0.6	1.0-2.1	0.25-0.6	35-67	80-100
PATIENT	13.1	189	0.77	1.26	0.73	49	84
FELINE CARDIAC PARAMETERS	LA/AO (M-mode)	LA/AO HEART BASE (Sisson)	LAD LA MAX 4 Chamber	LVOT VEL. (m/s)	RVOT VEL. (m/s)	IVRT (m)	
NORMAL PARAMETER	<1.5	1.6	0.7-1.7	<1.6	<1.3	40-60	
PATIENT	1.74	1.4	1.5	1.8	0.9	NM	
Adapted from June Boon, Veterinary Echocardiography, 1998 Sisson D et al. JVIM 1991; 5: 232, Jacobs et al. Am J Vet Res 1985; 46:1705							

E-wave velocity = 0.9

**Cardiac Presentation**

The echocardiogram in this patient demonstrated mildly excessive **left atrial** size with normal structure and no evidence of “smoke” or thrombi. The cranial and caudal **mitral** valve leaflets appeared mildly thickened with some insufficiency noted on Doppler. Mitral insufficiency velocity >4.0 m/sec. The **left ventricle** presented moderate concentric hypertrophy with adequate contractility and normal internal volumes. No systolic anterior motion noted at the time of the sonogram. The **left ventricular outflow** tract demonstrated turbulent laminar flow. Subjective assessment of the **right atrium** and auricle revealed normal size, structure and content. No evidence of masses was noted. **Tricuspid** valvular assessment demonstrated linear morphology. The **right ventricle** was of normal size with normal chordae structure, myocardial echogenicity and thickness. **Pulmonic** tract assessment revealed normal valve structure, laminar flow, and diameter. No visible **pericardial** or free pleura fluid was noted. No echographically detectable evidence of infiltrative disease was visible. The **mediastinum** was free of masses in the visible window.

**ULTRASONOGRAPHIC FINDINGS**

- Mildly excessive left atrial size, left ventricular hypertrophy.
- Mild mitral insufficiency.



**PATIENT**

Mustache Raper

**SPECIES**

Feline

**BREED**

DSH

**SEX**

Neutered Male

**AGE**

9 Years 1 Month

**WEIGHT**

13.1 lbs

**INTERPRETED BY**

Eric Lindquist, DMV,  
 DABVP (CFM), Cert.  
 IVUSS

**IMAGING PERFORMED BY**

Vincent Ravancho, CVT

**HOSPITAL NAME**

Denville Animal  
 Hospital

**REFERRING VET**

Dr. Reddy

**INVOICE**

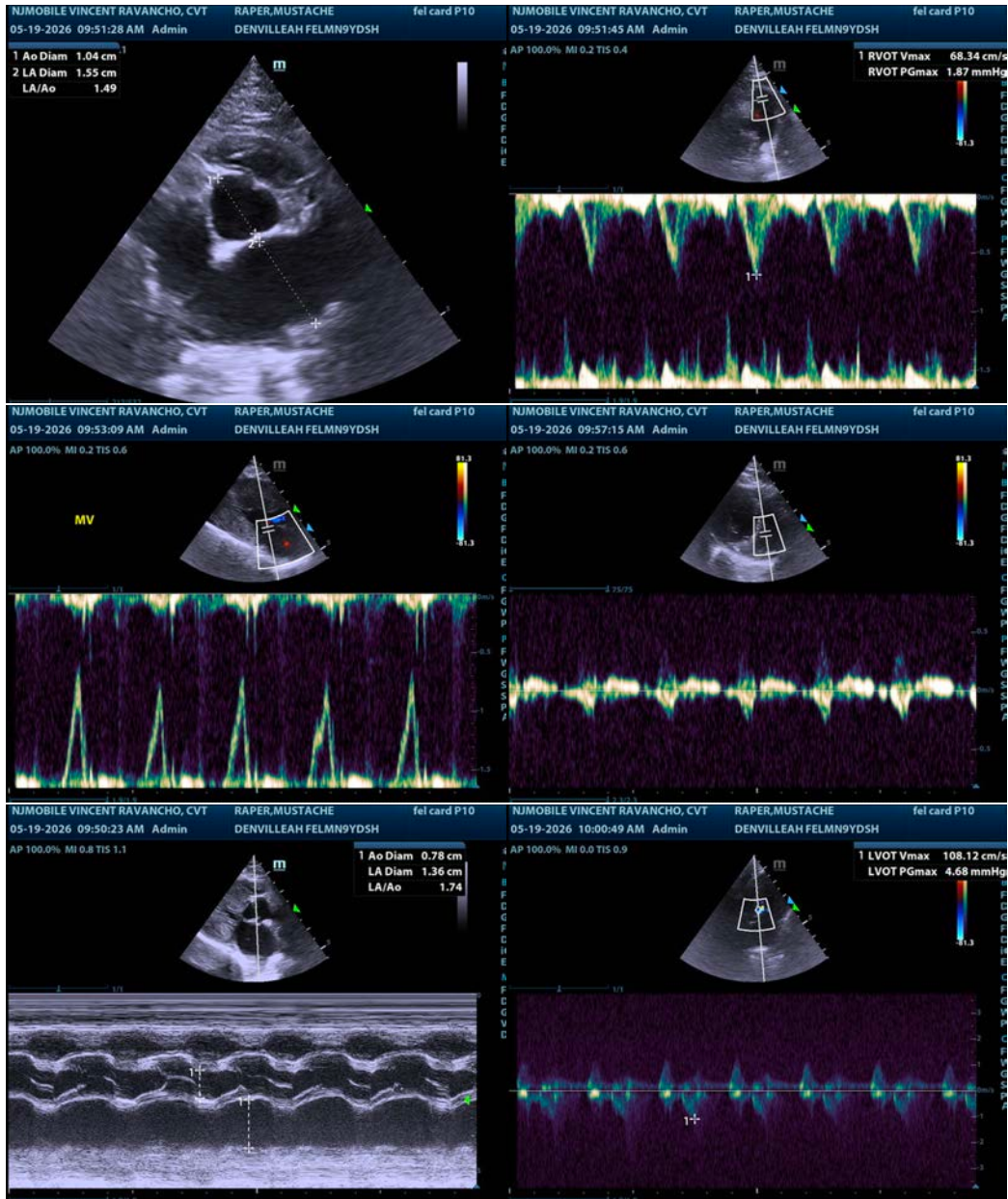
75276

**DATE**

5/19/26

**INTERPRETATION OF THE FINDINGS & FURTHER RECOMMENDATIONS**

Anesthetic risk is minor in this patient. Recommend continuation of current protocol of Lasix, Enalapril and Clopidogrel. Torbutrol pre-med, Propofol induction, Isoflurane maintenance recommended with minimal amount of anesthetic time in this patient. EKG and blood pressures as well as pulse oximetry monitoring are all essential in this patient. Recheck echo in 6-12 months.





**PATIENT**

Mustache Raper

**SPECIES**

Feline

**BREED**

DSH

**SEX**

Neutered Male

**AGE**

9 Years 1 Month

**WEIGHT**

13.1 lbs

**INTERPRETED BY**

Eric Lindquist, DMV,  
DABVP (CFM), Cert.  
IVUSS

**IMAGING PERFORMED BY**

Vincent Ravancho, CVT

**HOSPITAL NAME**

Denville Animal  
Hospital

**REFERRING VET**

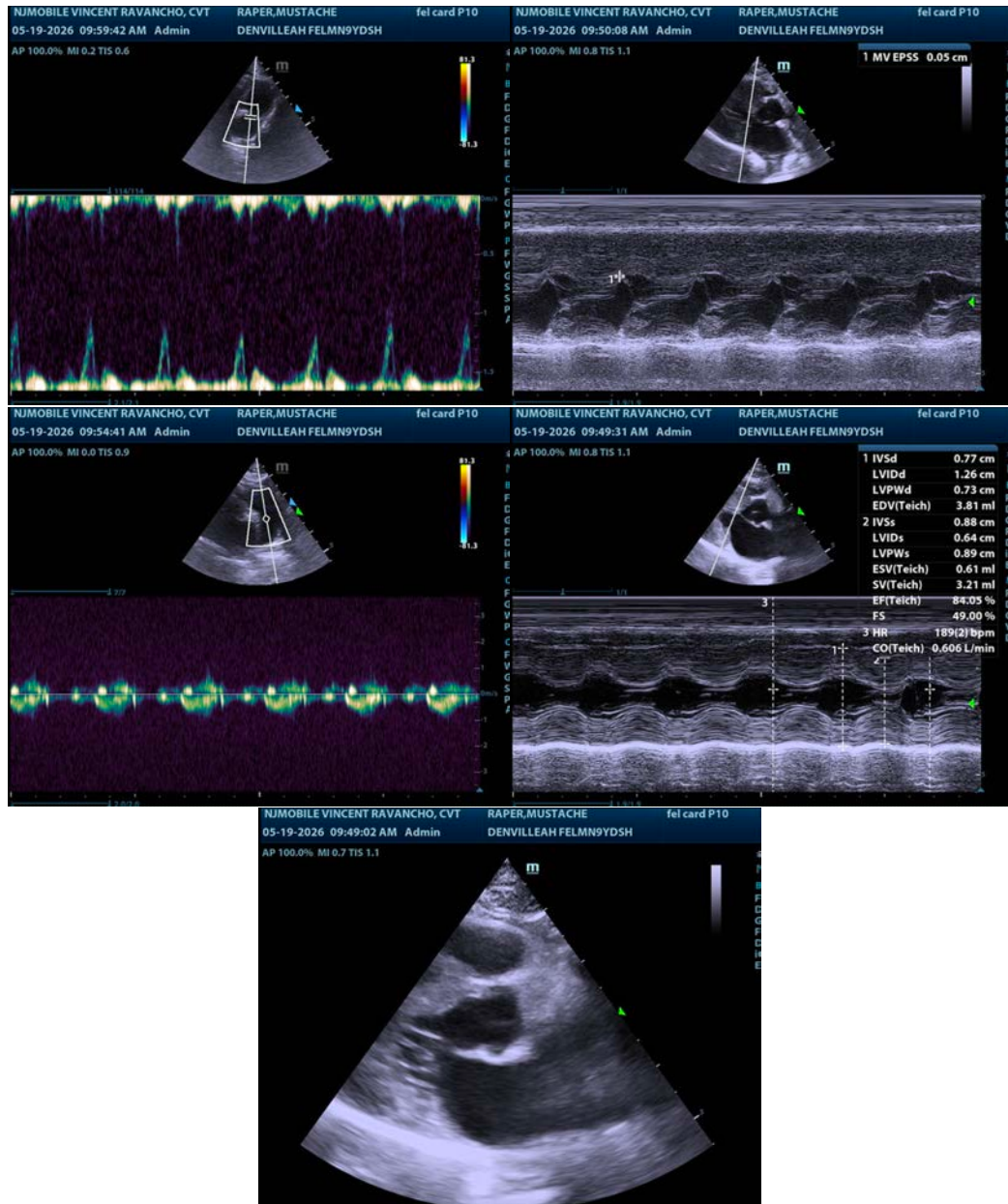
Dr. Reddy

**INVOICE**

75276

**DATE**

5/19/26



The information and recommendations provided are based on the images presented by the referring veterinarian/sonographer. No evaluation can be communicated regarding pathology that was not visible in the image/video clips provided.

Thank you for this referral. If the clinical or image interpretation does not parallel your findings or if I can be of any further assistance please contact me.

**Eric Lindquist, DMV, DABVP(CFM), Cert. IVUSS,**  
CEO, Owner, Founder -- SonoPath.com  
[info@SonoPath.com](mailto:info@SonoPath.com)