



## PATIENT

Freya Al Hetmi

## SPECIES

Feline

## BREED

Sphinx

## SEX

Female

## AGE

2 years

## WEIGHT

2.6 kg

## INTERPRETED BY

Eric Lindquist, DMV  
DABVP, Cert. IVUSS

## IMAGING PERFORMED BY

Dr. Samad Khan

## HOSPITAL NAME

The Veterinary Surgery  
Street 805

## REFERRING VET

Dr. Khan

## INVOICE

77724

## DATE

5/19/26

## PRESENTING CLINICAL SIGNS

History: Freyes repeat echo after starting furosemide and clopidogrel , 6/6 murmur after medication, the intensity of the murmur reduced

## ULTRASONOGRAPHIC EXAMINATION OF THE HEART

The echocardiogram in this patient presented volume overload of the left atrium and left ventricle and tachycardia. The septal and free wall thickness were unremarkable. Severe mitral insufficiency noted with volume overload of the left atrium and left ventricle. The right atrium and right ventricle were unremarkable. There was no pericardial or pleural effusion.

FELINE CARDIAC PARAMETERS	BODY WEIGHT (kg)	HR (BPM)	IVSd (cm)	LVIDd (cm)	LVWd (cm)	FS (%)	EF (%)
NORMAL PARAMETER	-----	150-240	0.3-0.6	1.0-2.1	0.25-0.6	35-67	80-100
PATIENT	2.6 kg	250	0.5	1.7	0.5	NM	NM
FELINE CARDIAC PARAMETERS	LA/AO (M-mode)	LA/AO HEART BASE (Sisson)	LAD LA MAX 4 Chamber		LVOT VEL. (m/s)	RVOT VEL. (m/s)	IVRT (m/)
NORMAL PARAMETER	<1.5	1.6	0.7-1.7		<1.6	<1.3	40-60
PATIENT	1.8	1.9	NM		NM	NM	NM
Adapted from June Boon, Veterinary Echocardiography, 1998 Sisson D et al. JVIM 1991; 5: 232, Jacobs et al. Am J Vet Res 1985; 46:1705							

## ULTRASONOGRAPHIC FINDINGS

Mitral insufficiency.

Left-sided volume overload.

## INTERPRETATION OF THE FINDINGS & FURTHER RECOMMENDATIONS

The changes are consistent with left-sided heart failure. Further imaging is necessary for further definition. I recommend continuation of the Furosemide and Clopidogrel; however, Pimobendan is indicated at 0.3 mg/kg b.i.d. Further imaging is necessary to assess for congenital disease further than mitral insufficiency and volume overload of the left heart.



**PATIENT**

Freya Al Hetmi

**SPECIES**

Feline

**BREED**

Sphinx

**SEX**

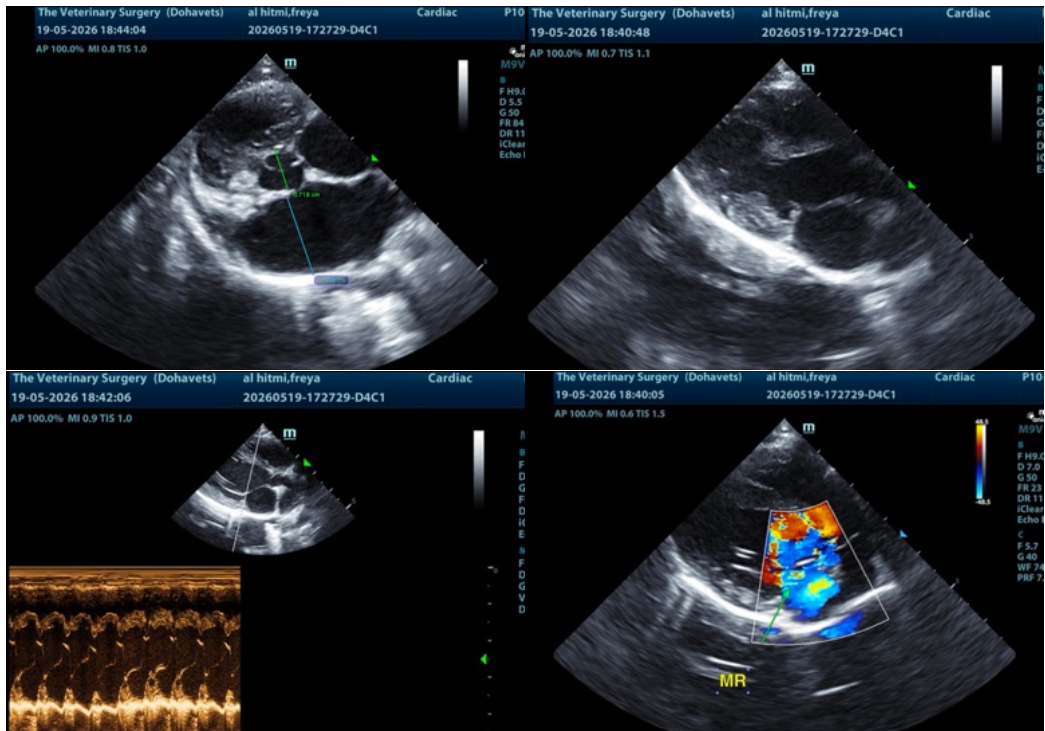
Female

**AGE**

2 years

**WEIGHT**

2.6 kg



**INTERPRETED BY**

Eric Lindquist, DMV  
DABVP, Cert. IVUSS

**IMAGING PERFORMED BY**

Dr. Samad Khan

**HOSPITAL NAME**

The Veterinary Surgery  
Street 805

**REFERRING VET**

Dr. Khan

**INVOICE**

77724

**DATE**

5/19/26

The information and recommendations provided are based on the images presented by the referring veterinarian/sonographer. No evaluation can be communicated regarding pathology that was not visible in the image/video clips provided.

Thank you for this referral. If the clinical or image interpretation does not parallel your findings or if I can be of any further assistance please contact me.

Eric Lindquist, DMV, DABVP (CFM), Cert. IVUSS, CEO of SonoPath.com

[info@SonoPath.com](mailto:info@SonoPath.com)