



PATIENT

Finn Pippin

SPECIES

Canine

BREED

King Charles Cavalier
Spaniel

SEX

Neutered male

AGE

7 years

WEIGHT

22.8 lbs

INTERPRETED BY

Eric Lindquist, DMV
DABVP, Cert. IVUSS

IMAGING PERFORMED BY

Dr. Ashley Whitesell

HOSPITAL NAME

Dickson AC

REFERRING VET

Dr. Hovis

INVOICE

77720

DATE

5/19/26

PRESENTING CLINICAL SIGNS

History: Grade V/VI heart murmur, asymptomatic
PE: Heart murmur V/VI, asymptomatic Chem: ALKP 326 IU/L (high), SDMA 4.1UG/dL (low), Cholesterol 333mg/dL (high)

ULTRASONOGRAPHIC EXAMINATION OF THE HEART

The echocardiogram in this patient demonstrated normal **left atrial** size based on 3 separate methods of LA evaluation. The cranial and caudal **mitral** valve leaflets presented normal linear structure, extension in systole, and union in diastole with normal kinesis. The **left ventricle** presented thicknesses with linear contour and was not dilated nor restricted. The **myocardium** presented normal echogenicity without subjective evidence of significant fibrotic or ischemic disease. **Contractility** of the ventricular walls was adequate and in normal range for this patient evidenced by the fractional shortening measurement and subjective evaluation of the different regions of the myocardium. The **left ventricular outflow** tract demonstrated normal laminar flow and subjective structural integrity. The **right atrium** and auricle revealed normal size, structure and content. No evidence of masses was noted. **Tricuspid** valvular assessment demonstrated adequate linear morphology and kinesis. The **right ventricle** was of normal size (1/3 diameter of LV), chordae structure, myocardial echogenicity and thickness. **Pulmonary outflow** tract assessment revealed normal valve structure, laminar flow, and diameter (approx. 1:1 pa/ao ratio). No visible **pericardial** or free pleura fluid was noted. The cranial **mediastinum and pericardial and extra-cardiac regions** were free of masses in the visible window. The hepatic veins were not dilated.

| CANINE CARDIAC PARAMETERS | MR VMAX (m/s) | TR VMAX (m/s) | LA/AO | LA/AO (Heart Base) | FS (%) | EF (%) | EPSS (cm) |
|---------------------------|---------------|---------------|--------------|--------------------|---------------------------------|--|--|
| NORMAL PARAMETER | 4.5-5.5 | <2.7 | 1.3 | <1.6 | 28-40 | 40-100 | <0.6 |
| PATIENT | None | - | 1.1 | 1.4 | 40 | - | 0.1 |
| CANINE CARDIAC PARAMETERS | HR (BPM) | AV VMAX (m/s) | PV MAX (m/s) | BODY WEIGHT | LA 2D short axis Base view (cm) | LVIDd Avg; 2D and m-mode short axis (cm) | LVIDs Avg; 2D and m-mode short axis (cm) |
| NORMAL PARAMETER | 50-100 | 0.7-1.7 | 0.7-1.6 | BELOW | BELOW | BELOW | BELOW |
| PATIENT | - | 1.2 | 0.6 | 22.8 lbs | 3.5 | 3.0 | |

ULTRASONOGRAPHIC FINDINGS

Stage B1 valvular disease.



PATIENT

Finn Pippin

SPECIES

Canine

BREED

King Charles Cavalier
Spaniel

SEX

Neutered male

AGE

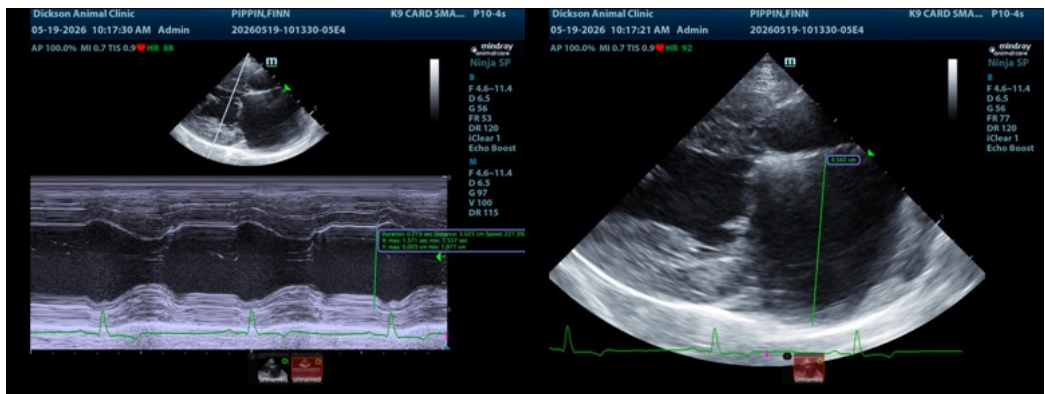
7 years

WEIGHT

22.8 lbs

INTERPRETATION OF THE FINDINGS & FURTHER RECOMMENDATIONS

The heart is stable without clinical disease. No overt contraindication for anesthesia of brief to moderate duration. I suggest Torbutrol premed, Propofol induction, Isoflo maintenance or similar protocol if anesthesia is desired. Blood pressure recommended if not already performed and target white coat negative systolic pressure of < 160 mmHg. If higher than this ACE-inhibitor is suggested to reach this level. Recheck echocardiogram is recommended in 6 months, earlier if murmur grade increases or clinical signs initiate.



INTERPRETED BY

Eric Lindquist, DMV
DABVP, Cert. IVUSS

IMAGING PERFORMED BY

Dr. Ashley Whitesell

HOSPITAL NAME

Dickson AC

REFERRING VET

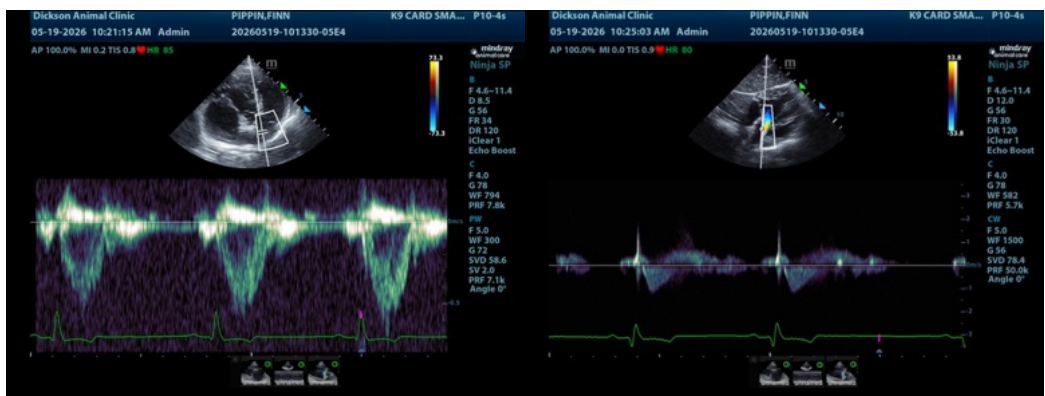
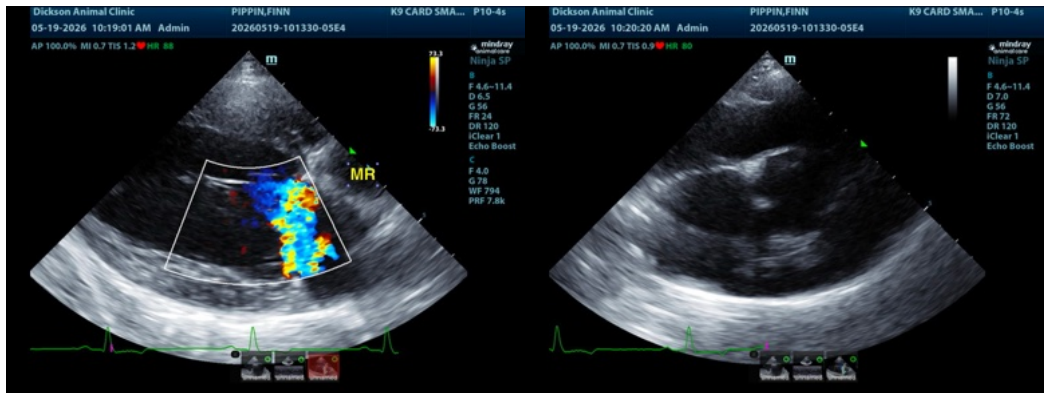
Dr. Hovis

INVOICE

77720

DATE

5/19/26



The information and recommendations provided are based on the images presented by the



PATIENT

Finn Pippin

SPECIES

Canine

BREED

King Charles Cavalier
Spaniel

SEX

Neutered male

AGE

7 years

WEIGHT

22.8 lbs

INTERPRETED BY

Eric Lindquist, DMV
DABVP, Cert. IVUSS

IMAGING PERFORMED BY

Dr. Ashley Whitesell

HOSPITAL NAME

Dickson AC

REFERRING VET

Dr. Hovis

INVOICE

77720

DATE

5/19/26

referring veterinarian/sonographer. No evaluation can be communicated regarding pathology that was not visible in the image/video clips provided.

Thank you for this referral. If the clinical or image interpretation does not parallel your findings or if I can be of any further assistance please contact me.

Eric Lindquist, DMV, DABVP (CFM), Cert. IVUSS, CEO of SonoPath.com

info@SonoPath.com