



PATIENT

Bailey Clarke

SPECIES

Canine

BREED

Morkie

SEX

Neutered male

AGE

11 years

WEIGHT

12.8 lbs

INTERPRETED BY

Eric Lindquist, DMV
DABVP, Cert. IVUSS

IMAGING PERFORMED BY

Dr. Ceclia Fisher

HOSPITAL NAME

Cape Coral Pet Vet

REFERRING VET

Dr. Vickers

INVOICE

77706

DATE

5/19/26

PRESENTING CLINICAL SIGNS

History: Diarrhea with hematochezia;
Prev HX- pancreatitis--still not back to 100% per owner
Meds on Metronidazole and carprofen.

ULTRASONOGRAPHIC EXAMINATION OF THE ABDOMEN

Urinary System

The **urinary bladder**, trigone, and pelvic urethra presented normal thicknesses and normal tone. The ureters were not visible which is normal. No uroliths or sediment were visualized and anechoic urine was present. No evidence of inflammatory or neoplastic changes was noted. Ureteral papillae were normal.

The **kidneys** revealed normal size and structure, corticomedullary definition and ratio for this age. The cortices presented largely uniform texture with normal echogenic relationship to liver and spleen. Medullary structure differed distinctly from the cortex and no evidence of pelvic dilation was present. The capsules were acceptably uniform without significant irregularities. The left kidney measured 4.0 cm. The right kidney measured

Adrenal Glands

Both **adrenal glands** were visualized and recognized as having normal shape, size, position and echogenicity for this breed. The phrenic vasculature, glandular echogenicity and detail were unremarkable. Capsule, cortex, and medullary definition were normal for this age patient. The left adrenal gland measured 0.5 cm. The right adrenal gland measured 0.5 cm.

Spleen

The **spleen** presented a smooth homogeneous parenchyma hyperechoic to liver and renal cortical parenchyma. The capsule was smooth without noticeable expansion or deviation from within the spleen or adjacent pathology. The splenic vasculature demonstrated normal volume without signs of congestion or thrombosis. No sonographic evidence of acute or chronic inflammatory, neoplastic, or infarctual changes was noted.

Liver

The **liver** was uniformly swollen with minor, excessive gallbladder debris and over distension with dependent and suspended bile without evidence of overt mucocele formation. However, excessive sludge was present. The liver presented coarse architecture with mildly increased portal markings and subtle, mixed echogenic changes. This is consistent with vacuolar hepatopathy and some level of remodeling and history of inflammatory component. There was no overt suspicion of neoplasia.



PATIENT

Bailey Clarke

SPECIES

Canine

BREED

Morkie

SEX

Neutered male

AGE

11 years

WEIGHT

12.8 lbs

INTERPRETED BY

Eric Lindquist, DMV
DABVP, Cert. IVUSS

IMAGING PERFORMED BY

Dr. Ceclia Fisher

HOSPITAL NAME

Cape Coral Pet Vet

REFERRING VET

Dr. Vickers

INVOICE

77706

DATE

5/19/26

Gastrointestinal

Examination of the **gastrointestinal tract** revealed transit of chyme into the small intestine. This is most consistent with a post prandial presentation. There was mucosal speckling in the small intestine. The clinical relevance is debatable and may be related to a latent inflammatory bowel.

Pancreas

The base and limbs of the **pancreas** were observed to be largely isoechoic to surrounding omental fat. Pancreatic duct and capsular contour were acceptably normal and parenchyma respected normal curvilinear patterns. No overt evidence of active inflammatory or neoplastic disease was noted.

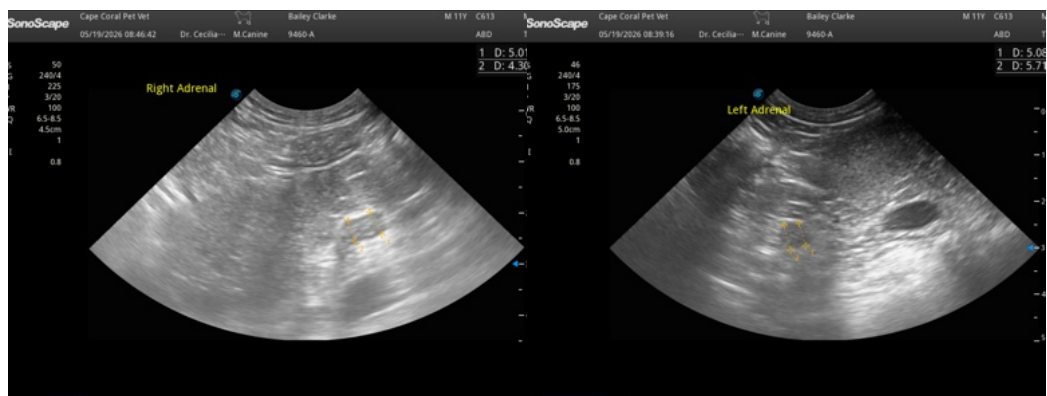
ULTRASONOGRAPHIC FINDINGS

Possible lymphangectasia presentation, inflammatory bowel. Changes are minor.

Benign abdomen.

INTERPRETATION OF THE FINDINGS & FURTHER RECOMMENDATIONS

Differentials for diarrhea include occult parasitism. Dietary indiscretion, dietary intolerance, antibiotic responsive colitis, intestinal dysbiosis and occult Addison's should all be considered as causes of diarrhea in this patient. A hydrolyzed diet trial may be in this patient's best interest +/- probiotics. 24-hour NPO and reintroduction of bland diet indicated. I recommend a baseline cortisol or ACTH stimulation test, a fresh fecal smear and fecal floatation analysis if not already performed





PATIENT

Bailey Clarke

SPECIES

Canine

BREED

Morkie

SEX

Neutered male

AGE

11 years

WEIGHT

12.8 lbs

INTERPRETED BY

Eric Lindquist, DMV
DABVP, Cert. IVUSS

IMAGING PERFORMED BY

Dr. Ceclia Fisher

HOSPITAL NAME

Cape Coral Pet Vet

REFERRING VET

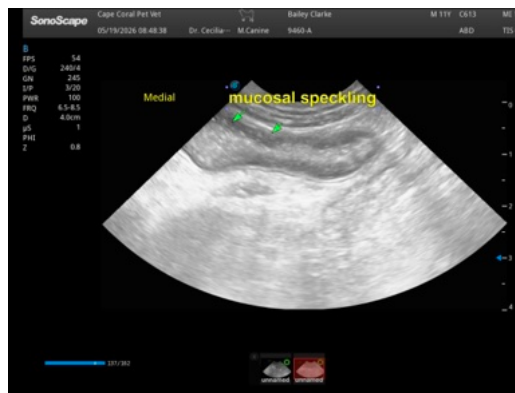
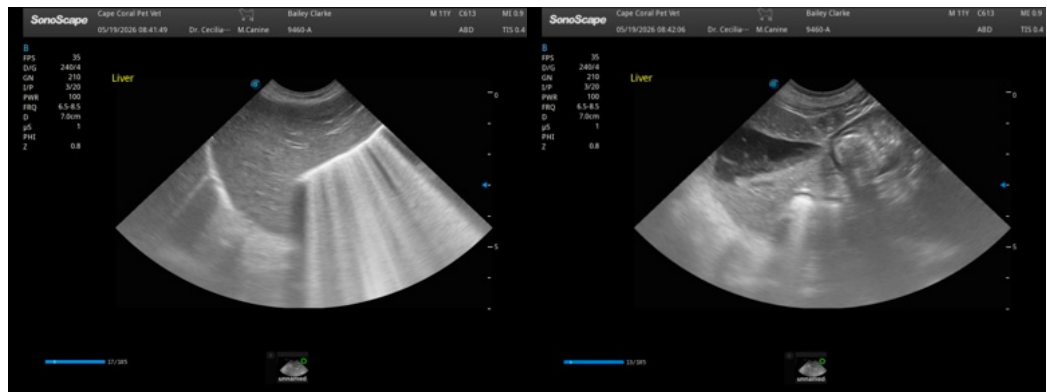
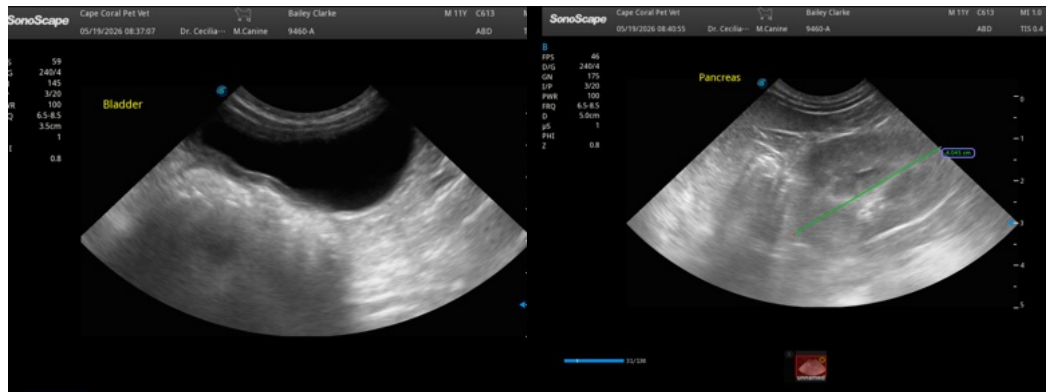
Dr. Vickers

INVOICE

77706

DATE

5/19/26



The information and recommendations provided are based on the images presented by the referring veterinarian/sonographer. No evaluation can be communicated regarding pathology that was not visible in the image/video clips provided.

Thank you for this referral. If the clinical or image interpretation does not parallel your findings or if I can be of any further assistance please contact me.

Eric Lindquist, DMV, DABVP (CFM), Cert. IVUSS, CEO of SonoPath.com

info@SonoPath.com