



**PATIENT PRESENTING CLINICAL SIGNS**

Stella Rupley History: Mass cranial to heart and abnormal result on IDEXX feline Pro BNP. This is the Dr.'s pet.

**SPECIES ULTRASONOGRAPHIC EXAMINATION OF THE HEART**

Feline

BREED

Domestic Shorthair

SEX

Spayed Female

AGE

16 years

WEIGHT

14.1 lbs

INTERPRETED BY

Eric Lindquist, DMV  
DABVP, Cert. IVUSS

IMAGING PERFORMED BY

Holly Burleson LVT

HOSPITAL NAME

All Pets Medical Center

REFERRING VET

Dr. Rupley

The echocardiogram in this patient demonstrated normal **left atrial** size based on 3 separate LA measurements. The cranial and caudal **mitral** valve leaflets presented normal linear structure and kinetics. The **left ventricle** presented normal thicknesses with linear contour and was not dilated nor restricted. The **myocardium** presented normal echogenicity without subjective evidence of significant fibrotic or ischemic disease. **Contractility** of the ventricular walls was adequate and in normal range for this patient evidenced by the fractional shortening measurement and subjective evaluation of the different regions and angles of the myocardium. The **left ventricular outflow** tract demonstrated normal laminar flow and subjective structural integrity. The **right atrium** and auricle revealed normal size, structure and content. No evidence of masses was noted or chamber overload. Minor **tricuspid** insufficiency was noted at 1.5 m/sec. The **right ventricle** was of normal size (1/3 diameter of LV), chordae structure, myocardial echogenicity and thickness. **Pulmonic** tract assessment revealed normal valve structure, laminar flow, and diameter (approx. 1:1 pa/ao ratio). No visible **pericardial** or free pleura fluid was noted or extra cardiac pathology in the visible planes. The cranial **mediastinum and pericardial regions** were free of masses in the visible window. A large amount of thoracic fat was noted in this patient around the heart base. There was no evidence of masses.

FELINE CARDIAC PARAMETERS	BODY WEIGHT	HR (BPM)	IVSd (cm)	LVIDd (cm)	LVWd (cm)	FS (%)	EF (%)
NORMAL PARAMETER	-----	150-240	0.3-0.6	1.0-2.1	0.25-0.6	35-67	80-100
PATIENT	14.1 lbs	NM					
FELINE CARDIAC PARAMETERS	LA/AO (Boon)	LA/AO HEART BASE (Sisson)	LA 2D 4-chamber long axis AS to FW (Sisson) (cm)	LVOT VEL. (m/s)	RVOT VEL. (m/s)	IVRT (m)	
NORMAL PARAMETER	<1.5	0.88-1.79	0.7-1.7	<1.6	<1.3	40-60	
PATIENT		1.4	1.3 max	1.05	0.82	NM	
Adapted from June Boon, Veterinary Echocardiography, 1998 Sisson D et al. JVIM 1991; 5: 232, Jacobs et al. Am J Vet Res 1985; 46:1705							

**INVOICE ULTRASONOGRAPHIC FINDINGS**

30542 Normal echocardiogram, fat density around the heart.

**DATE INTERPRETATION OF THE FINDINGS & FURTHER RECOMMENDATIONS**

5/18/22 No evidence of masses were noted.



## PATIENT

Stella Rupley

## SPECIES

Feline

## BREED

Domestic Shorthair

## SEX

Spayed Female

## AGE

16 years

## WEIGHT

14.1 lbs

## INTERPRETED BY

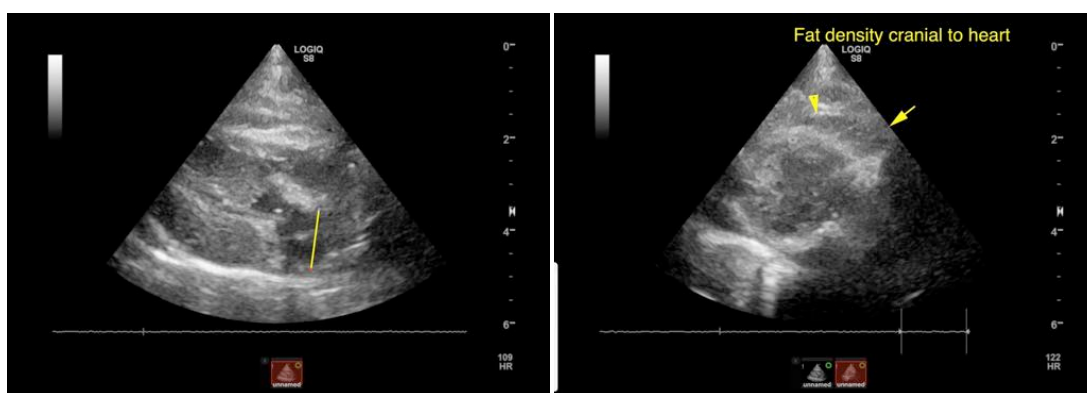
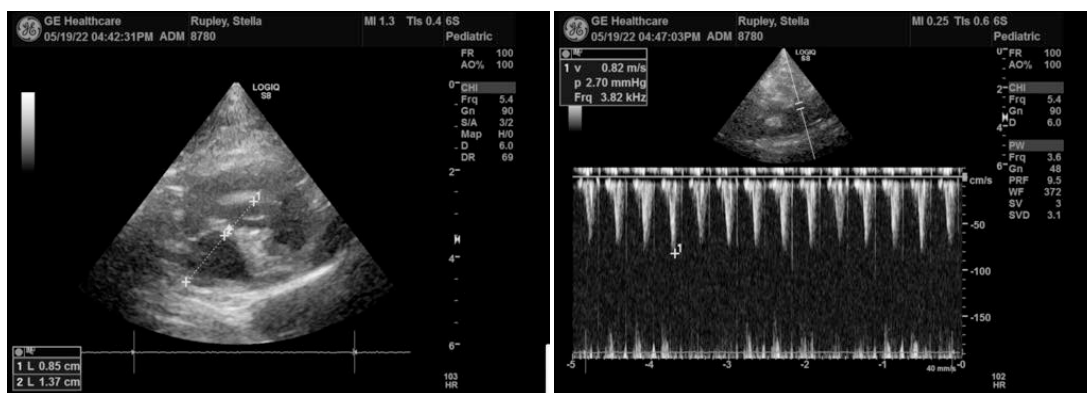
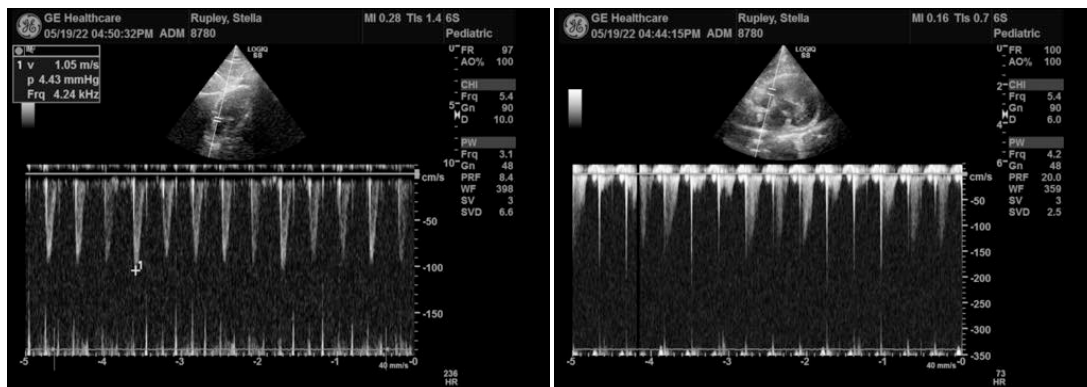
Eric Lindquist, DMV  
DABVP, Cert. IVUSS

## IMAGING PERFORMED BY

Holly Burleson LVT

## HOSPITAL NAME

All Pets Medical Center



## REFERRING VET

Dr. Rupley

## INVOICE

30542

## DATE

5/18/22

The information and recommendations provided are based on the images presented by the referring veterinarian/sonographer. No evaluation can be communicated regarding pathology that was not visible in the image/video clips provided.

Thank you for this referral. If the clinical or image interpretation does not parallel your findings or if I can be of any further assistance please contact me.

Eric Lindquist, DMV, DABVP, Cert. IVUSS, CEO of SonoPath.com  
info@SonoPath.com