



PATIENT PRESENTING CLINICAL SIGNS

Buffy Sluby Pre-anesthetic radiographs showed L sided cardiomegaly, no HM, pet fractious. Coughing, collapsing trachea. Hepatomegaly on radiographs, tense abdomen on exam. Mild elevation in ALT. O reports pet doesnt want to go for walks last few days.

SPECIES Abnormal PE/Chem/CBC/UA Results: Pt. fractious, tense abdomen, growling, mild tracheal cough, no evidence of heart murmur - however difficult to auscultate

Canine

BREED ULTRASONOGRAPHIC EXAMINATION OF THE HEART

Lhasa APso The echocardiogram presented a prominent **right heart** with mild **right ventricular** hypertrophy, with trivial **tricuspid** regurgitation, and normal **right atrial** size. No evidence of neoplasia was noted in the right auricle, or elsewhere in the heart. The **pulmonary artery** was uniformly prominent with mildly depressed pulmonic velocity measured on PW Doppler. No overt heartworms were noted in the main or visible deep pulmonary arteries. Yet, theoretically heartworms could be present in the deep pulmonary vasculature out of visible sonographic range. More likely, however, this prominent right heart is due to excessive intra-thoracic pressures caused by chronic respiratory disease or potentially excessive intra-thoracic fat (Pickwickian syndrome). The **left heart** demonstrated a linear **ventricular septum**.

SEX Contractility was functionally adequate demonstrated by the FS% measurement. The **mitral valve** was not significantly insufficient and no significant **left atrial** dilation was noted. The **left ventricular outflow** demonstrated normal flow patterns and velocities through the aortic valve. No evidence of tumor, pericardial or pleural effusion was noted. The visible **extra-cardiac** tissues were uniformly linear without evidence of masses, infiltrative or inflammatory mediastinal tissue. No evident arrhythmic activity was noted during the exam.

Spayed Female

AGE 8 years

WEIGHT 15 lbs

INTERPRETED BY

Eric Lindquist, DMV
DABVP, Cert. IVUSS

IMAGING PERFORMED BY

Dr. Striano-Kaplan

HOSPITAL NAME

Ramsey VH

REFERRING VET

Dr. Striano Kaplan

| CANINE | MR | TR | LA/AO | LA/AO | FS | EF | EPSS |
|---------------------------|----------------------|----------------------|---------------------|-------------------|---------------------------------|---------------------------------------|---------------------------------------|
| CARDIAC PARAMETERS | VMAX (m/s) | VMAX (m/s) | (Boon method) | (Heart Base; Swe) | (%) | (%) | (cm) |
| NORMAL PARAMETER | 4.5-5.5 | <2.7 | 1.3 | <1.3 | 28-40 | 40-100 | <0.6 |
| PATIENT | | | 1.15 | 1.3 | 45 | 80 | NM |
| CANINE | HR | AV | PV | BODY WEIGHT | LA | LVIDd | LVIDs |
| CARDIAC PARAMETERS | (BPM) | VMAX (m/s) | MAX (m/s) | | 2D short axis Base view (cm) | Avg; 2D and m-mode short axis (cm) | Avg; 2D and m-mode short axis (cm) |
| NORMAL PARAMETER | 50-100 | 0.7-1.7 | 0.7-1.6 | | | | |
| PATIENT | | | 0.5 | 15 lbs | 2.6 max | 2.36 | |

INVOICE

30517

DATE

5/18/22



PATIENT **ULTRASONOGRAPHIC EXAMINATION OF THE ABDOMEN**

Buffy Sluby

Urinary System

SPECIES

Canine

The **urinary bladder**, trigone, and pelvic urethra presented normal thicknesses and normal tone. The ureters were not visible which is normal. No uroliths or sediment were visualized and anechoic urine was present. No evidence of inflammatory or neoplastic changes was noted. Ureteral papillae were normal.

BREED

Lhasa APso

The **kidneys** revealed normal size and structure, corticomedullary definition and ratio for this age. The cortices presented largely uniform texture with normal echogenic relationship to liver and spleen. Medullary structure differed distinctly from the cortex and no evidence of pelvic dilation was present. The capsules were acceptably uniform without significant irregularities.

SEX

Spayed Female

Adrenal Glands

AGE

8 years

Both **adrenal glands** were visualized and recognized as having normal shape, size, position and echogenicity for this breed. The phrenic vasculature, glandular echogenicity and detail were unremarkable. Capsule, cortex, and medullary definition were normal for this age patient.

WEIGHT

15 lbs

Spleen

INTERPRETED BY

Eric Lindquist, DMV
DABVP, Cert. IVUSS

The **spleen** presented a smooth homogeneous parenchyma hyperechoic to liver and renal cortical parenchyma. The capsule was smooth without noticeable expansion or deviation from within the spleen or adjacent pathology. The splenic vasculature demonstrated normal volume without signs of congestion or thrombosis. No sonographic evidence of acute or chronic inflammatory, neoplastic, or infarctual changes was noted.

IMAGING PERFORMED BY

Dr. Striano-Kaplan

Liver

HOSPITAL NAME

Ramsey VH

The **liver** images submitted revealed subjectively normal liver size, contour, and structure. Parenchymal echogenicity was naturally coarse and hypoechoic to the spleen. Vascular and biliary tracts were of normal volume with no evidence of congestion. The gallbladder presented acceptably thin walls with primarily anechoic content. The cystic and common bile ducts were normal. No pathological hepatic lymphadenopathy was evident. No overt structural evidence of inflammatory, infiltrative or regenerative pathology was evident.

REFERRING VET

Dr. Striano Kaplan

Gastrointestinal

INVOICE

30517

Examination of the **gastrointestinal tract** revealed a stomach and intestine free of stasis, of normal wall thickness, acceptable curvilinear mural detail, and peristaltic activity. Small and large intestine demonstrated normal luminal chyme and stool consistency respectively. No obstructive or overt infiltrative disease was noted. No associated abnormal lymphatic activity was noted.

DATE

5/18/22



PATIENT

Pancreas

Buffy Sluby

The base and limbs of the **pancreas** were observed to be largely isoechoic to surrounding omental fat. Pancreatic duct and capsular contour were acceptably normal and parenchyma respected normal curvilinear patterns. No overt evidence of active inflammatory or neoplastic disease was noted.

SPECIES

Canine

ULTRASONOGRAPHIC FINDINGS

BREED

Mild cor pulmonale.

Lhasa APso

Minor tricuspid insufficiency.

SEX

INTERPRETATION OF THE FINDINGS & FURTHER RECOMMENDATIONS

Spayed Female

The clinical signs are not cardiogenic in this patient. Primary respiratory protocol is recommended.

AGE

8 years

WEIGHT

15 lbs

INTERPRETED BY

Eric Lindquist, DMV
DABVP, Cert. IVUSS

IMAGING PERFORMED BY

Dr. Striano-Kaplan

HOSPITAL NAME

Ramsey VH

REFERRING VET

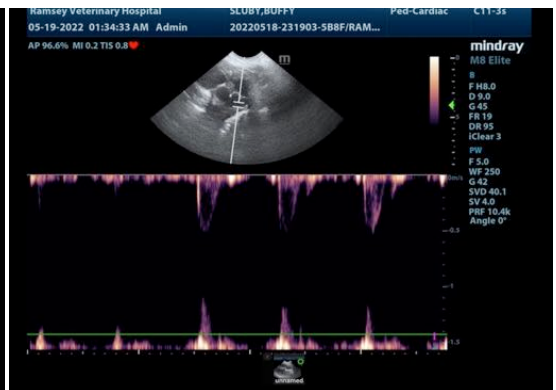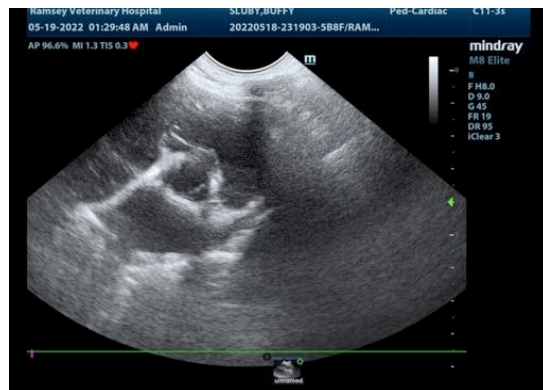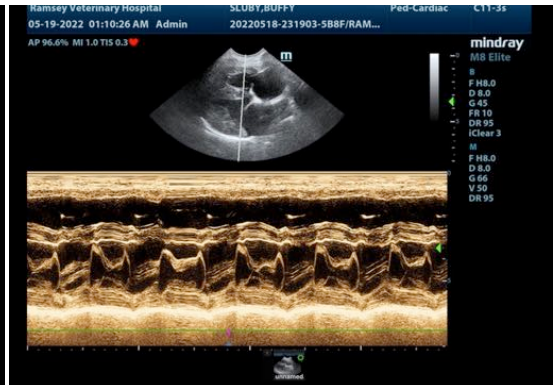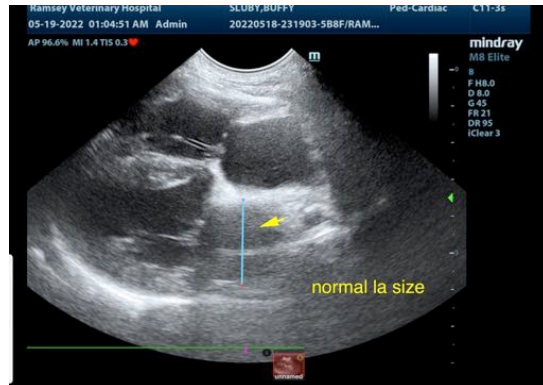Dr. Striano Kaplan

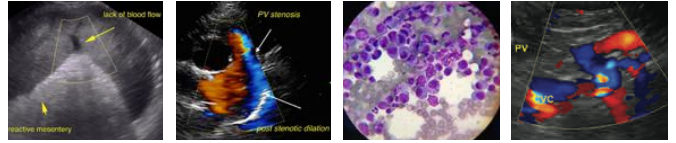
INVOICE

30517

DATE

5/18/22





PATIENT

Buffy Sluby

SPECIES

Canine

BREED

Lhasa APso

SEX

Spayed Female

AGE

8 years

WEIGHT

15 lbs

INTERPRETED BY

Eric Lindquist, DMV
DABVP, Cert. IVUSS

IMAGING PERFORMED BY

Dr. Striano-Kaplan

HOSPITAL NAME

Ramsey VH

REFERRING VET

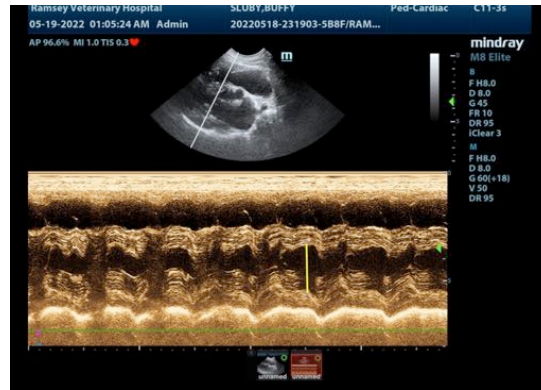
Dr. Striano Kaplan

INVOICE

30517

DATE

5/18/22



The information and recommendations provided are based on the images presented by the referring veterinarian/sonographer. No evaluation can be communicated regarding pathology that was not visible in the image/video clips provided.

Thank you for this referral. If the clinical or image interpretation does not parallel your findings or if I can be of any further assistance please contact me.

Eric Lindquist, DMV, DABVP, Cert. IVUSS, CEO of SonoPath.com
info@SonoPath.com