



## PATIENT

Winnie Abdel-Rahim

## SPECIES

Canine

## BREED

Mini Australian Shepherd

## SEX

Spayed Female

## AGE

7 Years

## WEIGHT

19.04 lbs

## INTERPRETED BY

Eric Lindquist, DMV,  
DABVP(CFM), Cert.  
IVUSS

## IMAGING PERFORMED BY

Holly LVT

## HOSPITAL NAME

All Pets Medical Center

## REFERRING VET

Agnes Rupley, DVM

## INVOICE

16347

## DATE

05/18/26

## PRESENTING CLINICAL SIGNS

Stable chronic grade II/VI left-sided systolic heart murmur ausculted. Significant renal failure is present and intravenous, or subcutaneous fluid therapy is indicated. Cardiac evaluation is being performed to assess the risk of potential cardiovascular complications associated with fluid administration.

## ULTRASONOGRAPHIC EXAMINATION OF THE HEART

CANINE CARDIAC PARAMETERS	MR VMAX (m/s)	TR VMAX (m/s)	LA/AO (M-Mode)	LA/AO (Heart Base; Swe)	FS (%)	EF (%)	EPSS (cm)
NORMAL PARAMETER	4.5-5.5	<2.7	1.3	Up to 1.6	28-40	40-100	<0.6
PATIENT	>4.0	--	1.2	1.4	50	--	0.1
CANINE CARDIAC PARAMETERS	HR (BPM)	AV VMAX (m/s)	PV MAX (m/s)	BODY WEIGHT (lbs)	LAD LA MAX 4 Chamber	LVIDd Avg; 2D and m-mode short axis (cm)	LVIDs Avg; 2D and m-mode short axis (cm)
NORMAL PARAMETER	50-100	0.7-1.7	0.7-1.6				
PATIENT	120	1.9	1.3	19.04	2.5	2.7	--

## Cardiac Presentation

The echocardiogram in this patient demonstrated normal **left atrial** size based on 3 different LA measurement methods. Chamber volumes and echogenicity were normal. The cranial and caudal **mitral** valve leaflets presented vegetative thickening consistent with endocardiosis. Doppler indicated measurable insufficiency. The **left ventricle** presented mild left ventricular septal free wall hypertrophy, with normal internal diameters. The **myocardium** presented normal echogenicity without subjective evidence of significant fibrotic or ischemic disease. **Contractility** of the ventricular walls was adequate and in normal range for this patient evidenced by the fractional shortening measurement and subjective evaluation of the different regions of the myocardium. The **left ventricular outflow** tract demonstrated normal laminar flow and subjective structural integrity. The **right atrium** and auricle revealed normal size, structure and content. No evidence of masses was noted or chamber overload. **Tricuspid** valvular assessment demonstrated adequate linear morphology. The **right ventricle** was of normal size (1/3 diameter of LV), chordae structure, myocardial echogenicity and thickness. **Pulmonic** tract assessment revealed normal valve structure, laminar flow, and diameter (approx.1:1 pa/ao ratio). No visible **pericardial** or free pleura fluid was noted. No echographically detectable evidence of infiltrative disease was visible. The cranial **mediastinum and pericardial regions** were free of masses in the visible window.

## ULTRASONOGRAPHIC FINDINGS

- Stage B1 valvular disease.



**PATIENT**

Winnie Abdel-Rahim

**SPECIES**

Canine

**BREED**

Mini Australian Shepherd

**SEX**

Spayed Female

**AGE**

7 Years

**WEIGHT**

19.04 lbs

**INTERPRETED BY**

Eric Lindquist, DMV,  
DABVP(CFM), Cert.  
IVUS

**IMAGING PERFORMED BY**

Holly LVT

**HOSPITAL NAME**

All Pets Medical Center

**REFERRING VET**

Agnes Rupley, DVM

**INVOICE**

16347

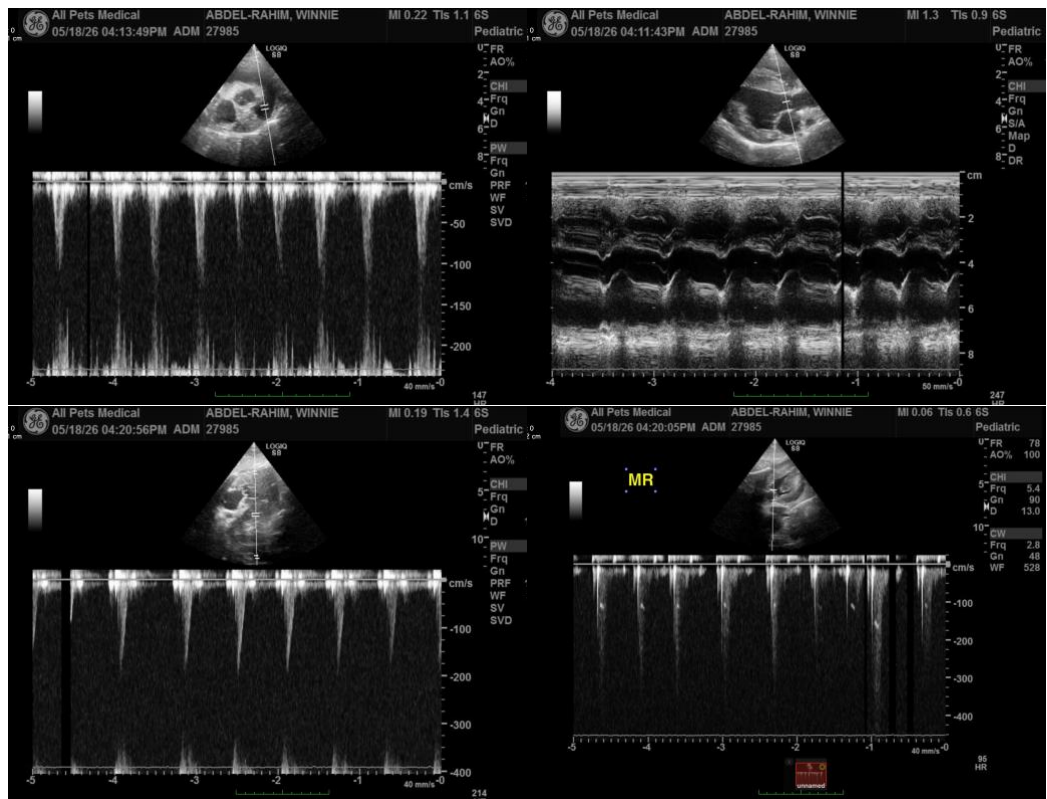
**DATE**

05/18/26

**INTERPRETATION OF THE FINDINGS & FURTHER RECOMMENDATIONS**

The heart is stable without clinical disease. No overt contraindication for anesthesia of brief to moderate duration. I suggest Torbutrol premed, Propofol induction, Isoflor maintenance or similar protocol if anesthesia is desired. Blood pressure, EKG and chest radiographs are recommended if not already performed. Target white coat negative systolic pressure of < 160 mmHg. If higher than this ACE-inhibitor is suggested to reach this level. Recheck echocardiogram is recommended in 6-12 months, earlier if murmur grade increases or clinical signs initiate.

No therapy is recommended at this time. If the patient is hypertensive, this would explain the left ventricular hypertrophy. Serial blood pressure is indicated, yet no specific cardiac medications are recommended at this time.





## PATIENT

Winnie Abdel-Rahim

## SPECIES

Canine

## BREED

Mini Australian Shepherd

## SEX

Spayed Female

## AGE

7 Years

## WEIGHT

19.04 lbs

## INTERPRETED BY

Eric Lindquist, DMV,  
DABVP(CFM), Cert.  
IVUSS

## IMAGING PERFORMED BY

Holly LVT

## HOSPITAL NAME

All Pets Medical  
Center

## REFERRING VET

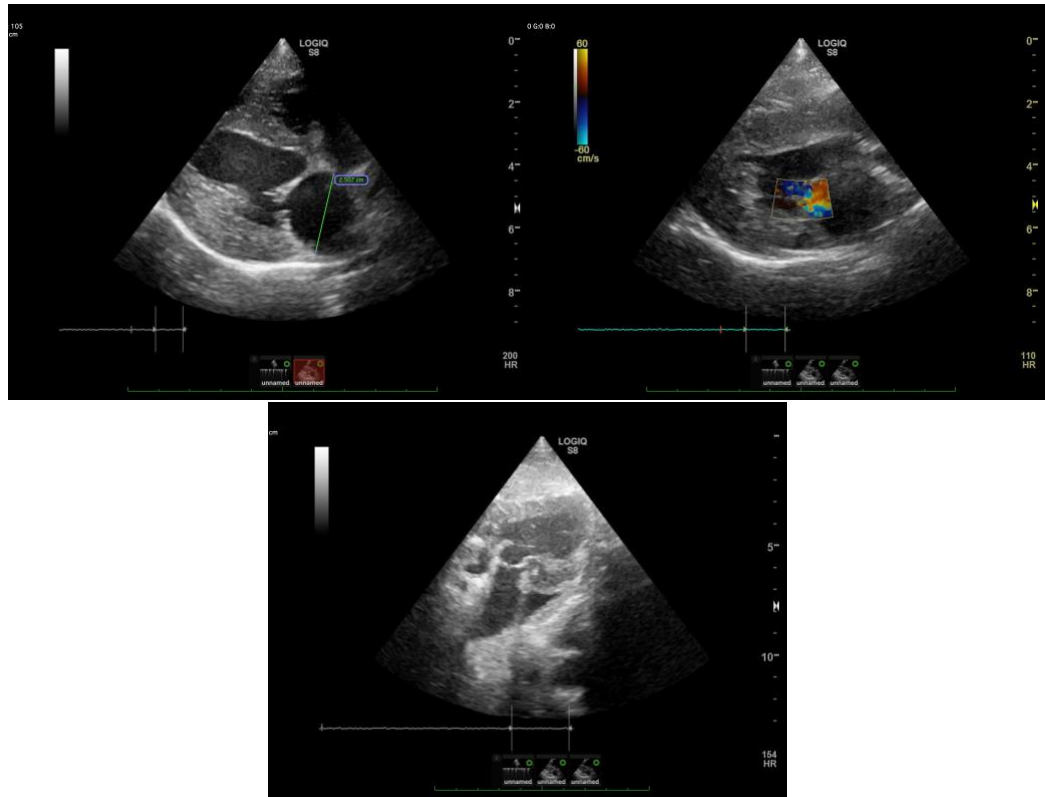
Agnes Rupley, DVM

## INVOICE

16347

## DATE

05/18/26



The information and recommendations provided are based on the images presented by the referring veterinarian/sonographer. No evaluation can be communicated regarding pathology that was not visible in the image/video clips provided.

Thank you for this referral. If the clinical or image interpretation does not parallel your findings or if I can be of any further assistance, please contact me.

**Eric Lindquist, DMV, DABVP(CFM), Cert. IVUSS,**

CEO, Owner, Founder -- SonoPath.com

[info@SonoPath.com](mailto:info@SonoPath.com)