



PATIENT

Tata Sun

SPECIES

Feline

BREED

Ragdoll

SEX

Spayed Female

AGE

11

WEIGHT

10

INTERPRETED BY

Eric Lindquist, DMV,
DABVP (CFM), Cert.
IVUSS

IMAGING PERFORMED BY

Dr. Shen Li

HOSPITAL NAME

Dr. Shen Li Veterinary
Service

REFERRING VET

Dr. Shen Li

INVOICE

75218

DATE

5/18/26

PRESENTING CLINICAL SIGNS

Recent heart murmur detection. Mild alt alp elevation. Hx of asthma. Vomit 1-2 times a month. Abnormal PE/Chem/CBC/UA Results: Normal PE dental disease. Mild elevation of ALT and ALP

ULTRASONOGRAPHIC EXAMINATION OF THE ABDOMEN

Urinary System

The **urinary bladder**, trigone, and pelvic urethra presented normal thicknesses and normal tone. The ureters were not visible which is normal. No uroliths or sediment were visualized and anechoic urine was present. No evidence of inflammatory or neoplastic changes were noted. Ureteral papillae were normal. The pelvic urethra was imaged 1.0 cm beyond the cystourethral junction.

The **kidneys** revealed largely normal size and structure, corticomedullary definition and ratio (cortex 1/3 of medulla) were essentially maintained with some age-related loss of curvilinear patterns regarding the capsule and C/M junction. The cortices presented largely uniform texture with some increased echogenicity expected for his age patient. Medullary structure differed distinctly from that of the cortex and no evidence of pelvic dilation was present. Slight areas of mineralization noted. Left kidney measured 3.6 cm. Right kidney measured 3.4 cm. Blood flow to the kidneys was slightly subnormal, expected for this age patient.

Adrenal Glands

Both **adrenal glands** were visualized and recognized as having normal shape, size, position and echogenicity for this breed. The phrenic vasculature, glandular echogenicity and detail were unremarkable. Capsule, cortex, and medullary definition were normal for this age patient. The adrenals measured 0.40 cm each.

Spleen

The **spleen** presented a smooth homogeneous parenchyma hyperechoic to liver and renal cortical parenchyma. The capsule was smooth without noticeable expansion or deviation from within the spleen or adjacent pathology. The splenic vasculature demonstrated normal volume without signs of congestion or thrombosis. No sonographic evidence of acute or chronic inflammatory, neoplastic, or infarctual changes were noted.

Liver

The **liver** images from right and left intercostal as well as subcostal views revealed subjectively normal liver size, contour, and structure. Some age-related parenchymal remodeling was noted but likely not clinically significant at this time. Vascular and biliary tracts were of normal volume and no evidence of congestion was noted. The gallbladder presented some dependent debris with essentially normal contour. The cystic and common bile ducts were normal. No overt evidence of active inflammatory, infiltrative or regenerative pathology was noted but should be paired with current or past LE elevations regarding any clinical significance to this presentation. The hepatic lymph nodes were unremarkable.

Gastrointestinal

Examination of the **gastrointestinal tract** revealed a stomach and intestine free of stasis, of normal wall thickness, acceptable curvilinear mural detail, and peristaltic activity. Small and large intestine



PATIENT

Tata Sun

demonstrated normal luminal chyme and stool consistency respectively. No obstructive or overt infiltrative disease was noted.

Pancreas

SPECIES

Feline

The base and limbs of the **pancreas** were observed to be largely isoechoic to surrounding omental fat. Pancreatic duct and capsular contour were acceptably normal and parenchyma respected normal curvilinear patterns. No overt evidence of active inflammatory or neoplastic disease was noted.

BREED

Ragdoll

Free Abdomen

No overt lymphadenopathy or peritoneal effusion was present.

SEX

Spayed Female

Mesenteric **lymph nodes** presented normal length to width ratio with slight, swollen contour. There was no loss of parenchymal detail. This is most consistent with reactive lymphadenitis or lymphatic hyperplasia. Largest lymph node measured 1.1 cm x 0.50 cm.

AGE

11

ULTRASONOGRAPHIC FINDINGS

- Reactive mesenteric lymph nodes.
- Structurally unremarkable liver with minor remodeling.
- Age related renal changes.

WEIGHT

10

INTERPRETATION OF THE FINDINGS & FURTHER RECOMMENDATIONS

INTERPRETED BY

Eric Lindquist, DMV,
DABVP (CFM), Cert.
IVUSS

Structurally insignificant inflammatory bowel and reactive lymphadenitis likely in this patient. Potential diet change to hydrolyzed diet and parasite management indicated. Potential Prednisolone trial may be necessary. If the mesenteric lymph node enlarges to a size that is easily sampleable, then cytology and culture would be appropriate.

IMAGING PERFORMED BY

Dr. Shen Li

HOSPITAL NAME

Dr. Shen Li Veterinary
Service

REFERRING VET

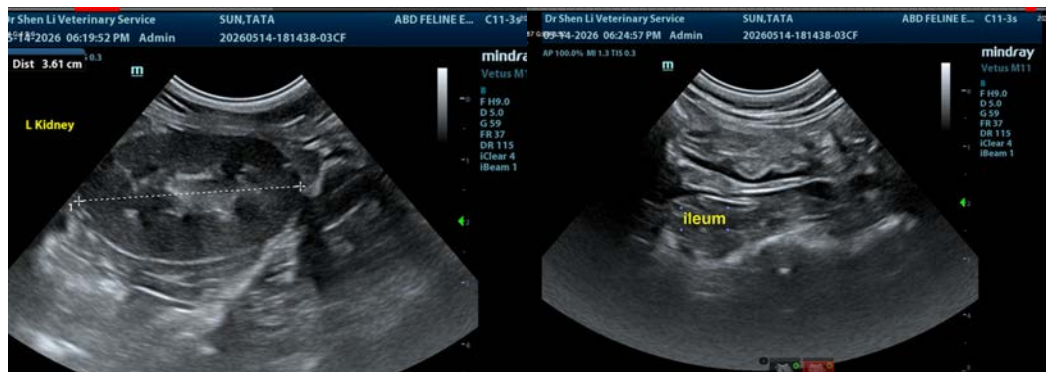
Dr. Shen Li

INVOICE

75218

DATE

5/18/26





PATIENT

Tata Sun

SPECIES

Feline

BREED

Ragdoll

SEX

Spayed Female

AGE

11

WEIGHT

10

INTERPRETED BY

Eric Lindquist, DMV,
DABVP (CFM), Cert.
IVUSS

IMAGING PERFORMED BY

Dr. Shen Li

HOSPITAL NAME

Dr. Shen Li Veterinary
Service

REFERRING VET

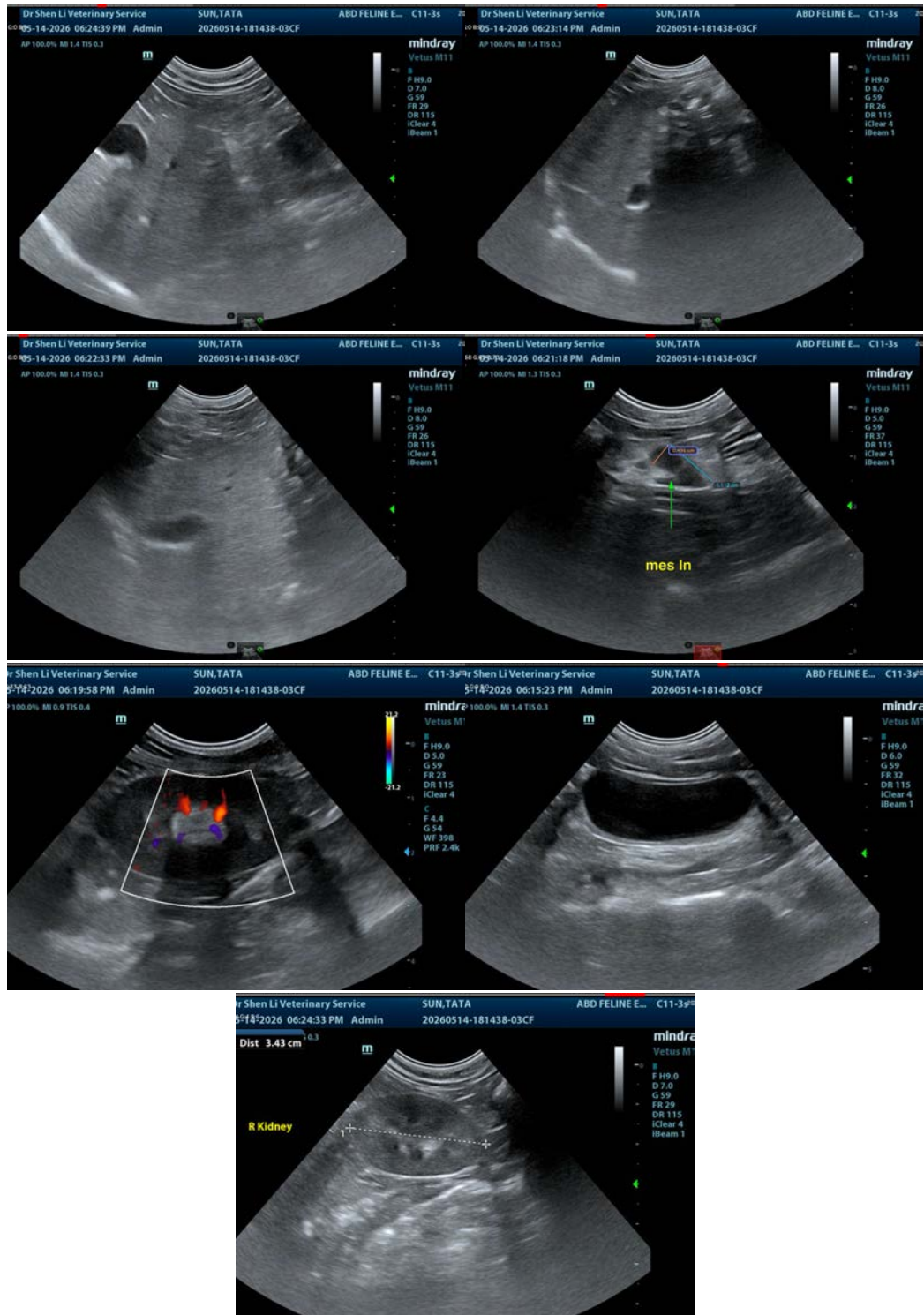
Dr. Shen Li

INVOICE

75218

DATE

5/18/26





PATIENT

Tata Sun

The information and recommendations provided are based on the images presented by the referring veterinarian/sonographer. No evaluation can be communicated regarding pathology that was not visible in the image/video clips provided.

SPECIES

Feline

Thank you for this referral. If the clinical or image interpretation does not parallel your findings or if I can be of any further assistance please contact me.

BREED

Ragdoll

Eric Lindquist, DMV, DABVP(CFM), Cert. IVUSS,
CEO, Owner, Founder -- SonoPath.com

info@SonoPath.com

SEX

Spayed Female

AGE

11

WEIGHT

10

INTERPRETED BY

Eric Lindquist, DMV,
DABVP (CFM), Cert.
IVUSS

**IMAGING
PERFORMED BY**

Dr. Shen Li

HOSPITAL NAME

Dr. Shen Li Veterinary
Service

REFERRING VET

Dr. Shen Li

INVOICE

75218

DATE

5/18/26