



PATIENT

Maya Mopsick

SPECIES

Canine

BREED

Blue Heeler/Australian
Shepherd Mix

SEX

Spayed Female

AGE

7 Years 3 Months

WEIGHT

59.8

INTERPRETED BY

Eric Lindquist, DMV,
DABVP(CFM), Cert.
IVUSS

IMAGING PERFORMED BY

Dr. Katie Margulies

HOSPITAL NAME

Fairland Animal
Hospital

REFERRING VET

Dr. Katie Margulies

INVOICE

16334

DATE

05/18/26

PRESENTING CLINICAL SIGNS

P has history of increase in thirst and hunger. Waking up in the middle of the night to eat. BCS has increased to 7/9 since these symptoms started a year ago. P has increased amount of panting and has overnight restlessness. No response to melatonin, gabapentin or clonidine. Only change on systemic labwork in 2/2026 was mild elevation in ALP. LDDS negative for Cushing's in 2/2026.

ULTRASONOGRAPHIC EXAMINATION OF THE ABDOMEN

Urinary System

The **urinary bladder**, trigone, and pelvic urethra to a depth of 2.0 cm presented normal thicknesses and normal tone. The ureters were not visible which is normal. No uroliths or sediment were visualized, and anechoic urine was present. No evidence of inflammatory or neoplastic changes were noted. Ureteral papillae were normal.

The **kidneys** revealed normal size and structure, corticomedullary definition and ratio for this age. The cortices presented largely uniform texture with normal echogenic relationship to liver and spleen. Medullary structure differed distinctly from the cortex and no evidence of pelvic dilation was present. The capsules were acceptably uniform without significant irregularities. The left kidney measured 6.7 cm in length. The right kidney measured 6.7 cm in length.

Adrenal Glands

The **left adrenal gland** was visualized and recognized as having normal shape, size, position and echogenicity for this breed. The phrenic vasculature, glandular echogenicity and detail were unremarkable. Capsule, cortex, and medullary definition were normal for this age patient. The left adrenal gland measured 0.5 cm width.

The **right adrenal gland** measured was not visualized owing to sound beam attenuation.

Spleen

The **spleen** presented a smooth homogeneous parenchyma hyperechoic to liver and renal cortical parenchyma. The capsule was smooth without noticeable expansion or deviation from within the spleen or adjacent pathology. The splenic vasculature demonstrated normal volume without signs of congestion or thrombosis. No sonographic evidence of acute or chronic inflammatory, neoplastic, or infarctual changes were noted.

Liver

The **liver** images from right and left intercostal as well as subcostal views revealed subjectively normal liver size, contour, and structure. Some minor age-related parenchymal remodeling was noted but likely not clinically significant at this time. Vascular and biliary tracts were of normal volume and no evidence of congestion was noted. The gallbladder presented some dependent debris with essentially normal contour. The cystic and common bile ducts were normal. No overt evidence of active inflammatory, infiltrative or regenerative pathology was noted but should be paired with current or past LE elevations regarding any clinical significance to this presentation. The hepatic lymph nodes were unremarkable.

Gastrointestinal



PATIENT

Maya Mopsick

SPECIES

Canine

BREED

Blue Heeler/Australian
Shpherd Mix

SEX

Spayed Female

AGE

7 Years 3 Months

WEIGHT

59.8

INTERPRETED BY

Eric Lindquist, DMV,
DABVP(CFM), Cert.
IVUSS

IMAGING PERFORMED BY

Dr. Katie Margulies

HOSPITAL NAME

Fairland Animal
Hospital

REFERRING VET

Dr. Katie Margulies

INVOICE

16334

DATE

05/18/26

Examination of the **gastrointestinal tract** revealed a stomach and intestine free of stasis, of normal wall thickness, acceptable curvilinear mural detail, and peristaltic activity. Small and large intestine demonstrated normal luminal chyme and stool consistency respectively. No obstructive or overt infiltrative disease was noted. No associated abnormal lymphatic activity was noted.

Pancreas

The base and limbs of the **pancreas** were observed to be largely isoechoic to surrounding omental fat. Pancreatic duct and capsular contour were acceptably normal and parenchyma respected normal curvilinear patterns. No overt evidence of active inflammatory or neoplastic disease was noted.

ULTRASONOGRAPHIC FINDINGS

- Structurally unremarkable abdomen.
- Normal left adrenal gland, nonvisualized right adrenal gland.

INTERPRETATION OF THE FINDINGS & FURTHER RECOMMENDATIONS

No evidence of significant disease. If adrenal disease is still suspected, then further imaging of the right adrenal under sedation may be necessary, owing to sound beam attenuation.



PATIENT

Maya Mopsick

SPECIES

Canine

BREED

Blue Heeler/Australian
Shpherd Mix

SEX

Spayed Female

AGE

7 Years 3 Months

WEIGHT

59.8

INTERPRETED BY

Eric Lindquist, DMV,
DABVP(CFM), Cert.
IVUSS

IMAGING PERFORMED BY

Dr. Katie Margulies

HOSPITAL NAME

Fairland Animal
Hospital

REFERRING VET

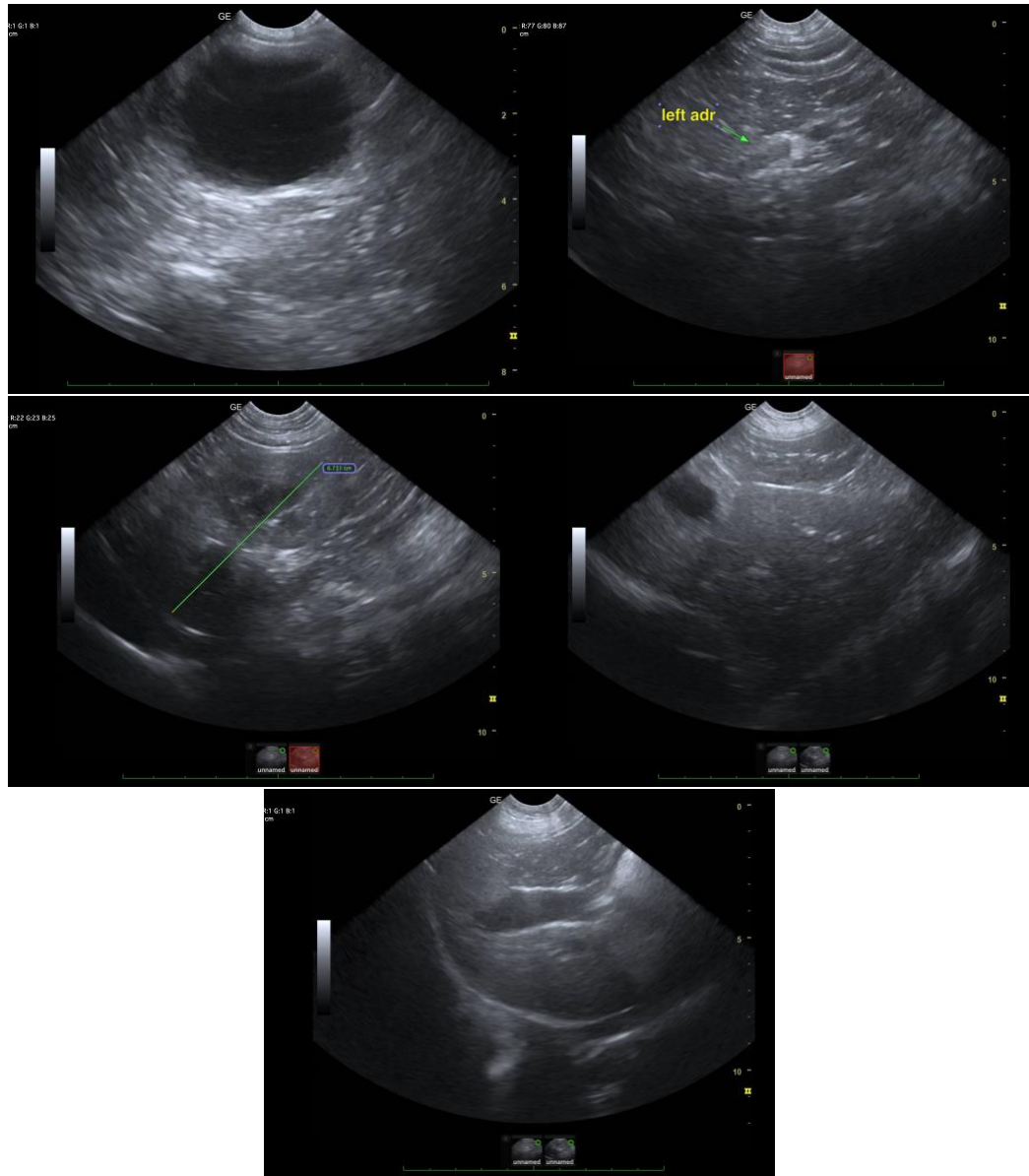
Dr. Katie Margulies

INVOICE

16334

DATE

05/18/26



The information and recommendations provided are based on the images presented by the referring veterinarian/sonographer. No evaluation can be communicated regarding pathology that was not visible in the image/video clips provided.

Thank you for this referral. If the clinical or image interpretation does not parallel your findings or if I can be of any further assistance, please contact me.

Eric Lindquist, DMV, DABVP(CFM), Cert. IVUSS,

CEO, Owner, Founder -- SonoPath.com

info@SonoPath.com



PATIENT

Maya Mopsick

SPECIES

Canine

BREED

Blue Heeler/Australian
Shpeherd Mix

SEX

Spayed Female

AGE

7 Years 3 Months

WEIGHT

59.8

INTERPRETED BY

Eric Lindquist, DMV,
DABVP(CFM), Cert.
IVUSS

IMAGING PERFORMED BY

Dr. Katie Margulies

HOSPITAL NAME

Fairland Animal
Hospital

REFERRING VET

Dr. Katie Margulies

INVOICE

16334

DATE

05/18/26